

Image in cardiology

Vibration and Staccato Flow Pattern in Ventricular Assist Devices

Vibración y flujo entrecortado en asistencia ventricular mecánica

M. Dolores García-Cosío Carmena,* Santiago Serrano-Fiz, and Manuel Gómez Bueno

Unidad de Trasplante Cardíaco, Hospital Universitario Puerta de Hierro, Majadahonda, Madrid, Spain

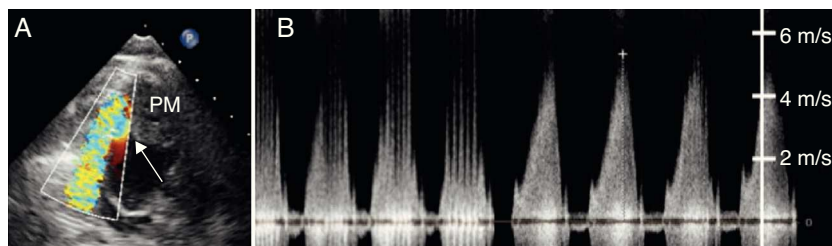


Figure 1.

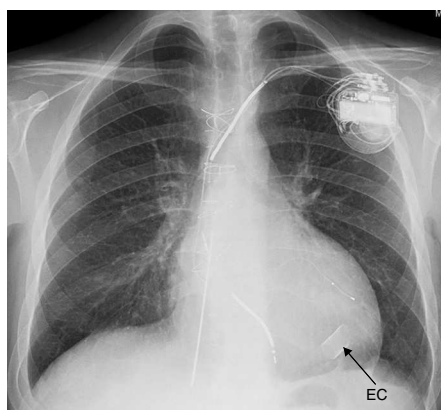


Figure 2.

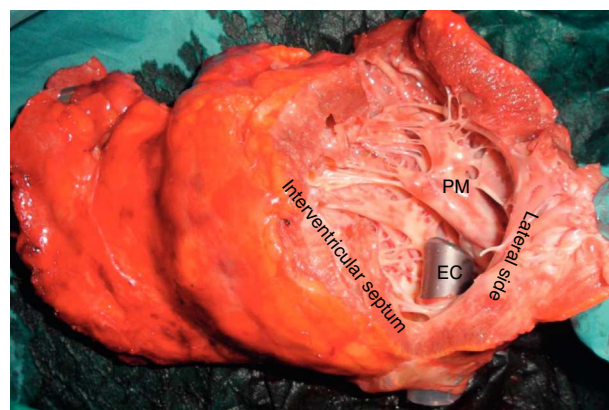


Figure 3.

A patient awaiting a heart transplant may need a ventricular assist device (VAD) to stabilize the clinical situation as needed, and may even be discharged. These VADs have complicated mechanics and dysfunctions can occur, sometimes related to an obstruction in the entrance cannula (EC). We present the case of a 28-year-old man with dilated-phase hypertrophic cardiomyopathy who received a Berlin Heart Excor[®] VAD. On the tenth day after the operation, following an intense negative balance, the EC started to vibrate and there were signs that the artificial ventricle was not filling up correctly. The echocardiogram showed that the left ventricular cavity was smaller than in other studies. The color Doppler study showed a PISA effect (Fig. 1A) in the EC of the left ventricular apex (Fig. 2). The Doppler continued showing high-flow velocity in the EC with intermittent unsteady flow, coinciding with the vibration (Fig. 1B), which were indicative of an obstruction. The vibration reduced once the patient was properly hydrated, and no clinical repercussions occurred.

After 111 days on VAD support, 90 of those days at home, the patient received the heart transplant. The extracted heart showed that the EC opening was very close to a prominent papillary muscle (Fig. 3). The implant was close to the deformed papillary muscle and the ventricular diameter reduced over time, which could have contributed to the obstruction. This last point explains that the alteration was manifested days after the VAD was implanted, and improved when the patient was properly hydrated.

* Corresponding author:
E-mail address: mdgcosio@secardiologia.es (M.D. García-Cosío Carmena).
Available online 23 September 2011