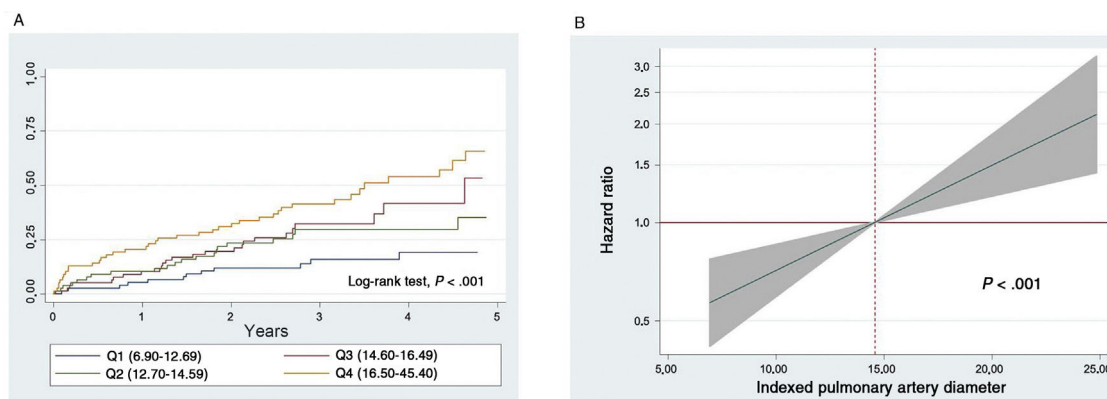

**Figure 1.** A, Kaplan-Meier curves showing all-cause mortality by quartile of indexed pulmonary artery diameter. B, estimated adjusted risk of death according to indexed pulmonary artery diameter.

Julio Núñez,<sup>a</sup> Héctor Merenciano-González,<sup>a</sup> Enrique Santas,<sup>a</sup> María Pilar López-Lereu,<sup>b</sup> José Vicente Monmeneu,<sup>b</sup> and Ernesto Valero<sup>a,\*</sup>

<sup>a</sup>Servicio de Cardiología, Hospital Clínico Universitario, Valencia, Spain

<sup>b</sup>Unidad de Resonancia Magnética Cardíaca, ERESA Grupo Médico, Valencia, Spain

\*Corresponding author:

E-mail address: [ernestovaleropicher@gmail.com](mailto:ernestovaleropicher@gmail.com) (E. Valero).

Available online 23 September 2020

## REFERENCES

- Merlos P, Núñez J, Sanchis J, et al. Echocardiographic estimation of pulmonary arterial systolic pressure in acute heart failure. Prognostic implications. *Eur J Intern Med.* 2013;24:562–567.
- Santas E, de la Espriella-Juan R, Mollar A, et al. Echocardiographic pulmonary artery pressure estimation and heart failure rehospitalization burden in patients with acute heart failure. *Int J Cardiol.* 2017;241:407–410.
- Galiè N, Humbert M, Vachiery JL, et al. ESC/ERS Guidelines for the diagnosis and treatment of pulmonary hypertension. *Eur Heart J.* 2016;37:67–119.

<https://doi.org/10.1016/j.rec.2020.06.039>

1885-5857/

© 2020 Sociedad Española de Cardiología. Published by Elsevier España, S.L.U. All rights reserved.

## Valve-in-valve transcatheter aortic valve implantation for bioprosthetic aortic sutureless valve failure: a case series



### Implante percutáneo de válvula en válvula por fallo de bioprótesis aórtica sin sutura: serie de casos

#### To the Editor,

In the era of transcatheter aortic valve implantation, sutureless Perceval valves (Livanova, London, United Kingdom) have emerged as a new implantation technique to minimize surgical risk in older patients with multiple comorbidities. This bioprosthesis facilitates a minimally invasive approach, allowing shorter duration of cross-clamping,<sup>1</sup> and prevents patient-prosthesis mismatch because of the absence of a sewing ring, which allows a larger effective orifice area (EOA).<sup>2,3</sup> As a result, sutureless valves have recently been proposed as an ideal solution for elderly patients with a small annulus.

Like other bioprostheses, sutureless valves degenerate; however, stent infolding with distortion (or “stent creep”) has been described as a single mechanism of valve failure. It consists of an inward deflection of the stent posts that leads to a reduced EOA, causing high gradients or paravalvular leaks.

Valve-in-valve (ViV) therapy using transcatheter heart valves (THVs) has been shown to be safe and effective in most patients

with degenerated prosthetic valves. Nevertheless, little is known about ViV within sutureless valves and only a few cases have been reported.<sup>1,3</sup> We present 5 illustrative cases of sutureless Perceval valve failure occurring at a median time of 3 years after the surgical aortic valve replacement and which were treated between December 2018 and December 2019.

Baseline and procedural characteristics are outlined in [table 1](#). Most of the patients were female and at high risk of aortic valve redo surgery (logistic EuroSCORE = 38.7%, EuroSCORE II = 24.3, and Society of Thoracic Surgeons score = 13.4). The most frequent mechanism of sutureless bioprosthetic failure in our series was stenosis (n = 2), regurgitation (n = 1), and mixed (n = 2). The mechanisms were stent infolding in 2 patients ([figure 1](#)), severe aortic regurgitation without evidence of endocarditis on positron emission-computed tomography in 1 patient, and elevated gradients due to calcification and valve degeneration in the other patients. Three of the treated valves were Perceval S (19–21 mm), 1 was Perceval M (21–23 mm), and 1 was Perceval XL (23–25 mm).

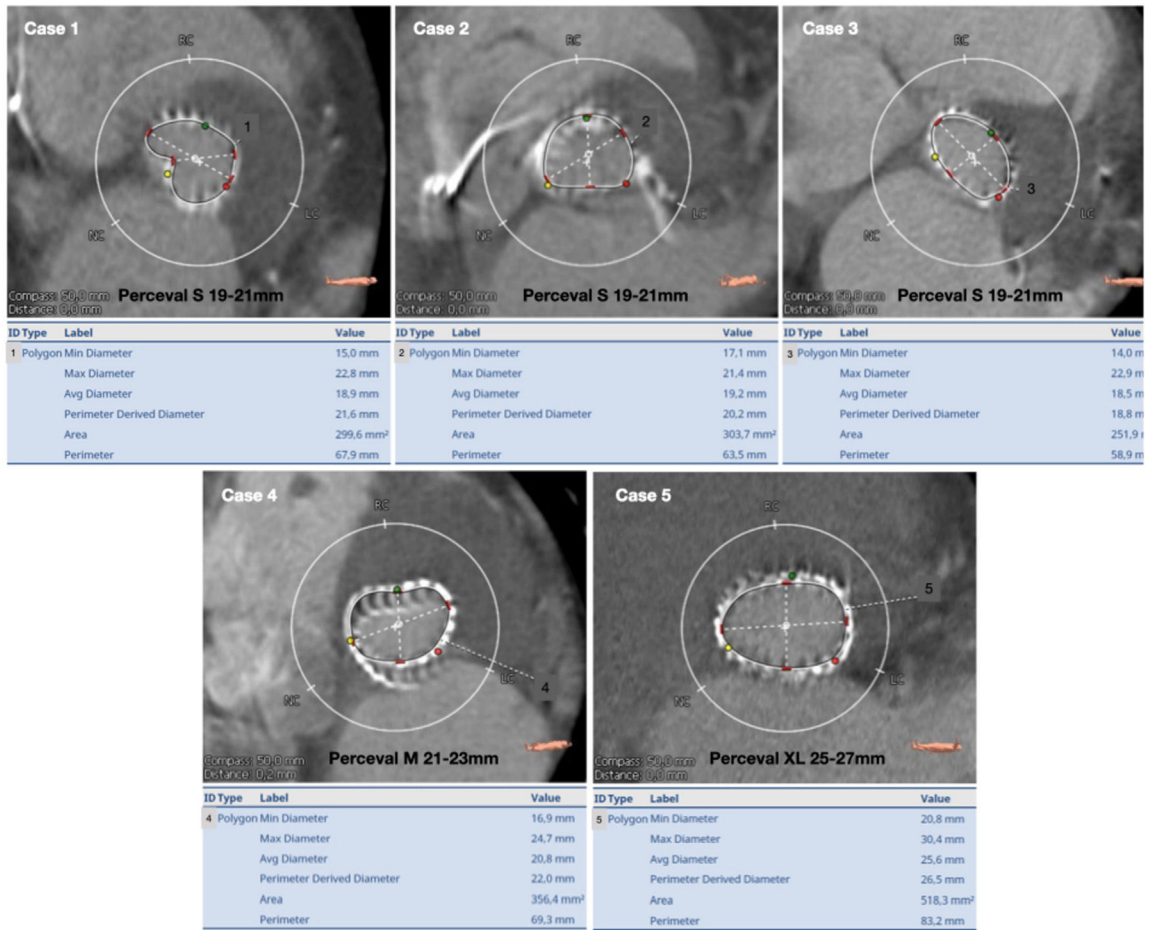
Sutureless valves with stent invagination were predilated and postdilated using an Atlas Gold (CR Bard, Murray Hill, New Jersey) balloon catheter in order to make the implantation more predictable. Self-expandable valves (CoreValve Evolut PRO in 1 patient and Symetis ACURATE neo in 1 patient) were used due to their repositionable features and supra-annular design. An Edwards SAPIEN 3 was implanted in the other 3 patients without sutureless valve stent underexpansion with no need for pre- or

**Table 1**  
Baseline and procedural characteristics and results

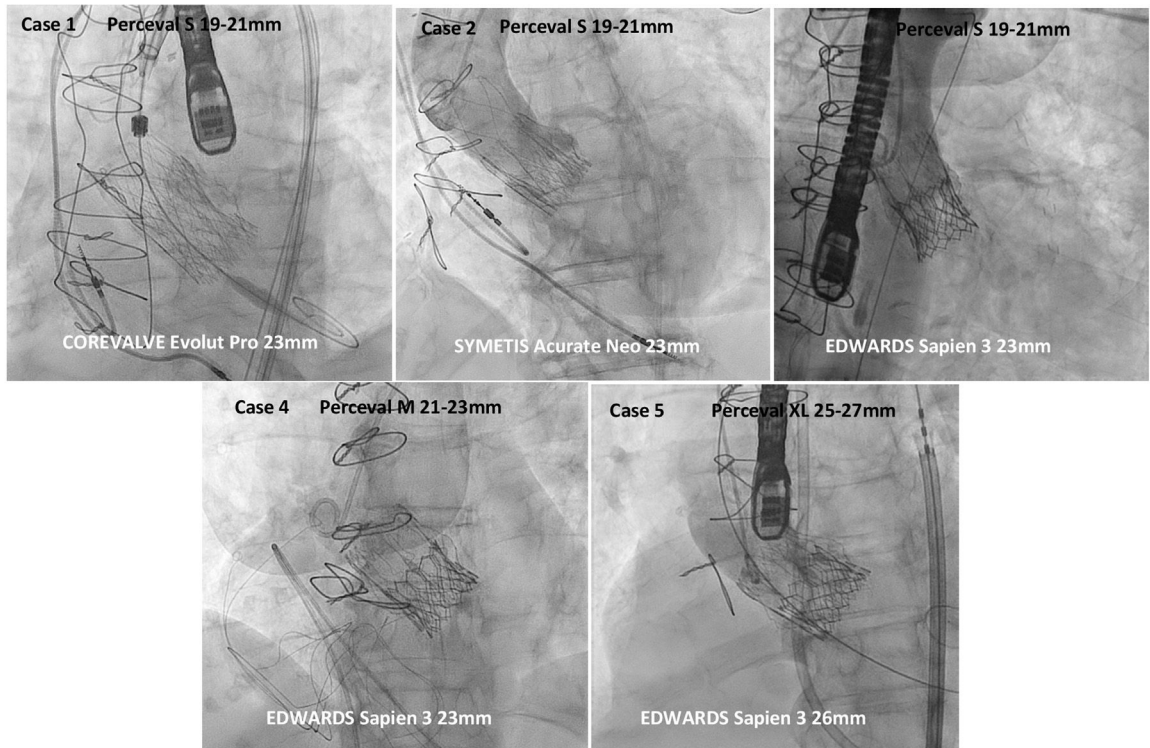
<i>Baseline characteristics</i>						n = 5
Age, y						83 ± 3.43
Female sex						4 (80)
Hypertension						5 (100)
Diabetes						2 (40)
Dyslipidemia						5 (100)
BMI, kg/m <sup>2</sup>						29.18
Logistic EuroSCORE, %						38.67
Euroscore II						24.27
STS score						13.38
NYHA class IV						4 (80)
Coronary artery disease						2 (40)
Previous pacemaker						0 (0)
Previous conduction disturbances						0 (0)
	Case 1	Case 2	Case 3	Case 4	Case 5	
Sutureless valve and size	Perceval S 19-21 mm	Perceval S 19-21 mm	Perceval S 19-21 mm	Perceval M 21-23 mm	Perceval XL 25-27 mm	
Failure time from SAVR, y	0.96	3.12	3.42	4.96	2.68	
Mechanism of dysfunction	Stent creep	Stent creep	Cusp calcification/ degeneration	Cusp calcification/ degeneration	Aortic regurgitation	
<i>Preprocedure measurements</i>						
Aortic gradients, mmHg	98/69	75/56	78/49	77/48	21/11	
Aortic regurgitation grade (localization)	Mild (central)	Moderate (intraprosthetic)	Moderate (intraprosthetic)	Moderate (intraprosthetic)	Severe (intraprosthetic)	
Annulus diameter (CT), mm	20.7	19.3	18.5	20.8	25.4	
Annulus area (CT), mm <sup>3</sup>	317.9	303.7	251.9	356.4	512.4	
Annulus perimeter (CT), mm	64.3	63.5	58.9	69.3	82.7	
Ostium heights (LCA/RCA), mm	11.2/12.8	18.2/16.3	11.7/17.9	18.9/21.1	12/20	
VTC, mm	5.3	4.6	4.5	5.5	4.5	
LVEF, %	71	65	73	68	47	
<i>Procedure characteristics</i>						
TAVI valve and size	CoreValve Evolut PRO 23 mm	Symetis ACURATE neo 23 mm	Edwards SAPIEN 3 23 mm	Edwards SAPIEN 3 23 mm	Edwards SAPIEN 3 26 mm	
ViV approach	Femoral	Femoral	Femoral	Femoral	Femoral	
Predilation	20 mm, 16 atm	18 mm, 18 atm	No	No	No	
Postdilation	22 mm, 14 atm	18 mm, 17 atm	No	No	No	
Final aortic gradients, mmHg	40/27	33/19	25/16	19/10	18/9	
Postprocedure leak	None	None	None	None	None	
<i>Follow-up of procedural complications</i>						
Conduction disturbances	Intraprocedural AVB	Intraprocedural AVB	NO-LBBB	NO-LBBB	None	
Pacemaker	Yes	Yes	No	No	No	
Other complications	None	None	None	None	None	
<i>Follow-up</i>						
Aortic gradients at 6 month-FU, mmHg	26/15	30/17	20/10	15/7	16/7	

AVB, atrioventricular block; BMI, body-mass index; CT, computed tomography; FU, follow-up; LCA, left coronary artery; LVEF, left ventricular ejection fraction; NO-LBBB, new-onset left bundle branch block; NYHA, class of the New York Heart Association; RCA, right coronary artery; SAVR, surgical aortic valve replacement; STS score, Society of Thoracic Surgeons; TAVI, transcatheter aortic valve implantation; ViV, valve-in-valve; VTC, virtual transcatheter heart valves to coronary distance. The data are presented as absolute numbers, No. (%), mean ± standard deviation, or max/mean.

A



B



**Figure 1.** A: computed tomography measurements (diameters, perimeter derived diameter, area and perimeter specified below each case) of annulus dimensions of failing sutureless aortic valves. B: final angiographic result of valve-in-valve procedures with different types of transcatheter heart valves in failing sutureless aortic valves.

postdilatation. All procedures were safely performed with good results (mean gradients < 20 mmHg with no residual leaks).

Although THV durability appears favorable in the setting of native aortic valve stenosis, there are concerns about its durability in underexpanded ViV implants and the occurrence of specific procedural complications. Certain surgical valves have been identified as having a higher risk of coronary obstruction (the main mechanism being occlusion of the ostia by a dislodged leaflet after deployment of the THV). Thus, detailed preprocedural computed tomography study is crucial to identify high-risk features (such as low coronary heights, shallow sinuses of Valsalva, and short virtual THV to coronary distance).<sup>4</sup> Although very few reports are available, we extend this experience with 5 patients, none of whom developed coronary obstruction. Although the risk of coronary occlusion seemed low (high coronary heights, wide sinuses, and virtual THV to coronary distance > 4 mm), this type of valve may have a lower risk of coronary occlusion than other prostheses due to its implantation technique and valve design (the metallic stent has sinusoidal struts that fit Valsalva sinuses). Regarding conduction disturbances, a recent propensity-matched analysis reported lower rates of pacemaker implantation with ViV vs redo surgery for the management of failed prostheses.<sup>5</sup> Data on sutureless valves are lacking, but among our patients, 2 patients with Percevals with stent deformation treated with self-expandable valves presented with atrioventricular block requiring pacemaker implantation, 2 patients with Percevals S and M treated with Edwards SAPIEN 3 presented with new onset left bundle branch block that was treated conservatively, and 1 patient with Perceval XL did not have any conduction abnormalities.

One of the advantages of sutureless valves is the absence of a sewing ring, which provides larger EOAs and reduces the risk of the development of patient-prosthesis mismatch compared with other bioprostheses. As described in table 1, acceptable gradients were achieved in our patients after the procedure and at mid-term follow-up. Paravalvular leaks were not a major concern in any of the patients in our series.

To conclude: a) ViV transcatheter aortic valve implantation in sutureless valves was feasible and safe; b) challenging cases such as small degenerated valves were successfully treated with self-expandable valves and acceptable gradients, and c) the rate of procedural complications was low and good in-hospital and mid-term outcomes were achieved with different types of transcatheter aortic valves.

Currently, procedural or mid-term results for ViV procedures in sutureless aortic valves are lacking. However, because sutureless valves are becoming more widely used and ViV is increasing, thorough knowledge will be essential and the features described above provide insights into the safety and feasibility of these procedures.

Victoria Vilalta,<sup>a,b,c,\*</sup> Xavier Carrillo,<sup>a,c</sup>  
Eduard Fernández-Nofrerías,<sup>a,c</sup> Marta González-Lopera,<sup>a</sup>  
Josepa Mauri,<sup>a,c</sup> and Antoni Bayés-Genís<sup>a,b,c</sup>

<sup>a</sup>*Servicio de Cardiología, Hospital Universitari Germans Trias i Pujol, Badalona, Barcelona, Spain*

<sup>b</sup>*Departamento de Medicina, Universidad Autónoma de Barcelona (UAB), Barcelona, Spain*

<sup>c</sup>*Centro de Investigación Biomédica en Red de Enfermedades Cardiovasculares (CIBERCV), Barcelona, Spain*

\*Corresponding author:

E-mail address: [victoria.vilalta@gmail.com](mailto:victoria.vilalta@gmail.com) (V. Vilalta).

Available online 14 August 2020

## REFERENCES

1. Attia R, Papalexopoulou N, Hancock J, et al. Successful treatment of failing biological prosthesis due to 'stent creep' with Valve-in-Valve Transcatheter Aortic Valve Implantation. *Catheter Cardiovasc Interv.* 2015;86:119–125.
2. Meco M, Montisci A, Miceli A, et al. Sutureless Perceval Aortic Valve Versus Conventional Stented Bioprostheses: Meta-Analysis of Postoperative and Midterm Results in Isolated Aortic Valve Replacement. *J Am Heart Assoc.* 2018;7:e006091.
3. Balghith MA. Degenerated Sutureless Perceval with (Paravalvular Leak and AS) Treated by Valve in Valve using S3 Edward Valve. *Heart Views.* 2019;20:166–169.
4. Bernardi FLM, Dvir D, Rodes-Cabau J, Ribeiro HB. Valve-in-Valve Challenges: How to Avoid Coronary Obstruction. *Front Cardiovasc Med.* 2019;6:120.
5. Tam DY, Dharma C, Rocha RV, et al. Transcatheter ViV Versus Redo Surgical AVR for the Management of Failed Biological Prosthesis. *JACC Cardiovasc Interv.* 2020;13:765–774.

<https://doi.org/10.1016/j.rec.2020.06.020>  
1885-5857/

© 2020 Sociedad Española de Cardiología. Published by Elsevier España, S.L.U. All rights reserved.

## Changes in the microbiological etiology of infective endocarditis in our region in the last 3 decades (1987-2019)



### Cambios en el espectro microbiológico causal de la endocarditis infecciosa en nuestro medio en las últimas 3 décadas (1987-2019)

#### To the Editor,

Infective endocarditis (IE), first described by William Osler in 1885, is a serious disease.<sup>1</sup> Classic forms of IE are mainly caused by *Streptococcus viridans* or *Staphylococcus aureus*.<sup>2</sup> Numerous sociocultural and health-related changes (eg, population aging, complex cardiac surgery, a greater use of implanted pacemakers and defibrillators, and a higher prevalence of health care-

associated bacteremia)<sup>3</sup> have changed the face of IE in recent decades.<sup>4</sup> As suggested in recent studies, one of the possible consequences of these changes is a shift in the microbiological profile of IE.<sup>4,5</sup> The aim of this study was to analyze the causative microorganisms identified in native and prosthetic forms of IE at our hospital over a period of 33 years and to examine the changes that have taken place. We analyzed a cohort of patients with IE whose data were prospectively recorded between 1987 and 2019. The cohort included all patients diagnosed with IE during this period except persons who inject drugs. The study period was divided into 3 periods: 1987 to 1997, 1998 to 2008, and 2009 to 2019.

Our hospital is a tertiary care center with a cardiac surgery department that serves as an IE referral center for 3 regional hospitals in the province. Native IE accounted for 66.1%