

Brief report

Value of Molecular Diagnosis in a Family With Marfan Syndrome and an Atypical Vascular Phenotype

Ana Lebreiro,^{a,*} Elisabete Martins,^a Jorge Almeida,^b Sofia Pimenta,^c José Miguel Bernardes,^c José Carlos Machado,^d and Cassiano Abreu-Lima^{a,e}^a Cardiology Department, Hospital S. João, Porto, Portugal^b Thoracic Surgery Department, Hospital S. João, Porto, Portugal^c Rheumatology Department, Hospital S. João, Porto, Portugal^d Institute of Molecular Pathology and Immunology, University of Porto, Porto, Portugal^e Medicine Department, Medical School, University of Porto, Porto, Portugal

ARTICLE INFO

Article history:

Received 2 January 2010

Accepted 21 February 2010

Available online 30 December 2010

Keywords:

Marfan syndrome

FBN1 gene

Molecular testing

Aortic dissection

Palabras clave:

Síndrome de Marfan

Gen FBN1

Estudio molecular

Diseción aórtica

ABSTRACT

Marfan syndrome is mainly caused by mutations in the *FBN1* gene. Diagnosis is usually based on clinical criteria, but the phenotypic presentation varies widely among affected individuals. Aortic dissection or rupture is the cause of death in over 90% of untreated patients. Early identification of individuals at risk is important given the availability of medical and surgical treatment that can significantly improve life-expectancy. Molecular testing could provide an etiologic diagnosis in patients who present with milder or atypical clinical forms of the disease. Moreover, it could contribute to preventive treatment in carriers, inform genetic counseling, and offer reassurance to unaffected individuals. By describing a family with Marfan syndrome in whom the disease presented in an atypical aggressive form, this article highlights the value of testing for *FBN1* mutations in selected cases.

© 2010 Sociedad Española de Cardiología. Published by Elsevier España, S.L. All rights reserved.

Utilidad del diagnóstico molecular en una familia con síndrome de Marfan y un fenotipo vascular atípico

RESUMEN

El síndrome de Marfan (SMF) se produce principalmente por mutaciones del gen *FBN1*. El diagnóstico suele basarse en criterios clínicos, pero la forma de presentación fenotípica es muy diversa en los individuos afectados. La disección o la rotura aórtica son la causa de la muerte en más del 90% de los pacientes no tratados. La identificación precoz de los individuos en riesgo es importante, teniendo en cuenta la disponibilidad de tratamientos médicos y quirúrgicos que mejoran significativamente la esperanza de vida. Los estudios moleculares pueden proporcionar un diagnóstico etiológico en los pacientes con formas de presentación clínica atípicas o más leves y contribuyen al manejo preventivo de portadores y el consejo genético y la tranquilización de los individuos no afectados. En este artículo, mediante la descripción de una familia con SMF con una forma de presentación vascular atípica y agresiva, ponemos de relieve la utilidad de las pruebas de detección de la mutación de *FBN1* en casos seleccionados.

© 2010 Sociedad Española de Cardiología. Publicado por Elsevier España, S.L. Todos los derechos reservados.

INTRODUCTION

Aortic dissection or rupture is the main cause of death in over 90% of untreated patients with Marfan syndrome (MFS),¹ but in about 18% the first aortic event (i.e. dilatation or dissection) occurs in the distal aorta.²

In general, MFS is caused by mutations in the fibrillin-1 (*FBN1*) gene, a large gene located on chromosome 15. More than 600 pathogenic mutations were reported in the last update of the

Universal Marfan Database, and most of these are unique to individual families.³

To date, there is no established genotype-phenotype correlation. Nevertheless, the relative risk of specific organ involvement differs significantly between different types of mutations.⁴

Early recognition of at-risk MFS patients is important in view of available medical and surgical treatments that can significantly improve life-expectancy.

In this paper, we describe a family that includes several members with clinical features compatible with MFS but who have peculiar phenotypic characteristics. In this family, molecular diagnosis provided a definitive diagnosis and could be used for family screening.

* Corresponding author: Hospital de S. João, Alameda Prof. Hernâni Monteiro 4202-451 Porto, Portugal.

E-mail address: ana.lebreiro@gmail.com (A. Lebreiro).

METHODS

Clinical Data

Patients and their relatives were invited to a medical consultation with a cardiologist, a rheumatologist and an ophthalmologist; MFS was diagnosed according to Ghent's criteria.⁵

Echocardiographic evaluations were performed using either a Vivid 3 (GE Healthcare) or iE33 (Philips) ultrasound scanner. The diameter of the aorta was measured on the basis of recommendations for chamber quantification from the American Society of Echocardiography and the European Association of Echocardiography.⁶ The aortic root was considered dilated when the maximum diameter at the sinuses of Valsalva exceeded the upper normal limit for the patient's age and body surface area.⁷

Magnetic resonance angiography (MRA) using a 3-T whole-body magnet (Siemens Magnetom Trio) was performed in some patients. Transverse, longitudinal, coronal and oblique sagittal scans encompassing the ascending aorta, aortic arch, and descending aorta were acquired. Multiplanar reconstructions were also analyzed.

The only ocular criterion considered was ectopia lentis. Magnetic resonance was not used to look for dural ectasia.

Molecular Data

After appropriate written informed consent was obtained, DNA was extracted from peripheral blood samples and all 65 exons of *FBN1* were amplified. Mutation screening of the entire coding sequence of the *FBN1* gene was then performed using the polymerase chain reaction. All positive results were confirmed by repeated analysis.

RESULTS

Family Description

Our proband (Fig. 1, III:7, arrowed), a 37-year-old female, was referred to our center after experiencing a type-B aortic dissection that started 60 mm after the origin of left subclavian artery and extended distally to the iliac arteries. The dimensions of the ascending aorta and aortic arch were within normal limits, while the descending thoracic aorta had a diameter of 42 mm.

Family history at that time revealed that the patient's father (Fig. 1, II:3) had died suddenly at the age of 48 years (after a type-B aortic dissection) and two uncles (Fig. 1, II:19 and II:21) were already being monitored for aortic disease. The older of these, a 53-year-old male (Fig. 1, II:19), had a Bentall composite graft implanted at the age of 50 years because of progressive aortic root dilatation (60 mm). The second uncle, who was 48 years old

(Fig. 1, II:21), presented with generalized arterial disease. His left leg had been amputated because of occlusive arterial disease at the age of 45 years, and a popliteal aneurysm on the right leg had been excluded when he was aged 46 years. He also had mild dilatation of the abdominal aorta and an aortic root aneurysm, of diameters 34 mm and 46 mm, respectively.

By that time, family screening had been started and our patient's brothers were called in for clinical evaluation. Three of them (two females and one male) were evaluated: a 43-year-old sister (Fig. 1, III:4) had a normal-sized aorta but peculiar post-isthmic ectasia was found on MRA (Fig. 2A); a 39-year-old sister (Fig. 1, III:6) had mild aortic root dilatation (40 mm), a normal-sized descending aorta and the same peculiar post-isthmic ectasia (Fig. 2B); and the youngest brother, a 36-year-old patient (Fig. 1, III:8), presented with aortic root dilatation (47 mm) and discrete aortic ectasia (31 mm) of the descending aorta just after the isthmus (Fig. 2C). Four days after clinical and imaging evaluations, this patient was admitted for acute type-B aortic dissection, which started immediately after the origin of the subclavian artery. A CT scan revealed aortic dilatation (44 mm) at the level of the aortic dissection.

A first-degree cousin of the patient, a 19-year-old (Fig. 1, III:33), had acute type-A dissection at the age of 19 years, which extended throughout the entire aorta. The ascending aorta was markedly dilated (82 mm) and he underwent emergent surgical aortic root and valve replacement.

Another of the proband's aunts, a 61-year-old (Fig. 1, II:14), was found to have aortic root dilatation (43 mm).

The clinical features of affected family members are depicted in Table 1. The other family members evaluated (i.e. 12 subjects) showed no clinical or molecular evidence of MFS.

Molecular Study

A new pathogenic *FBN1* mutation was identified in all affected members of this family. The mutation was a nonsense mutation, with a C1995G substitution in exon 16 of *FBN1*, which led to the formation of a stop codon in position 665 of tyrosine (i.e. Tyr665X).

DISCUSSION

This family came to our attention because of two cases of type-B aortic dissection (Fig. 1, III:7 and III:8). The aortic diameters were smaller than expected in these complications and the descending aorta had a peculiar anatomy, which had not previously been described as being associated with MFS (Fig. 2). Moreover, another family member presented with an initial diagnosis of peripheral arterial disease (i.e. a popliteal aneurysm) and was subsequently diagnosed with abdominal and ascending aortic dilatation. The presence of a generalized arterial familial syndrome was suspected and we searched for mutations in *FBN1* and transforming growth

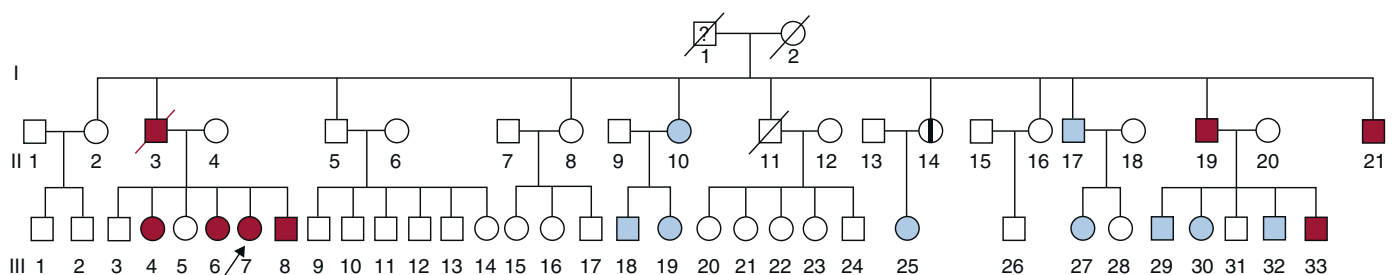


Figure 1. Family pedigree. Arrow, proband. Red-colored symbols, affected subjects fulfilling Ghent criteria. Symbols with a vertical black bar, affected subjects not fulfilling Ghent criteria. Blue symbols, negative clinical and molecular study findings. ?, possibly affected subject. Symbols with an oblique bar, deceased subjects.

Table 1
Clinical Features of Affected Family Members

Patient	Sex	Age (years)	Cardiovascular system			Skeletal system						Ocular system (ectopia lentis)	Lung (spontaneous pneumothorax)	Skin			
			ADil	ADis	MVP	PCar	PExc	ASp/H	Scol	W&T	PPlan				PAcet	JointH	FacF
II:14	F	61	+	–	–	–	–	1.03	–	–	–	na	–	–	na	–	–
II:19	M	53	+/Surg	–	+/Surg	na	na	1.08	+	+	+	+	–	–	–	–	–
II:21	M	48	+	–	–	na	na	1.03	–	+	–	+	–	+	–	+	+
III:4	F	43	–	–	+	–	+	1.04	+	+	+	+	–	+	–	–	+
III:6	F	39	+	–	–	–	+	1.02	+/Surg	+	+	+	+	–	–	+	+
III:7	F	37	–	+	+	–	+	1.04	+	+	+	+	+	+	–	–	+
III:8	M	36	+	+	+	+	–	1.06	+	+	+	+	+	–	–	–	+
III:33	M	19	+	+/Surg	–	–	–	1.08	–	+	–	+	+	+	–	–	+

Abbreviations: ADil, aortic dilatation; ADis, aortic dissection; Asp/H, arm-span-to-height ratio; F, female; FacF, facial features; JointH, joint hypermobility; M, male; MVP, mitral valve prolapse; na, not available; PAcet, protusio acetabulae; PCar, pectus carinatum; PExc, pectus excavatum; PPlan, pes planus; Scol, scoliosis; Surg, surgery; W&T, wrist and thumb signs; –, not present; +, present.

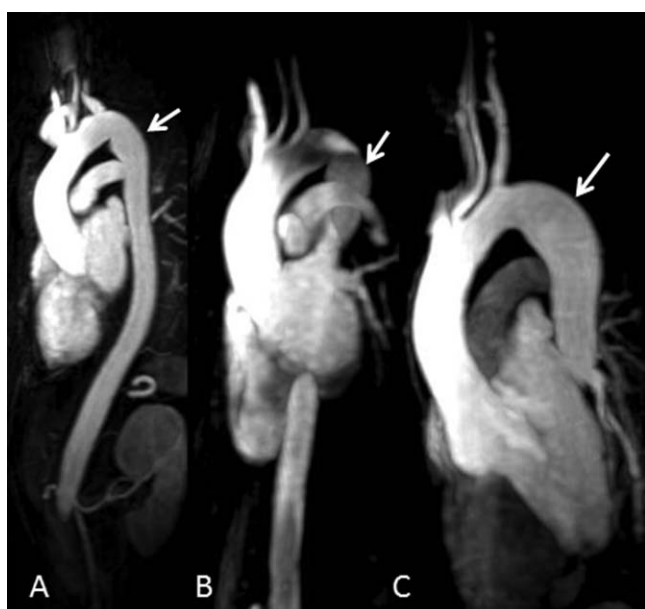

Figure 2. Three-dimensional reconstruction of magnetic resonance angiography images of patients III:4 (A), III:6 (B) and III:8 (C) in Figure 1, showing peculiar mild narrowing at the level of the isthmus and post-isthmus aortic ectasia (arrows).

factor-beta receptor (*TGFβR*) genes. The molecular identification of a *FBN1* mutation was a determinant of a definitive diagnosis of MFS in this family.

In general, *FBN1* gene mutations are found in about 90% of MFS patients who fulfill Ghent's criteria,⁸ but patients with classic MFS phenotypes have also been found to be carriers of *TGFβR1* and *TGFβR2* mutations (MFS type 2), the same mutations that cause Loeys–Dietz syndrome (LDS). These patients typically present at an early age with generalized arterial tortuosity and aneurysms and aortic dissection and have smaller aortic diameters.⁹ A broad clinical overlap has been found among MFS, MFS type 2 and LDS.¹⁰

In this family, we found a new *FBN1* mutation that leads to an early protein sequence truncation and which is associated with a particularly aggressive cardiovascular phenotype in most affected individuals. The nonsense mutation found was located in the exon encoding the second of seven TGFβ1-binding protein-like modules of fibrillin-1, a domain present only in *FBN1* and latent TGF-beta

binding proteins (LTBPs). These globular domains have no known specific function, although they may mediate specific protein–protein interactions.¹¹

Currently, increased TGFβ activity is thought to be a major contributor to the pathogenesis of both MFS and LDS.^{9,12}

In the future, better understanding of the genetic background and molecular pathways involved may change our approach to aortic disease in MFS. Meanwhile, currently accepted criteria for surgical aortic intervention in MFS patients are an ascending aorta diameter of 5.0 cm or more and a descending aorta diameter of at least 6.0 cm.¹³ These values are far from the aortic dimensions presented by our proband and her brother, yet this did not prevent them developing type-B aortic dissection. The questions of whether and when to intervene in the other two sisters who have similar aortic morphologies are difficult, and these individuals are now under close clinical and imaging surveillance to detect any increase in aortic dimensions. In conclusion, in this family, detection of a *FBN1* mutation revealed the genetic nature of the phenotypic features described, enabled patients with milder clinical presentations to be diagnosed, and played a role in early diagnosis, genetic counseling, preventive management of carriers and reassurance of unaffected individuals. The differential diagnosis of classic MFS, MFS type 2 and an LDS subtype would not have been possible on clinical grounds alone.

FUNDING

This study was supported by a grant from the Research Department of Hospital S. João, Porto, Portugal.

CONFLICTS OF INTEREST

None declared.

REFERENCES

1. Nienaber CA, Von Kodolitsch Y. Therapeutic management of patients with Marfan syndrome: focus on cardiovascular involvement. *Cardiol Rev*. 1999;7:332–41.
2. Engelfriet PM, Boersma E, Tijssen JG, Bouma BJ, Mulder BJ. Beyond the root: dilatation of the distal aorta in Marfan's syndrome. *Heart*. 2006;92:1238–43.
3. Beroud C, Collod-Beroud G, Boileau C, Soussi T, Junien C. UMD (Universal mutation database): a generic software to build and analyze locus-specific databases. *Hum Mutat*. 2000;15:86–94.

4. Schrijver I, Liu W, Odom R, Brenn T, Oefner P, Furthmayr H, et al. Premature termination mutations in *FBN1*: distinct effects on differential allelic expression and on protein and clinical phenotypes. *Am J Hum Genet.* 2002;71:223-37.
5. De Paepe A, Devereux RB, Dietz HC, Hennekam RC, Pyeritz RE. Revised diagnostic criteria for the Marfan syndrome. *Am J Med Genet.* 1996;62:417-26.
6. Lang RM, Bierig M, Devereux RB, Flachskampf FA, Foster E, Pellikka PA, et al. Recommendations for chamber quantification: a report from the American Society of Echocardiography's Guidelines and Standards Committee and the Chamber Quantification Writing Group, developed in conjunction with the European Association of Echocardiography, a branch of the European Society of Cardiology. *J Am Soc Echocardiogr.* 2005;18:1440-63.
7. Roman MJ, Devereux RB, Kramer-Fox R, O'Loughlin J. Two-dimensional echocardiographic aortic root dimensions in normal children and adults. *Am J Cardiol.* 1989;64:507-12.
8. Loeys B, De Backer J, Van Acker P, Wettinck K, Pals G, Nuytinck L, et al. Comprehensive molecular screening of the *FBN1* gene favors locus homogeneity of classical Marfan syndrome. *Hum Mutat.* 2004;24:140-6.
9. Loeys BL, Schwarze U, Holm T, Callewaert BL, Thomas GH, Pannu H, et al. Aneurysm syndromes caused by mutations in the TGF-beta receptor. *N Engl J Med.* 2006;355:788-98.
10. Mizuguchi T, Matsumoto N. Recent progress in genetics of Marfan syndrome and Marfan-associated disorders. *J Hum Genet.* 2007;52:1-12.
11. Colod-Beroud G, Boileau C. Marfan syndrome in the third Millennium. *Eur J Hum Genet.* 2002;10:673-81.
12. Neptune ER, Frischmeyer PA, Arking DE, Myers L, Bunton TE, Gayraud B, et al. Dysregulation of TGF-beta activation contributes to pathogenesis in Marfan syndrome. *Nat Genet.* 2003;33:407-11.
13. Elefteriades JA. Natural history of thoracic aortic aneurysms: indications for surgery, and surgical versus nonsurgical risks. *Ann Thorac Surg.* 2002;74:S1877-80. discussion S92-8.