

## Usefulness of the Contact Force Sensing Catheter to Assess the Areas of Myocardial Scar in Patients With Ventricular Tachycardia



### Utilidad de un catéter de ablación con sensor de fuerza en la evaluación de las áreas de cicatriz miocárdicas de pacientes con taquicardia ventricular

#### To the Editor,

Ablation is one of the pillars of treatment for ventricular tachycardias (VT).<sup>1,2</sup> Pressure is important for determining the size and potential efficacy of the ablation lesions.<sup>3,4</sup> Traditional catheters do not provide direct information on the pressure they exert on tissues; it is estimated indirectly according to the signal voltage and the operator's perceptions. In VT substrate electro-anatomical mapping, the absence of contact between the catheter and the endocardium can generate low-voltage electrocardiograms that cause erroneous delimitation of the actual scarring and eventually the loss of the channels involved in maintaining VT. Direct information on the force applied by the tip of the catheter could improve the delimitation of the electrically abnormal tissue in patients with a substrate for VT.

The principal objectives of this study were to compare the scarred areas obtained by traditional voltage mapping with those obtained using a map that includes the contact force information in patients with VT, and to determine whether this information makes it possible to improve the traditional map, correcting the points acquired in areas with no contact.

Eleven patients (8 males; mean age, 64.9 [38–80] years) with ventricular arrhythmias due to ischemic cardiomyopathy or dilated cardiomyopathy who underwent VT ablation for clinical indications were included (Table). The study was approved by the Ethics Committee of the hospital and recorded in the clinicaltrials.gov register of clinical trials under identification number NCT01639365.

A voltage map of the left ventricle was obtained during sinus rhythm with the Carto<sup>®</sup> 3 navigation system and a Navistar Thermo Cool catheter (Biosense-Webster; Diamond Bar, California, United States). The points with fragmented or late potentials were labeled, and the color coding of the voltage map was adjusted to locate channels (control map). The information on the force at each point captured was acquired by the system, but was not available to the operator during control-map acquisition. Once this was over, the operator was given the contact information and proceeded to acquire new points in order to correct the previously acquired

areas with poor contact (final map). Each point on the control map that had no contact was classified as scarred (< 0.5 mV), low voltage (0.5–1.5 mV), or normal (> 1.5 mV). The size of the scars, the abnormal potentials, and the channels detected in the control map were compared with those of the final map (Figure).

We noticed that in general the mean area did not vary significantly between the control map (10.08 [SD, 6.48] cm<sup>2</sup>) and the final map (7.69 [SD, 9.21] cm<sup>2</sup>); however, the area was clearly greater in the initial map of 9 scars and in the final map of 3, and the estimated size was similar in both maps for the remaining 17 scars. The absolute value of the difference in area between maps was 5.38 [SD, 7.32] cm<sup>2</sup>. In 10 of the 29 scars analyzed, the contact information amended the estimation of the area by more than 50%. Eight conducting channels were detected in the control maps for 6 patients, but were not confirmed in 3 of the patients in the final map. In 3 patients, an additional channel was defined. In 4 patients, areas with low voltage potentials compatible with abnormal areas were observed, which disappeared when the area was remapped in the final map. The areas with no contact in the control maps with potentials < 0.5, 0.5–1.5, and > 1.5 mV were 12.3, 18.5, and 8.6 cm<sup>2</sup>, respectively.

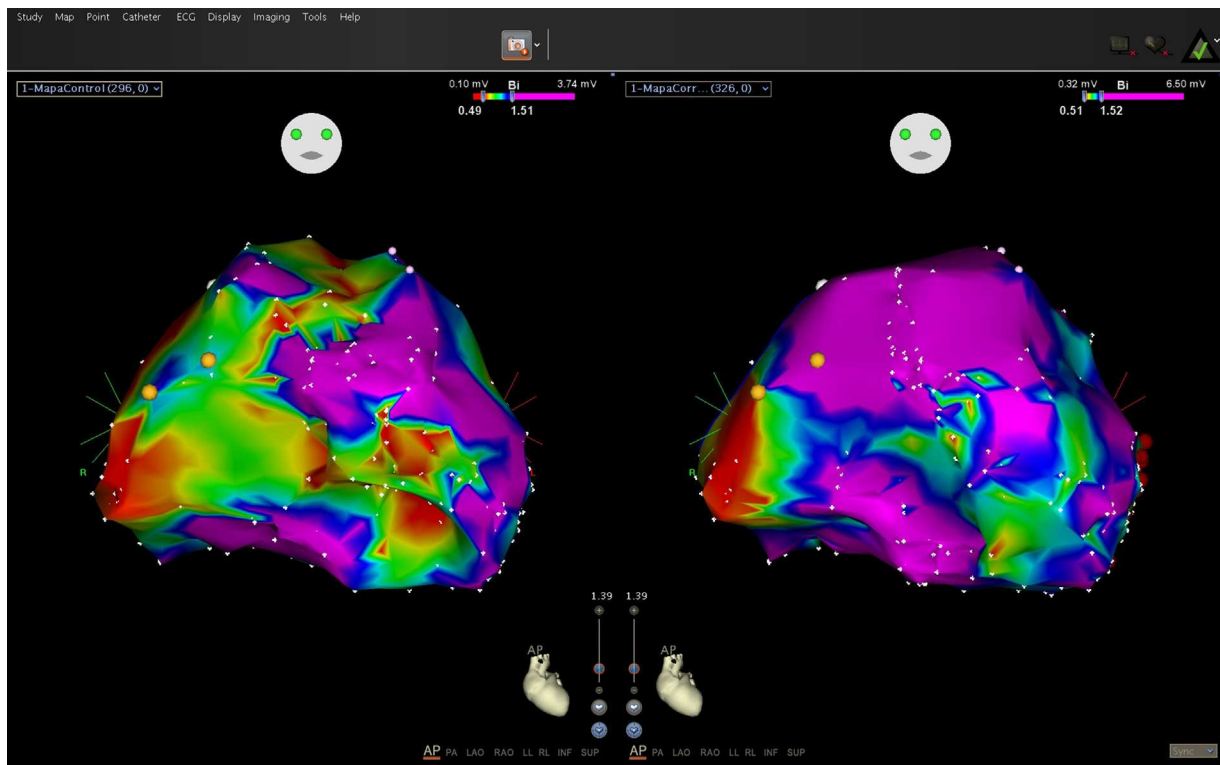
The main finding of the study was the demonstration that the use of a catheter with a force sensor makes it possible to define more precisely the true area of scarring as well as the areas with reduced potentials. Our data confirm that a normal voltage does not imply the existence of contact, as the lack of contact can also generate low-voltage electrocardiograms. The detection of channels was also modified by the contact information. The delimitation of channels depends on the difference between the voltages recorded in one area and the adjacent areas. The evidence of no contact in some areas led to more detailed mapping, making it possible to conclude that the values of the potential were more homogeneous and that a false channel had been assumed in the control map. It has been reported that improved contact increases the sensitivity of detection of late potentials<sup>5</sup>; however, this effect was not observed in our study, possibly due to the small sample size. The choice of the 5 g value as an indication of contact was based on the observation that, with the free catheter in the ventricle during system calibration, the force exerted by blood against the catheter sensor was ≤ 5 g. Other authors have considered different cut-off values,<sup>5</sup> but new studies are needed to define the most appropriate values, both for mapping and for applying radiofrequency with this technology.

We can conclude that inadequate contact of the mapping catheter with the ventricle wall can cause underestimation or

**Table**  
Demographic and Clinical Characteristics

Patient	ICD	Heart disease	Number of infarctions	Location	LVEF	LVEDD	LVESD	Septum	Spontaneous VT morphology	Induced VT morphology
1	Yes	Ischemic	1	Inferior	40	60	52	11	2 ECG ICD	No
2	Yes	Ischemic	1	Inferior	45	44	31	13	No	1 RBBB SUP
3	Yes	Ischemic	1	Anteroapical	25	52	36	13	1 ECG ICD	No
4	Yes	Ischemic	2	Anterior/inferior	31	78	59	6	2 ECG ICD	No
5	No	Ischemic	1	Inferior	51	52	36	13	1 RBBB SUP	1 RBBB SUP
6	No	Ischemic	2	Inferior/septal	43	54	48	10	1 VES: RBBB SUP	No
7	No	Dilated	0	NA	20	67	63	11	1 LBBB SUP	1 LBBB SUP
8	Yes	Ischemic	0	NA	20	60	40	9	1 ECG ICD	No
9	No	Dilated	0	NA	20	59	54	8	4 VES: RBBB INF	No
10	No	Ischemic	1	Septal	28	51	35	9	1 RBBB SUP	1 RBBB SUP
11	No	Ischemic	1	Posteroinferior	45	50	37	12		2 polymorphic

RBBB, right bundle branch block; LBBB, left bundle branch block; ICD, implantable cardioverter defibrillator; ECG, electrocardiogram; LVEDD, left ventricle end-diastolic diameter; LVEF, left ventricular ejection fraction; LVESD, left ventricle end-systolic diameter; INF, inferior frontal axis; NA, not applicable; SUP, superior frontal axis; VT, ventricular tachycardia; VES, ventricular extrasystole.



**Figure.** Initial map (with no contact force data) and final map (corrected with contact force data).

overestimation of the extent of scarring on the electroanatomical map and can hinder interpretation of the areas with low potentials, and that the use of an ablation catheter with a force sensor seems to substantially reduce these errors.

Juan José Sánchez Muñoz,\* Pablo Peñafiel Verdú,  
Juan Martínez Sánchez, Mariela Salar Alcaraz,  
Mariano Valdés Chavarri, and Arcadio García Alberola

Unidad de Arritmias, Servicio Cardiología, Hospital Clínico  
Universitario Virgen de la Arrixaca, IMIB-Arrixaca, Murcia, Spain

\* Corresponding author:  
E-mail address: [juanjosanchezmunoz@me.com](mailto:juanjosanchezmunoz@me.com)  
(J.J. Sánchez Muñoz).

Available online 12 December 2014

## REFERENCES

1. Ávila P, Arenal A. Ablación de sustrato de las taquicardias ventriculares en pacientes con infarto de miocardio antiguo. *Rev Esp Cardiol.* 2014;67:514-8.
2. Ferrero de Loma-Osorio A, Díaz-Infante E, Macías Gallego A; en representación de los colaboradores del Registro Español de Ablación con Catéter. Registro Español de Ablación con Catéter. XII Informe Oficial de la Sección de Electrofisiología y Arritmias de la Sociedad Española de Cardiología (2012). *Rev Esp Cardiol.* 2013;66:983-92.
3. Okumura Y, Johnson SB, Bunch TJ, Henz BD, O'LBBBen CJ, Packer DL. Asystematical analysis of in vivo contact forces on virtual catheter tip/tissue surface contact during cardiac mapping and intervention. *J Cardiovasc Electrophysiol.* 2008;19:632-40.
4. Kuck KH, Reddy VY, Schmidt B, Natale A, Neuzil P, Saoudi N, et al. A novel radiofrequency ablation catheter using contact force sensing: Toccata study. *Heart Rhythm.* 2012;9:18-23.
5. Mizuno H, Vergara P, Maccabelli G, Trevisi N, Eng SC, Brombin C, et al. Contact force monitoring for cardiac mapping in patients with ventricular tachycardia. *J Cardiovasc Electrophysiol.* 2013;24:519-24.

<http://dx.doi.org/10.1016/j.rec.2014.09.011>

## Systolic Aortic Regurgitation. A New Prognostic Marker in Heart Failure Patients?



### *Insuficiencia aórtica sistólica. ¿Un emergente marcador pronóstico en pacientes con insuficiencia cardíaca?*

To the Editor,

Aortic regurgitation usually occurs during diastole, although in certain situations, such as atrial fibrillation or extrasystoles, systolic aortic regurgitation (SAR) has been reported. This phenomenon is a reflection of mechanical failure of the ventricle and arises because the left ventricle is unable to generate the necessary pressure to open the aortic valve, leading to a systolic gradient between the aorta and the left ventricle. In fact, SAR has

been associated with the presence of heart failure (HF).<sup>1</sup> The objective of this study was to assess the prevalence of SAR in an unselected outpatient population and determine the relationship between SAR and HF.

In this prospective observational study lasting 15 months (January 2012 through March 2013), data were collected from all outpatients referred to our echocardiography laboratory, where the same operator recorded all echocardiograms. The presence of HF was assessed according to the current clinical practice guidelines.<sup>2</sup> Patients with aortic regurgitation of any severity and atrial fibrillation or extrasystoles underwent a 60-s continuous-wave Doppler assessment of aortic regurgitation in the 5-chamber apical view. In the echocardiography study, SAR was defined as the presence of holosystolic flow from the aorta to the left ventricular outflow tract. Admissions to