

5. Benussi S, Mazzone P, Maccabelli G, Vergara P, Grimaldi A, Pozzoli A, et al. Thoracoscopic appendage exclusion with an atriclip device as a solo treatment for focal atrial tachycardia. *Circulation*. 2011;123:1575–8.
6. Kilic A, Amasyali B, Kose S, Aytemir K, Kursaklioglu H, Lenk MK. Successful Catheter Ablation of a Right-Sided Accessory Pathway in a Child With Interrup-

tion of the Inferior Vena Cava and Azygos Continuation. *Int Heart J*. 2005;46:537–41.

<http://dx.doi.org/10.1016/j.rec.2016.04.008>

Usefulness of Reciprocal Changes in the Diagnosis of Myocardial Infarction With Minimal ST-segment Elevation



Utilidad de las alteraciones especulares en el diagnóstico del infarto con elevación mínima del segmento ST

To the Editor,

Minimal ST-elevation often leads to inappropriate diagnoses and delayed interventions. Recent studies have shown that between 11% and 23% of infarctions do not reach the cutoff for accepted electrocardiographic criteria for infarction, and the absence of such criteria is not associated with a more favorable prognosis.^{1,2} The main objective of this study was to analyze the prevalence of reciprocal changes (RC) as a diagnostic tool in myocardial infarction with minimal ST-elevation.

The study was based on a prospective registry of 480 consecutive patients with a definitive diagnosis of infarction who underwent emergency coronary angiography as part of a systematic primary angioplasty program between 2009 and 2011. The present study comprised 75 patients with a maximum ST-elevation of 0.01 to 0.1 mV and who could be assessed for RC. The indication for catheterization was based on persistent symptoms of ischemia. No patient received thrombolysis during the study period.

Reciprocal changes were defined as J point depression ≥ 0.05 mV in the TP segment, in at least 1 lead other than the aVR lead. All patients provided informed consent prior to participation.

Variables were compared using the chi-square test, the Fisher exact test, and the Mann-Whitney *U* test. The variables associated with RC with $P < .1$ (age, site, multivessel disease) were included in the multivariate logistic regression model to assess whether they were independently associated.

In total, 51 patients had RC (prevalence 68%, 95% confidence interval [95%CI], 57%-79%), which was attributed to an ischemic cause in all of them. In 27 patients, a depression ≥ 0.1 mV was observed and, in all patients except 1, the slope was horizontal or decreasing.

Among the 24 remaining patients, 17 showed an ST-depression of 0.01–0.04 mV ($n = 15$) or negative or symmetric T waves ($n = 10$). Overall, 68 patients had some sort of RC that supported diagnosis (91%; 95%CI, 84%-97%) (Figure).

The Table shows the characteristics of the groups according to the presence of RC. In all patients, initial thrombolysis in myocardial infarction (TIMI) flow was 0/1 or creatinine kinase was elevated to more than 3 times the upper limit of normal. Although the enzyme concentrations were similar, patients with RC showed a tendency toward a higher incidence of heart failure during hospitalization (31% vs 12%; $P = .080$).

In the analysis by infarction site, the prevalence of RC was 38% (95%CI, 8%-69%) in anterior acute myocardial infarction, 70% (95%CI 35%-100%) in lateral or inferobasal infarction, and 75% (95%CI, 63%-87%) in inferior infarction ($P = .041$). In the multivariate analysis, nonanterior site was independently associated with the presence of RC (odds ratio = 4.6; 95%CI, 1.3–16.1; $P = .017$).

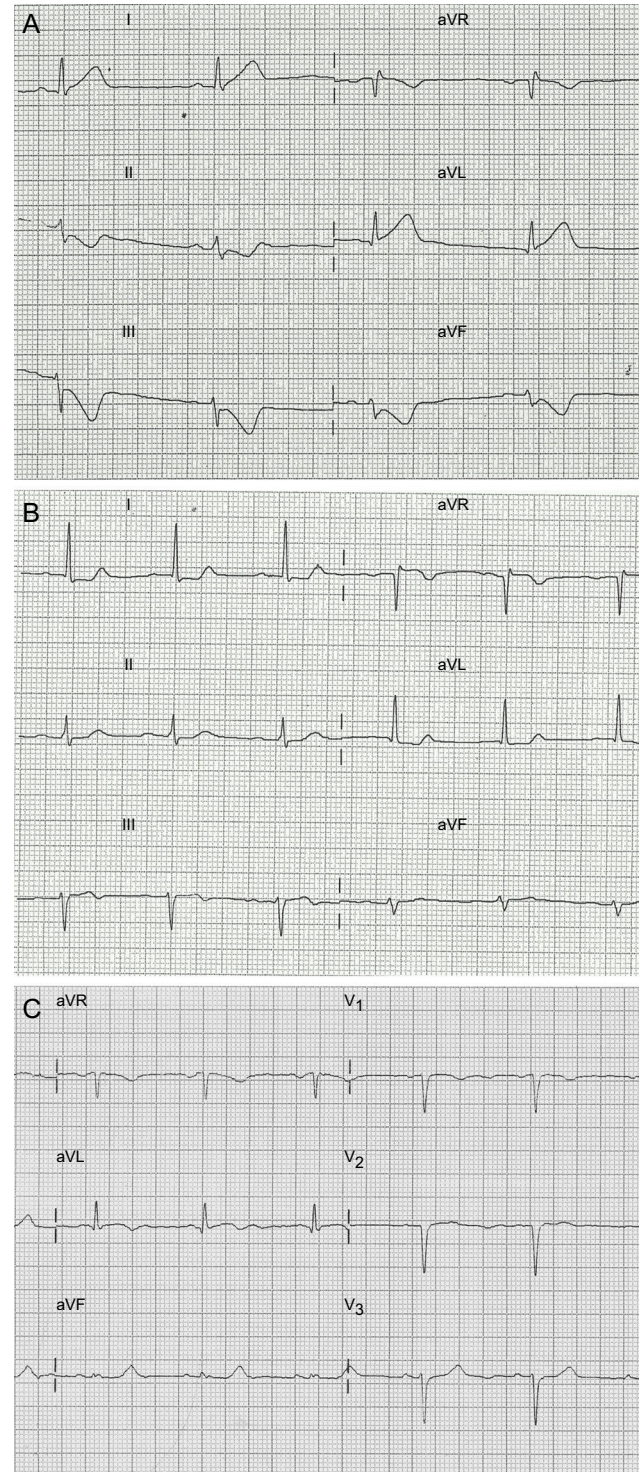


Figure. Electrocardiographic patterns of patients included in the study. A: Reciprocal ST-segment depression > 0.1 mV. B: Reciprocal depression of 0.05 mV. C: Reciprocal depression < 0.05 mV and symmetric T wave change.

Table

Clinical and Angiographic Findings in Patients in the Study According to the Presence of Reciprocal Changes

	No RC (n = 24)	RC (n = 51)	P
Baseline characteristics			
Age, y	58 [48–69]	66 [55–75]	.055
Male sex	17 (71)	40 (78)	.472
Hypertension	14 (58)	29 (57)	.904
Diabetes mellitus	5 (21)	13 (25)	.660
Dyslipidemia	10 (42)	27 (53)	.362
Current smoker	16 (67)	28 (55)	.334
Chronic kidney disease	2 (9)	8 (16)	.485
Prior myocardial infarction	4 (17)	7 (14)	.740
Clinical presentation			
Anterior site	8 (33)	5 (10)	.02
Symptoms-to-door time, min	151 [60–582]	170 [85–227]	.931
Door-to-balloon time, min	111 [58–187]	85 [66–132]	.378
Q wave	9 (37)	18 (35)	1.0
Corrected QT > 450 ms	7 (29)	15 (30)	1.0
LVEF, %	62 [47–72]	59 [50–67]	.327
Maximum troponin I, ng/mL	18 [12–69]	26 [12–49]	.782
Maximum CK, U/L	930 [524–2140]	972 [526–1573]	.857
Angiography findings			
Culprit artery			.448
Anterior descending	8 (33)	9 (18)	
Circumflex	6 (25)	16 (31)	
Right coronary	10 (42)	25 (49)	
Venous graft	0 (0)	1 (2)	
Basal TIMI flow 0/1	18 (82)	41 (85)	.731
Multivessel disease	10 (42)	32 (63)	.086

CK, creatinine kinase; LVEF, left ventricular ejection fraction; RC, reciprocal change; TIMI, thrombolysis in myocardial infarction.

Data expressed as no. (%) or median [interquartile range].

An important finding in this study of patients with minimal ST-elevation treated with systematic primary angioplasty is that two-thirds of the patients with borderline electrocardiogram and no diagnosis of myocardial infarction showed reciprocal depression ≥ 0.05 mV and 91% had some type of RC that was useful for early diagnosis of infarction.

One aspect worthy of discussion is whether to adjust the cutoff for defining RC in patients with borderline electrocardiogram. The ST segment should, in normal conditions, be isoelectric or show a depression < 0.05 mV. Classical studies of ST-elevation myocardial infarction show reciprocal depression ≥ 0.1 mV in approximately 60% of inferior infarctions and 30% of anterior infarctions.^{3,4} In a study of 126 infarctions with minimal ST elevation, Jang et al¹ reported RC in 58%. In our study, lowering the cutoff to 0.05 mV enabled detection of RC in 68% of patients compared with 36% when a cutoff of 0.1 mV was used. Along these lines, it has been observed that a certain degree of ST depression is

an almost universal finding in inferior infarction and is very uncommon in pericarditis.^{5,6} These arguments would therefore support the use of a more lax criterion (≥ 0.05 mV) for a condition in which diagnostic sensitivity is of the utmost importance.

Moreover, the presence of RC may have prognostic implications. Some studies have associated RC with the extent of myocardium at risk and with multivessel disease.³ In our series, the patients with RC showed a tendency toward more multivessel disease and a greater incidence of heart failure during hospitalization.

Among the limitations of the study, of note is the absence of a control group, although the aforementioned studies have shown that RC are uncommon in other entities and their presence would be more specific for infarction. We did not include patients not undergoing coronary angiography. Nevertheless, the high proportion of patients with minimal ST-elevation suggests that the sample is representative of the study population.

In conclusion, RC is extremely useful for identifying and enabling early treatment of patients with chest pain and minimal ST-elevation in inferior and lateral leads. In anterior infarction, the absence of RC is common, and therefore diagnosis should consider other clinical, electrocardiographic, and imaging criteria.

David Martí,^{a,*} Luisa Salido,^b José Luis Mestre,^b Eduardo Casas,^b María Jesús Esteban,^b and José Luis Zamorano^b

^aServicio de Cardiología, Hospital Central de la Defensa Gómez Ulla, Universidad de Alcalá, Madrid, Spain

^bServicio de Cardiología, Hospital Universitario Ramón y Cajal, Universidad de Alcalá, Madrid, Spain

* Corresponding author:

E-mail address: docalcala@hotmail.com (D. Martí).

Available online 8 June 2016

REFERENCES

- Jang SY, Bae MH, Kim JH, Park SH, Lee JH, Yang DH, et al. Predictors and clinical implications of minimal ST-segment elevation in patients with ST-segment elevation myocardial infarction. *Cardiology*. 2014;128:273–81.
- Martí D, Mestre JL, Salido L, Esteban MJ, Casas E, Pey J, et al. Incidence, angiographic features and outcomes of patients presenting with subtle ST-elevation myocardial infarction. *Am Heart J*. 2014;168:884–90.
- Peterson ED, Hathaway WR, Zabel KM, Pieper KS, Granger CB, Wagner GS, et al. Prognostic significance of precordial ST segment depression during inferior myocardial infarction in the thrombolytic era: results in 16,521 patients. *J Am Coll Cardiol*. 1996;28:305–12.
- Sasaki K, Yotsukura M, Sakata K, Yoshino H, Ishikawa K. Relation of ST-segment changes in inferior leads during anterior wall acute myocardial infarction to length and occlusion site of the left anterior descending coronary artery. *Am J Cardiol*. 2001;87:1340–5.
- Bischof JE, Worrall C, Thompson P, Martí D, Smith SW. ST depression in lead aVL differentiates inferior ST-elevation myocardial infarction from pericarditis. *Am J Emerg Med*. 2016;34:149–54.
- Adler Y, Charron P, Imazio M, Badano L, Barón-Esquivias G, Bogaert J, et al. Guía ESC 2015 sobre el diagnóstico y tratamiento de las enfermedades del pericardio. *Rev Esp Cardiol*. 2015;68:1126.

<http://dx.doi.org/10.1016/j.rec.2016.03.021>