

## Image in cardiology

## Unusual Case of Huge In-transit Thrombus: a Challenge for Three-dimensional Echocardiography

## Caso inusual de trombo gigante en tránsito: un reto para el eco-3D

Oscar Salvador Montañés,\* Teresa López Fernández, and Mar Moreno Yangüela

Servicio de Cardiología, Hospital Universitario La Paz, Madrid, Spain

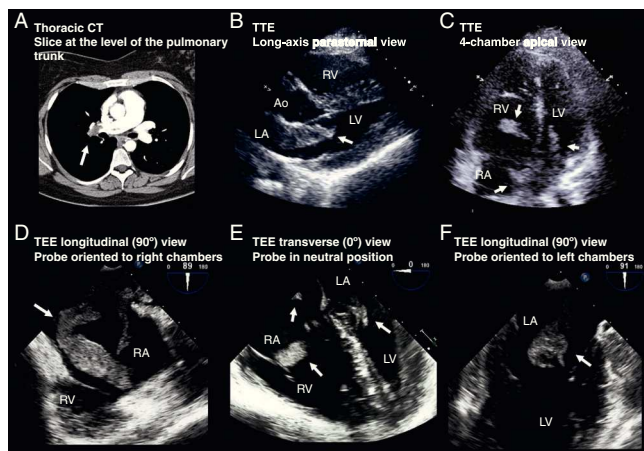


Figure 1.

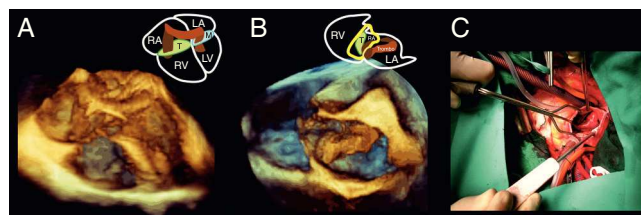


Figure 2.

A 29-year-old woman was admitted to the emergency room of our hospital with sudden dyspnea and pleuritic pain. Ten months previously she had had a normal full term delivery, after which she experienced deep venous thrombosis. At emergency room admission, her heart rate was 110 bpm and blood pressure was 90/69 mmHg. An S1Q3T3 pattern was observed on electrocardiography. Computed tomography (CT) study disclosed a massive pulmonary thromboembolism (Fig. 1A). Transthoracic echocardiography (TTE) (Figs. 1B and C, video 1) showed large masses (white arrows) in both atria, protruding through the 2 atrioventricular valves (Ao, aorta; RA, right atrium; LA, left atrium; RV, right ventricle; LV, left ventricle). We performed 2-dimensional (2D) (Figs. 1D-F, video 2) and 3D (Figs. 2A and B, videos 3-6) transesophageal echocardiography (TEE), which demonstrated that the patient had a large, morphologically complex mass (white arrow) passing through a patent foramen ovale. The patient was surgically treated with thrombectomy (Fig. 2C) and suturing of the foramen ovale. Pathology confirmed the diagnosis of a thrombus. The patient was discharged 1 week later with no incidents.

Pulmonary thromboembolism is a common complication of deep venous thrombosis, but demonstration of the thrombus in transit is unusual. Because of the considerable risk of systemic embolism, the treatment of choice is surgical thrombectomy. Although no cases have yet been recorded in the literature, 3D TEE may be useful to accurately show the anatomy of the mass and interatrial septum.

## SUPPLEMENTARY MATERIAL



Supplementary material (videos) associated with this article can be found in the online version available at <http://dx.doi.org/10.1016/j.rec.2012.02.023>.

\* Corresponding author:

E-mail address: [oscarsalvador24@gmail.com](mailto:oscarsalvador24@gmail.com) (O. Salvador Montañés).

Available online 28 June 2012