

The Right Heart and Pulmonary Circulation (XI)

Tricuspid and Pulmonary Valve Disease Evaluation and Management

Pravin M. Shah

Chair and Medical Director, Hoag Heart Valve Center, Hoag Memorial Hospital Presbyterian, Newport Beach, CA, United States

The clinical detection and quantification of tricuspid valve disease, although important, is not entirely accurate. Diagnostic evaluation is based on echocardiography, and color flow Doppler is useful for quantifying tricuspid regurgitation. Echocardiography provides information on heart chamber dimensions, right ventricular function, and the degree of pulmonary hypertension. In addition, tricuspid stenosis can be accurately assessed using mean and end-diastolic pressure gradient measurements. The treatment options for tricuspid stenosis include balloon valvuloplasty and surgical valve repair. Functional tricuspid regurgitation associated with left heart disease may require surgical attention during an operation to treat the left heart disease. Severe tricuspid regurgitation usually requires surgery to be performed in association with mitral valve surgery. Mild-to-moderate tricuspid regurgitation requires surgery when annular dilatation or severe pulmonary hypertension is present. The surgical options include tricuspid valve repair, with or without an annuloplasty ring. In patients with a primary anatomic deformity of the tricuspid valve, replacement of the valve with a bioprosthesis or mechanical valve may be considered. Intermediate and long-term results favor annuloplasty valve repair over valve replacement. Pulmonary valve disease is predominantly congenital, and generally takes the form of pulmonary stenosis. Pulmonary regurgitation often results from surgical or balloon valvuloplasty and is associated with deleterious long-term sequelae. The recent development of percutaneous valve replacement was a major advance.

Key words: *Tricuspid regurgitation. Tricuspid valve repair. Pulmonary stenosis. Percutaneous pulmonary valve replacement.*

Valvulopatía tricuspídea y pulmonar: evaluación y tratamiento

La detección clínica y la cuantificación de la valvulopatía tricuspídea, a pesar de su importancia, no son del todo exactas. La ecocardiografía es la base de la evaluación diagnóstica y el Doppler-color es útil para la cuantificación de la insuficiencia tricuspídea. La ecocardiografía proporciona información relativa a los tamaños de las cámaras, la función ventricular derecha y el grado de hipertensión pulmonar. De igual modo, la estenosis tricuspídea puede evaluarse de forma exacta con el empleo de gradientes medios y telediastólicos. Las opciones de tratamiento para la estenosis tricuspídea incluyen la valvuloplastia con balón y la reparación quirúrgica de la válvula. La insuficiencia tricuspídea funcional asociada a una cardiopatía izquierda puede requerir atención quirúrgica durante la operación por una afección del corazón izquierdo. La insuficiencia grave requiere generalmente una actuación quirúrgica asociada a la cirugía de la válvula mitral. La insuficiencia tricuspídea leve o moderada requiere cirugía en caso de dilatación anular o hipertensión pulmonar grave. Las opciones quirúrgicas incluyen la reparación de la válvula tricúspide con o sin anuloplastia. En los pacientes con una deformidad anatómica primaria de la válvula tricúspide, puede considerarse una sustitución valvular con una bioprótesis o una válvula mecánica. Los resultados a medio y largo plazo son favorables a la reparación valvular con anuloplastia, en comparación con la sustitución valvular. La valvulopatía pulmonar es de etiología predominantemente congénita, por lo general en forma de estenosis pulmonar. La insuficiencia pulmonar con frecuencia se debe a una valvuloplastia quirúrgica o con balón y tiene secuelas negativas a largo plazo. Los progresos recientes en la sustitución valvular percutánea son importantes.

Palabras clave: *Insuficiencia tricuspídea. Reparación de válvula tricúspide. Estenosis pulmonar. Sustitución percutánea de válvula pulmonar.*

TRICUSPID VALVE DISEASE

Tricuspid valve (TV) is often referred to as the forgotten valve and is considered deserving of more respect. However, recent literature is replete with emphasis on TV disease and its long term

Correspondence: P. M. Shah, MD, MACC, Chair, Medical Director, Hoag Heart Valve Center, Hoag Memorial Hospital Presbyterian, Newport Beach, CA, USA
E-mail: pshah@hoaghospital.org

ABBREVIATIONS

PASP: pulmonary artery systolic pressure
 PISA: proximal isovelocity surface area
 PR: pulmonary regurgitation
 PS: pulmonary stenosis
 TEE: transesophageal echocardiography
 TR: tricuspid regurgitation
 TV: tricuspid valve

implications.^{1,4} A variety of surgical approaches have been introduced. Intermediate and long term outcome of some of these surgical options is promising.⁵ The present report will attempt to summarize the current understanding of the TV disorders in terms of diagnosis, prognosis and treatment.

Embryology

The septation of atria and ventricles in the fetal circulation is followed by formation of endocardial cushions at the crux of the heart. The atrioventricular (AV) valves develop subsequently. The architecture of the two AV valves is intimately tied to the corresponding ventricles. This relationship demonstrates that the mitral valve is connected to the anatomic left ventricle and the TV to the anatomic right ventricle. This relationship is emphasized in the congenitally corrected transposition of great arteries with functionally intact circulation, such that the anatomic right ventricle becomes the systemic ventricle and anatomic left ventricle the pulmonary ventricle. The corresponding AV valves are transposed along with the ventricles. Thus, the TV becomes a left sided valve between the left atrium and anatomic right ventricle, which is the systemic ventricle connected to the aorta. Similarly the mitral valve is transposed with anatomic left ventricle, which is the pulmonary ventricle connected to the pulmonary artery and low resistance pulmonary circulation. Congenitally corrected transposition in absence of other malfunctions is compatible with life into the sixth and seventh decades. This speaks to the adaptation of the anatomic right ventricle and TV to high pressure, high resistance systemic circulation.

Since the formation of AV cushions at the crux of the heart are central to distinctive anatomy of

the two atrioventricular valves, the congenital absence of AV cushions, partial or complete, results in striking abnormalities of the two AV valves. The attachment of the septal leaflet of the TV is normally more apical than the mitral valve, and a small defect is capable of providing shunting of blood from the left ventricle to the right atrium. This defect, when isolated, is anatomically small and is known as Gerbode defect. Another anatomic consideration is that the septal leaflet of the TV is attached to membranous ventricular septum. Thus, perimembranous ventricular septal defects distort this portion of the TV, which can grow over the defect, resulting in spontaneous closure of small membranous VSD in childhood.

Valve Anatomy

The TV is most caudally located and has the largest orifice of the 4 intracardiac valves. It functions as a unidirectional valve permitting systemic venous blood flow from right atrium and hence from the 2 vena cava to advance to the right ventricle during diastole and prevents backflow or regurgitation during systole. The TV apparatus is composed of the annulus, the leaflets, the chordae and papillary muscles. Its coordinated function is also influenced by the geometric alterations of the right ventricle and the right atrium.

The annulus: The tricuspid annulus is oval in shape, but assumes a more circular shape on dilatation. It has been shown to have a more complex nonplanar shape with postero-septal commissure the highest point. The shape, besides becoming more circular, flattens out and becomes more planar in presence of severe “functional” regurgitation. The annular diameter, circumference and area are all larger than the mitral valve by about 20 percent. Although major tricuspid annular diameter values of 30-35 mm are described for normal adults (BSA 1.5-1.7 m²), the orifice size is influenced by overall body size as reflected in body surface area. Thus, while a measured diameter of 40 mm in an average size normal adult represents dilated annulus, this may be normal for a person with BSA in excess of 2.0 m². Thus, size of an individual patient must be considered in assigning the given measure as normal or abnormal. The average normal annular diameter is 21 (2) mm/m². A hemodynamic consequence of a larger tricuspid annulus orifice is lower velocities and lower pressure drops during diastolic inflow than in the normal mitral valve. The annulus exhibits a dynamic behavior similar to the mitral annulus, with expansion of the orifice in diastole and reduction in systole.⁶ The maximum to minimum area reduction is nearly 30%. This dynamic behavior promotes forward flow while

maintaining low right atrial and thus systemic venous pressures.

The TV has 3 leaflets; anterior, septal and posterior, the anterior being the largest and septal being the smallest. The septal leaflet attachment is from posterior ventricular wall across the interventricular septum, its insertion being more apical relative to the anterior leaflet. The anterior leaflet is attached to the right AV junction. The posterior leaflet has mural attachment.

The tendinous chords are attached to the ventricular surface of the leaflets or the free edges of the leaflets to the papillary muscle supporting the leaflet. There may be accessory chords that attach from the septal leaflet to the moderator band or the right ventricular free wall.

There are 3 sets of papillary muscles, each set being composed of up to 3 muscles. The chordae arising from each set are inserted into 2 adjacent leaflets. Thus, the anterior set of chordae insert into half of the anterior and half of the posterior leaflets, the medial set provides chordae to anterior and septal leaflets. The third, posterior, set is more rudimentary and is attached to the diaphragmatic wall of the right ventricle.⁷

Normal Tricuspid Valve Function

The diastolic opening of the valve along with corresponding expansion of the annulus provides a tricuspid orifice area of 7-9 cm². This large orifice provides unimpeded flow both at rest and with physical activity without elevations in central venous pressures. The systolic narrowing of the orifice provides an effective seal for valve closure; however, a measure of tricuspid regurgitation (TR) detected by Doppler echocardiography is observed in 80%-90% of normal subjects. The majority of patients with physiologic TR are in the mild category, but a small number of otherwise healthy individuals may have moderate regurgitation. A failure to appreciate this may result in identifying as abnormal what is a normal variant.

Tricuspid Valve Dysfunction

The TV disease is generally classified as primary or intrinsic valve pathology or secondary or functional valve dysfunction.^{8,9} The primary valve disease results from structural abnormality of the valve apparatus. The secondary or functional TV disease results from factors that generally lead to tricuspid annular dilatation, commonly from left heart disease and resulting right ventricular hypertension, dilatation and dysfunction (Figure 1).¹⁰

A classification of TV disease according to etiology is given in Table 1.

Clinical Presentation

The abnormal valve function may be in form of: *a)* pure or predominant tricuspid stenosis; *b)* pure or predominant TR; or *c)* mixed.

Generally the symptoms of left heart disease predominate in those with secondary TV disease. The symptoms specific to advanced TV disease are related to: *a)* decreased cardiac output, for example, fatigue; *b)* right atrial hypertension, for example, liver congestion resulting in right upper quadrant discomfort, or gut congestion with symptoms of dyspepsia, indigestion, or fluid retention with leg edema and ascites. It may be emphasized that significant TV disease may not be associated with any symptoms until a late stage of the disease involving progressive right ventricular dysfunction. Symptoms caused by underlying etiology such as flushing, diarrhea, abdominal pain, etc. associated with carcinoid heart disease point to the etiology.

Physical findings include signs related to TV disease and those secondary to chronic venous congestion, that is, leg edema and ascites. Tricuspid stenosis results in characteristic changes in the jugular venous pulse in form of a slow "V" to "Y" descent and prominent "A" waves. The liver is enlarged with a firm edge, and pulsatile in presystole. Auscultation reveals a low-to-medium-pitched diastolic rumble with inspiratory accentuation. This is usually localized to the lower sternal border.¹¹

TR results in the jugular venous pulse exhibiting a prominent "C-V" wave or systolic wave. There is often a parasternal lift from right ventricular enlargement. The liver shows systolic pulsations, is enlarged and often tender. The cardiac auscultation reveals a soft early or holosystolic murmur which is augmented with inspiratory effort (Carvallo sign). A systolic honk may be present with TV prolapse.¹² Substantial TR may exist without the classic auscultatory findings. Thus, neither presence nor quantitation of TR can be reliably judged by auscultation. The pulsatile liver is a sign of severe regurgitation.

Laboratory Diagnosis

Electrocardiogram: There are no specific markers of TV disease, although the following clues may be present: *a)* right ventricular (RV) hypertrophy and "strain" with right QRS axis; and *b)* right atrial enlargement with prominent P waves. Specific ECG signs of primary etiology may be noted, such as left axis deviation and complete right bundle branch block in AV canal defect associated with cleft valve, and Ebstein's anomaly may exhibit wide QRS.

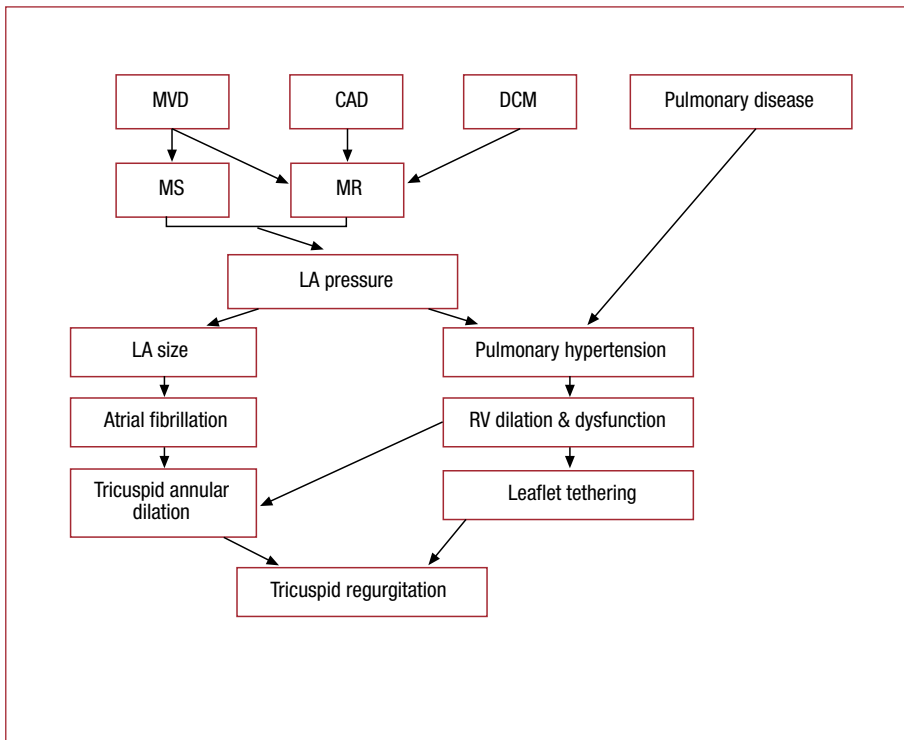


Figure 1. Pathogenesis of functional tricuspid regurgitation. CAD, coronary artery disease; DCM, dilated cardiomyopathy; LA, left atrial; MS, mitral stenosis; MR, mitral regurgitation; MVD, mitral valve disease. Modified from Shiran et al.¹⁰

TABLE 1. Etiology of Tricuspid Valve Disease

Primary tricuspid valve disease	
Congenital	
	Ebstein's anomaly Congenital cleft valve Congenital tricuspid stenosis Tricuspid atresia
Acquired	
	Rheumatic Infective endocarditis Degenerative. Tricuspid valve prolapse Carcinoid heart disease Toxic (eg, Phen-Fen or methysergide valvulopathy) (?) Tumors (eg, fibroelastoma, myxoma) Trauma Iatrogenic (eg, pacemaker lead trauma, radiation injury, biopsy instrument)
Secondary or functional tricuspid valve disease	
	Right ventricular dilatation (eg, atrial septal defect, pulmonary regurgitation) Right ventricular hypertension (eg, pulmonary hypertension, pulmonary stenosis) Right ventricular dysfunction (eg, cardiomyopathy, myocarditis) Segmental right ventricular dysfunction (eg, ischemia or infarction, endomyocardial fibrosis, arrhythmogenic right ventricular dysplasia) Chronic atrial fibrillation (asymmetric tethering leads to eccentric jet)

Chest radiograph: cardiomegaly associated with prominent right-heart borders may be noted. There are no specific findings to suggest a diagnosis of TV disease.

Echocardiography: 2-dimensional echocardiogram combined with spectral and color flow Doppler evaluation provides the most accurate laboratory test in detection and quantitation of TV disease.

In addition, the TV morphology provides clues of underlying etiology and pathophysiology of valve dysfunction.¹³

Tricuspid valve morphology: Ebstein's anomaly is characterized by apical displacement of the septal tricuspid leaflet into the right ventricle by more than 8 mm/m² from the insertion point of the anterior mitral leaflet from the crux. The right atrium is enlarged, composed of anatomic right atrium proper and atrialized proximal inflow right ventricle. The residual right ventricle is reduced in size.

AV cushion defect with associated cleft valve abnormality is best seen in apical 4 chamber view. The mitral and TVs are seen as a common valve straddling the defect. The cleft may be visualized with confirmation by color flow image showing the regurgitation jet going across the valve abnormality.

Carcinoid heart disease is characterized by thickened immobile valve leaflets held in half open position, resulting in appearance of stenosis as well as free flowing regurgitation with color flow Doppler (Figure 2).¹⁴

Rheumatic TV disease is nearly always associated with rheumatic mitral and/or aortic valve disease. The valve leaflets are thickened and exhibit some doming in diastole.

TV prolapse is seen in nearly 30% of patients with mitral valve prolapse. The characteristic appearance includes dilated annulus, billowing prolapse, less commonly chordae rupture with flail leaflet (Figure 3).¹⁴ Apart from the general syndrome of degenerative valve disease, TV prolapse has been described in congenital heart disease associated with systemic right ventricles.

Infective endocarditis is generally apparent with demonstration of mobile vegetation with transthoracic echocardiography. In some cases, the transesophageal approach may be used for confirmation. Differentiation of a vegetation from a tumor requires clinical correlation (Figure 4).¹⁴

Valvulopathy associated with Phen-Fen and methysergide consists of thickened, fibrotic, less mobile tricuspid leaflets. These appearances are non-specific and require historical confirmation of drug use.

Pacemaker lead related trauma exhibits leaflet entrapment by a pacemaker lead. The color flow jet of TR may be localized at the pacemaker contact site along the tricuspid leaflet. Less commonly, leaflet perforation may be noted.

Secondary or functional TR is characterized by annular dilatation, generally the annular diameter greater than 40 mm, and tethering of leaflets with tenting distance in excess of 8 mm. In extreme cases, the leaflets fail to coapt with wide open

regurgitation. Severe right ventricular hypertension is associated with shift of the interventricular septum toward the left ventricle, resulting in asymmetric tethering. In addition, characteristic appearances of right ventricular infarction, arrhythmogenic right ventricular dysplasia, or myocarditis and cardiomyopathy may be observed.

Detection and Quantitation of Tricuspid Valve Disease

Color flow Doppler and spectral Doppler are sensitive for detection of valve regurgitation and generally accurate for semiquantitative assessment of tricuspid stenosis and regurgitation.¹⁵ Tricuspid stenosis is detected with color flow imaging by demonstrating a central core of high velocity jet. The continuous wave Doppler permits measurements of mean and end-diastolic gradients. The normal mean gradient is less than 3 mm Hg and the end diastolic gradient nearly zero. Severe stenosis is associated with mean gradient of 5 mm Hg and pressure half time measured in end inspiratory beat is greater than 190 ms. It has been proposed, but not well validated, that TV area may be determined by 190 divided by pressure half time.

TR using color flow imaging is readily recognized from parasternal tricuspid inflow view, short axis view, and apical or subcostal four chamber cross sections. Regurgitant jet area correlates roughly with severity of regurgitation, being less than 5 cm² in mild, 6-10 cm² in moderate and greater than 10 cm² in severe cases. In clinical practice, a visual estimate rather than actual planimetry is utilized. A more accurate estimate may be obtained by utilizing flow acceleration and PISA (Proximal Isovelocity Surface Area) measurements from which regurgitant orifice area may be calculated. The measured PISA radius is by itself a good guide to severity of regurgitation. The technique is important. The color flow baseline should be shifted in direction of regurgitation to get aliased velocity of approximately 30 cm/sec. The radius of hemispherical PISA of greater than 9 mm indicates severe, 5-9 mm moderate, and less than 5 mm mild regurgitation. The spectral Doppler image of TR represents pressure gradient between right ventricle and right atrium through systole. The shape of TR velocity profile using continuous wave Doppler provides a clue to this relationship. The regurgitation profile is generally parabolic except in severe cases, where high right atrial "C-V" waves result in rapid equalization with right ventricular pressure giving a profile with rapid deceleration, also described as 'V' wave cut off sign (Figure 5).¹⁴ Additional indirect clues of regurgitation severity are density of continuous wave Doppler profile, size of right ventricle and atrium, paradoxical

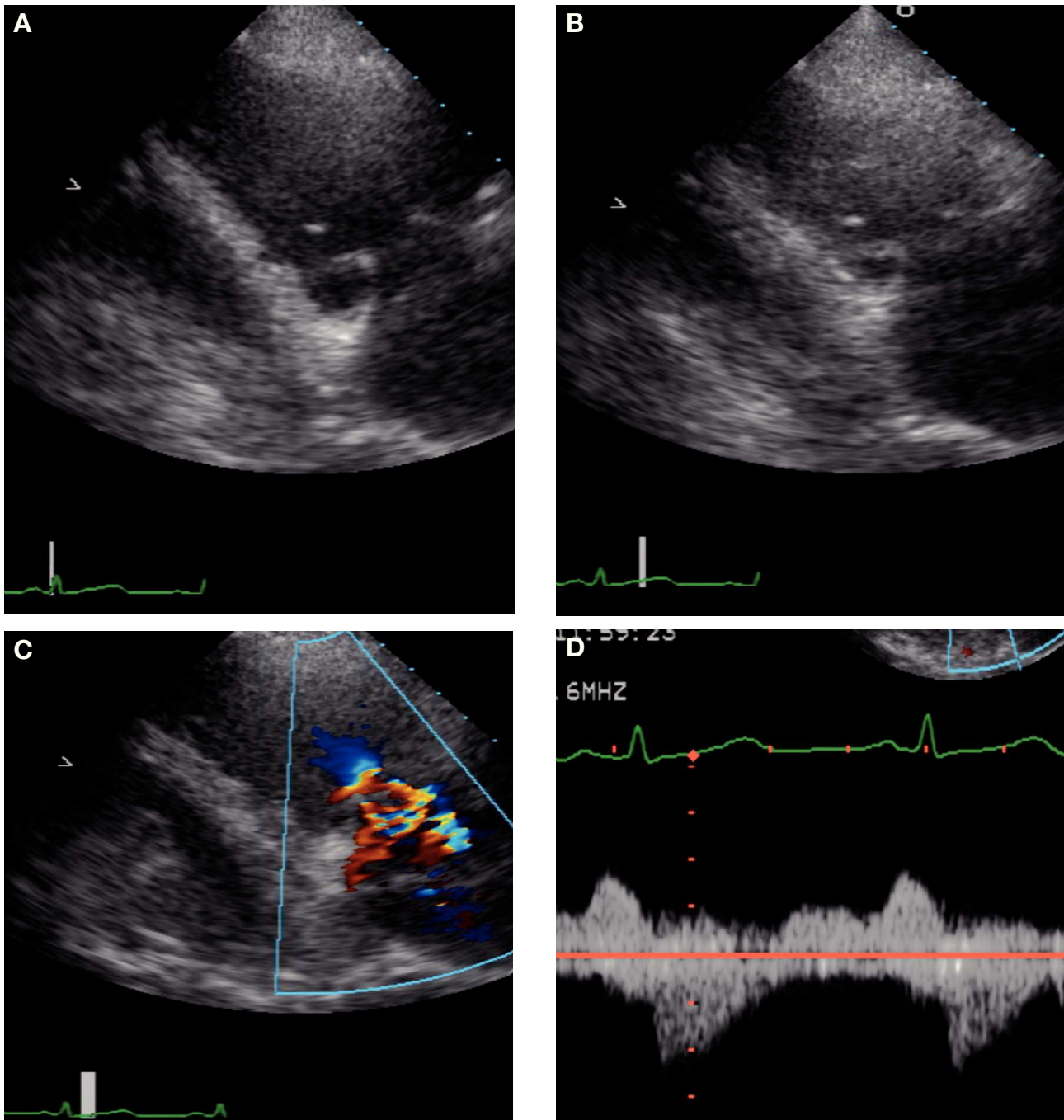


Figure 2. Echocardiographic images in 48-year-old man with carcinoid heart disease. A: end-diastolic frame showing the tricuspid valve (TV) in the open position. B: the TV in the end-systolic frame is in a partially open position. C: this characteristic valve restriction results in severe tricuspid regurgitation. D: the continuous-wave Doppler shows several characteristic features. The systolic velocity of early peak and rapid deceleration indicate high right atrial pressure. The diastolic velocity with slow early deceleration and a prominent presystolic flow is consistent with some degree of tricuspid stenosis.

interventricular septal motion, and systolic bulge of interatrial septum toward left atrium. The hepatic vein flow may exhibit systolic reversal of flow in severe cases.

A calculation of right ventricular systolic pressure (ie, pulmonary artery systolic pressure in absence

of outflow obstruction) using peak TR velocity is extremely useful in clinical practice. The formula used is: Right Ventricular Systolic Pressure = $4 \times \text{TR velocity} + \text{right atrial pressure}$.¹⁶ The latter may be assumed to be 7-10 mm, or more accurately determined from size of inferior vena cava and its

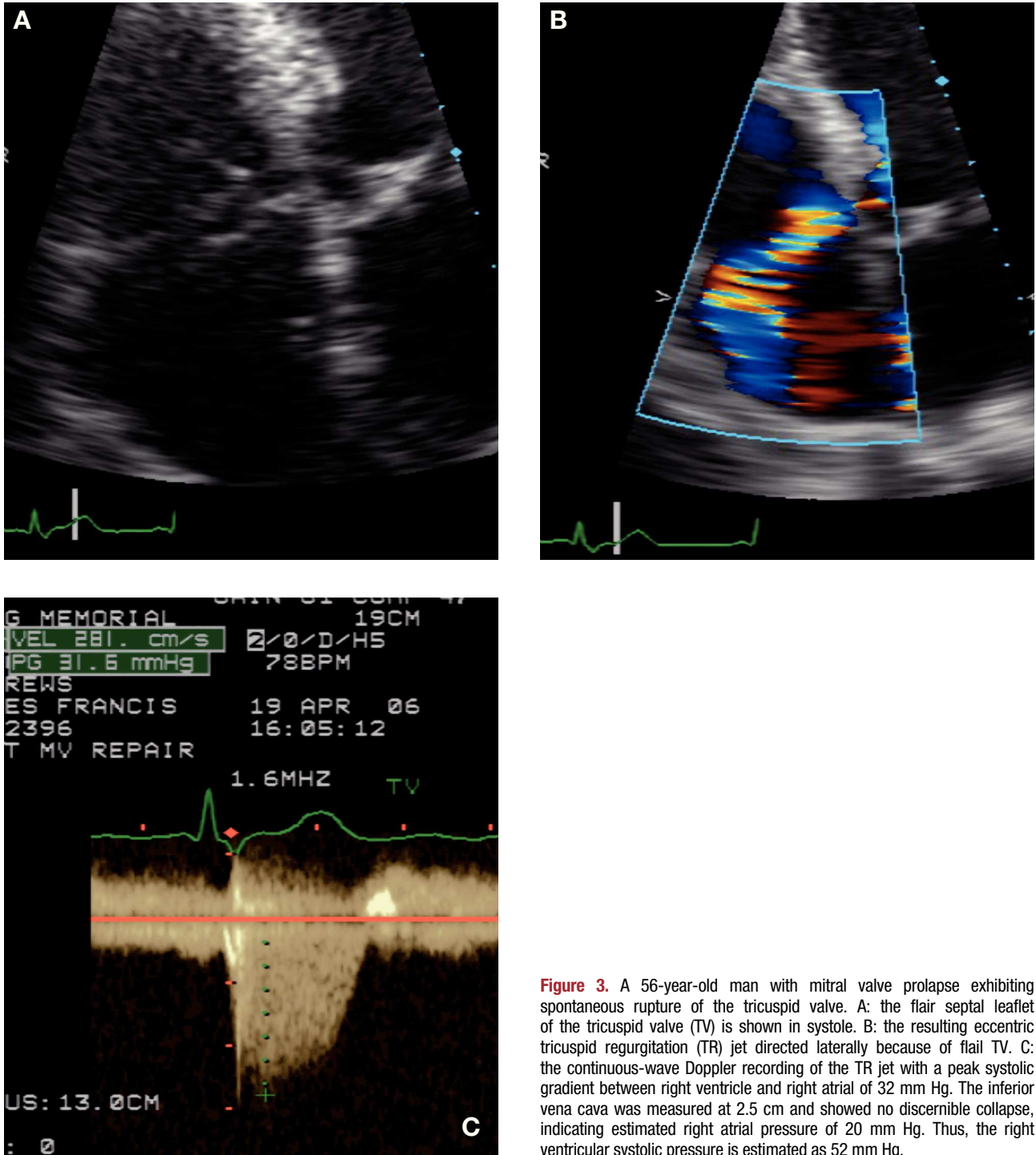


Figure 3. A 56-year-old man with mitral valve prolapse exhibiting spontaneous rupture of the tricuspid valve. A: the flail septal leaflet of the tricuspid valve (TV) is shown in systole. B: the resulting eccentric tricuspid regurgitation (TR) jet directed laterally because of flail TV. C: the continuous-wave Doppler recording of the TR jet with a peak systolic gradient between right ventricle and right atrial of 32 mm Hg. The inferior vena cava was measured at 2.5 cm and showed no discernible collapse, indicating estimated right atrial pressure of 20 mm Hg. Thus, the right ventricular systolic pressure is estimated as 52 mm Hg.

collapse with sniff test. It is important to emphasize that height of TR velocity is not indicative of severity of regurgitation, but rather the degree of right ventricular systolic pressure or pulmonary hypertension.

Transesophageal echocardiography (TEE): transthoracic echocardiography is often of

diagnostic quality because the TV and the right ventricle are closer to the anterior chest wall and several parasternal, apical, and subcostal views are used to image these structures. However, TEE is indicated for better anatomic definitions of the valve lesions or precise measurement of the tricuspid annulus. The assessment of severity of

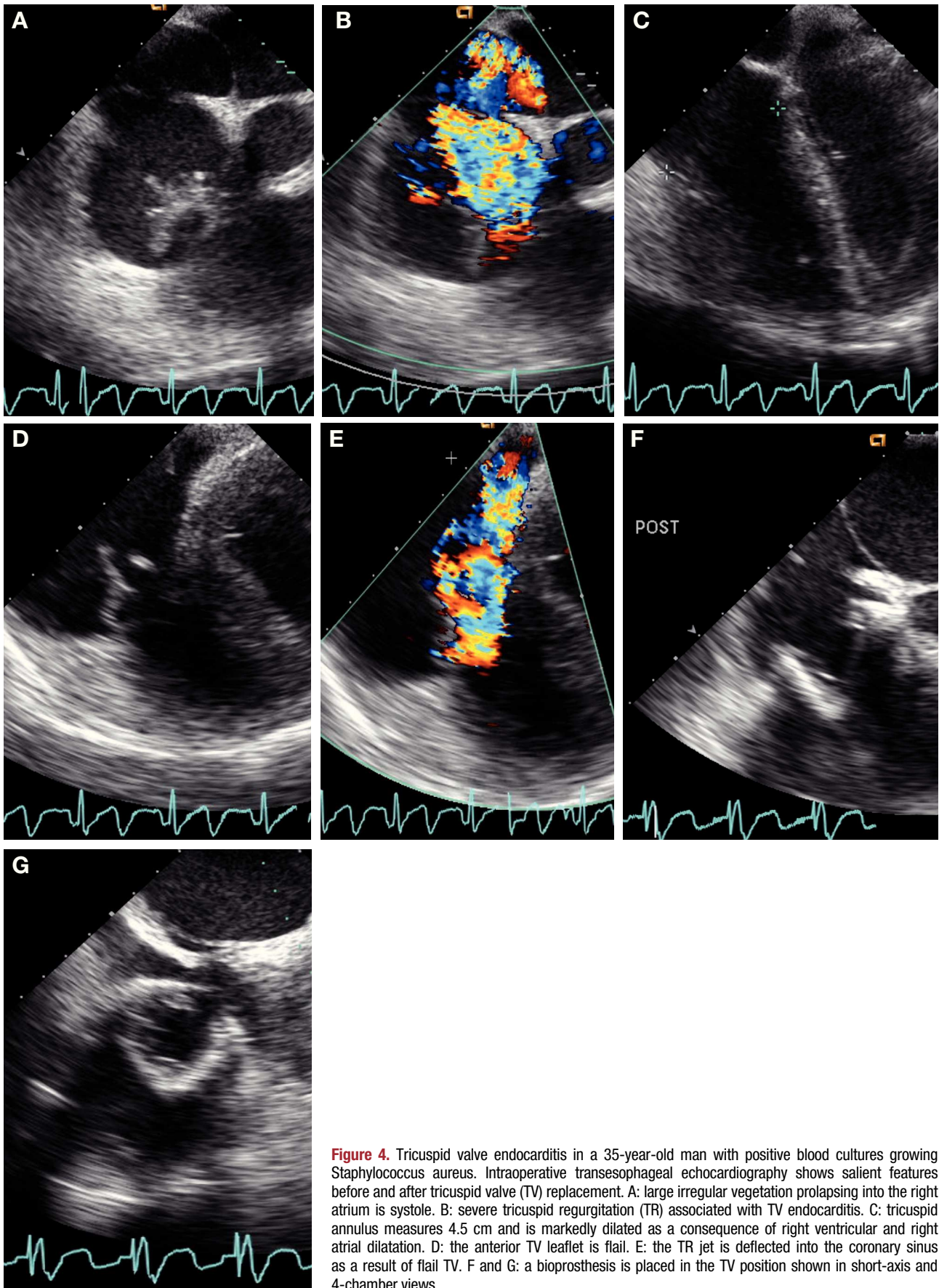


Figure 4. Tricuspid valve endocarditis in a 35-year-old man with positive blood cultures growing *Staphylococcus aureus*. Intraoperative transesophageal echocardiography shows salient features before and after tricuspid valve (TV) replacement. A: large irregular vegetation prolapsing into the right atrium is systole. B: severe tricuspid regurgitation (TR) associated with TV endocarditis. C: tricuspid annulus measures 4.5 cm and is markedly dilated as a consequence of right ventricular and right atrial dilatation. D: the anterior TV leaflet is flail. E: the TR jet is deflected into the coronary sinus as a result of flail TV. F and G: a bioprosthesis is placed in the TV position shown in short-axis and 4-chamber views.

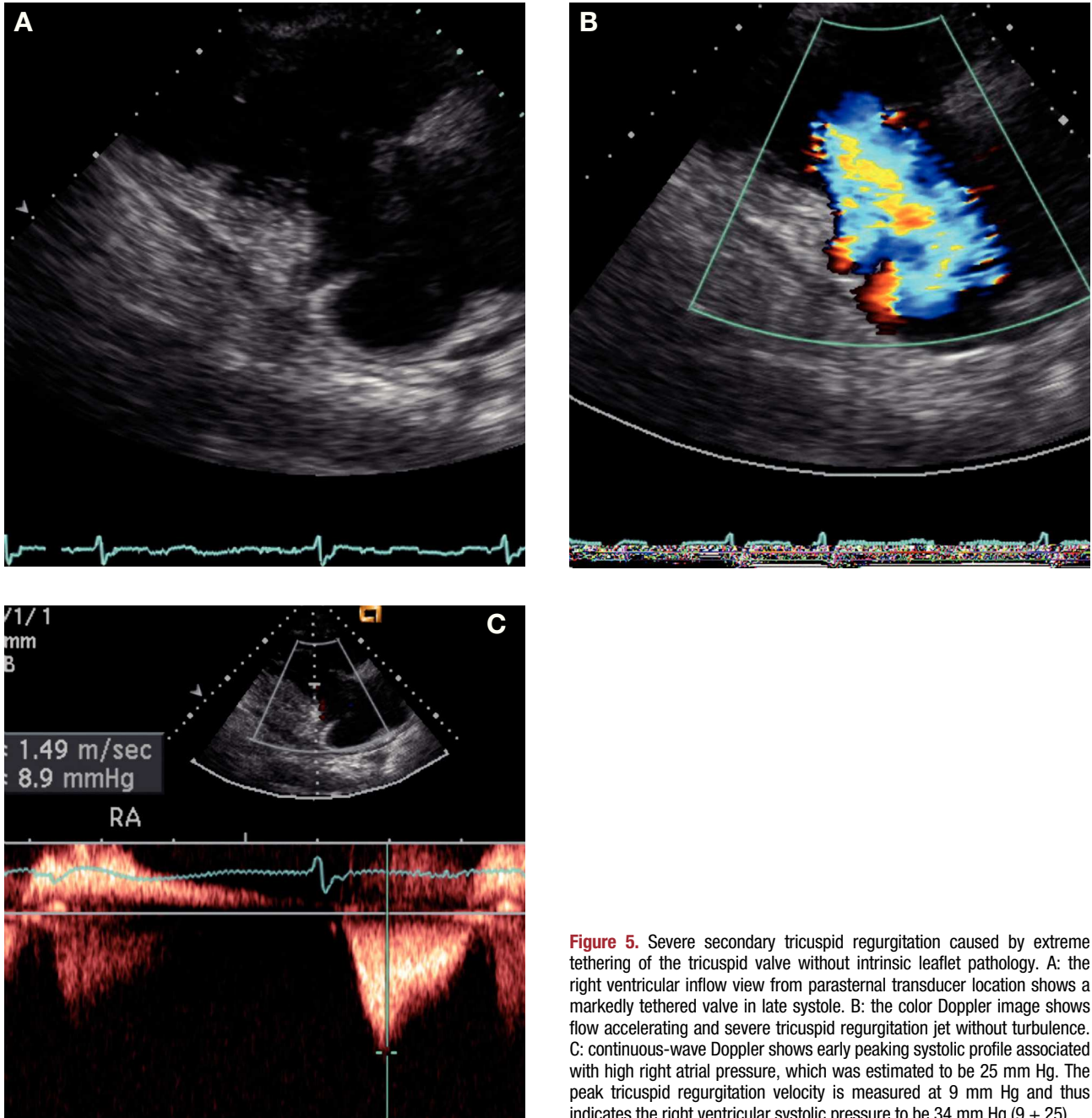


Figure 5. Severe secondary tricuspid regurgitation caused by extreme tethering of the tricuspid valve without intrinsic leaflet pathology. A: the right ventricular inflow view from parasternal transducer location shows a markedly tethered valve in late systole. B: the color Doppler image shows flow accelerating and severe tricuspid regurgitation jet without turbulence. C: continuous-wave Doppler shows early peaking systolic profile associated with high right atrial pressure, which was estimated to be 25 mm Hg. The peak tricuspid regurgitation velocity is measured at 9 mm Hg and thus indicates the right ventricular systolic pressure to be 34 mm Hg (9 + 25).

tricuspid stenosis or TR is generally more accurate with transthoracic echocardiography. This is especially true in the intraoperative setting, where severity of TR may be underestimated as a result of lowered pulmonary vascular resistance from the anesthetic agents. It is therefore erroneous to use the severity of TR in the operating room to decide if a surgical procedure is to be performed on the TV. In the intraoperative setting, TEE is especially

used for measuring the tricuspid annulus diameter. This is done in the midesophageal four-chamber view and a plane perpendicular (90 degrees) to it.

Cardiac catheterization and selective angiography: Prior to the advent of diagnostic echocardiography, cardiac catheterization was used to confirm the presence and severity of tricuspid stenosis. It was recognized that simultaneous recordings of right

atrial and right ventricular diastolic pressures was needed for accurate assessment because the pressure gradients are small and there is considerable respiratory variation in the pressure wave forms. The diagnosis of TR posed a greater challenge, as selective angiography into the right ventricle would often distort the TV. The pressure wave form in the right atrium shows the characteristic prominent systolic V wave with rapid descent only in the most severe cases. Diagnostic cardiac catheterization should rarely, if ever, be undertaken for the diagnosis or quantitation of TV disease alone.

Treatment

The treatment of TV disease must entertain two important questions, namely when to treat and how to treat (Table 2).

When to Treat?

The decision to treat TV disease is based largely on hemodynamic and functional consequences of the diseases as well as coexistence of other associated valvular or congenital lesions. As an isolated lesion, mild or moderate TV disease does not need to be treated. Mild or even moderate TR may be observed using current echo-Doppler techniques in normal subjects. In the absence of structural changes such as annular dilatation or leaflet disruption, such lesions are not known to progress. On the other hand, severe TV disease results in enlargement of right atrium and right ventricle and increase in right atrial and systemic venous pressures. If untreated, right ventricular dysfunction with reduction in cardiac output develop first with exercise and subsequently at rest. This is accentuated by development of atrial fibrillation. In addition, chronic hepatic congestion results in fibrosis and development of cardiac cirrhosis. The liver function tests become increasingly abnormal. Progressive dilatation of right heart chambers brings about progressive annular dilatation, worsening severity of regurgitation. Thus, chronic severe regurgitation often begets more regurgitation. For isolated severe TV disease, intervention should be considered as earliest signs of right ventricular and/or hepatic dysfunction develop.

The rules governing management are different when moderate TV dysfunction is associated with other valvular or myocardial disorders. The timing of intervention is generally dictated by considerations relating to accompanying left heart disease. Approximately 40% of patients exhibit regression of TR following mitral valve surgery, with reduction in pulmonary hypertension. Since it fails to regress in nearly 60% of patients, it is a recommended practice

TABLE 2. Indication for TV Surgery During Mitral and/or Aortic Valve Surgery Intraoperative TEE

Severe TR	TV repair
Mild to moderate TR	
Prior known severe TR	TV repair
No prior severe TR	
Annulus diameter ≥ 40 mm	TV repair
Annulus diameter 35-39 mm	
PASP > 50 mm Hg	TV repair
Annulus diameter < 35 mm	No need for repair

PASP indicates pulmonary artery systolic pressure; TEE, transesophageal echo; TR, tricuspid regurgitation; TV, tricuspid valve.

to treat tricuspid lesion more aggressively during the mitral valve surgery.¹⁷

How to Treat?

Primary or intrinsic TV disease with severe dysfunction nearly always requires surgery, with the possible exception of rheumatic tricuspid stenosis which may be approached by percutaneous balloon valvuloplasty.

Secondary or functional TR offers a wider array of options:

– Medical treatment: TR secondary to pulmonary hypertension may be treated by medical management of underlying etiology, when feasible. Thus, appropriate treatment of myocarditis or depressed left ventricular function may result in amelioration of functional TR. Similarly, improvement in lung function in chronic obstructive lung disease or appropriate control of sleep apnea may improve the associated TR. It is worth emphasizing that functional TR may be dynamic, being load dependent. Intensive medical treatment of heart failure may improve dramatically the severity of TR. This is especially relevant when a patient is undergoing surgery of left heart disease (such as mitral or aortic valve disease) following intensive medical treatment of heart failure, such that the most recent echocardiogram may fail to show significant TR. In this setting even if the TR is mild to moderate, it will require surgical treatment.

– Surgical treatment: Rheumatic tricuspid stenosis is nearly always associated with rheumatic mitral valve disease. Successful mitral and TV repair may be carried out, although long term results are poor. Mitral valve replacement with TV replacement may be considered in patients unwilling to entertain a risk of reoperation. These patients will require

mechanical prosthesis, being in a younger age group.

– Tricuspid regurgitation: since the most commonly observed TR undergoing surgery is functional or secondary to mitral, aortic or ischemic heart disease; the surgical approaches will be considered in some detail. Significant TR is often a marker of adverse outcome.^{18,19} A variety of techniques for valve repair have been used over the years. These fall broadly into 2 categories; suture techniques and annuloplasty techniques.

Suture techniques:

– De Vega purse string repair: since its inception in 1972, this technique has been extensively used long-term with considerable success.²⁰ However, long-term follow-up studies reveal a significantly higher recurrence rate as compared to use of annuloplasty ring or band.⁵ The early results (up to 6 months) are good, such that one would recommend its use in cases where a rapid and sustained fall in pulmonary artery pressure is likely to result following mitral valve surgery. It is a more practical and economical approach in developing countries with high incidence of rheumatic mitral disease being operated on at early age (Table 3).⁵

– Suture plication of posterior leaflet: this approach has been used in some cases with extreme annular dilatation, but generally in combination with annuloplasty.

Annuloplasty techniques:

There is a growing body of evidence to support improved outcome and durability of TV repair using annuloplasty ring. Tant et al reported freedom from recurrent TR in those receiving rings was 82 (5%) at 15 years as compared to 39 (11%) ($P=.0003$) in repairs without use of a ring. They also observed improved long term survival as well as event free survival for those with TV repair with ring. McCarthy et al also reported a higher rate of failed TV repair without use of rings. They observed 30% of patients with De Vega procedure had severe regurgitation at 8 years as compared to none with ring annuloplasty.⁵ A variety of annuloplasty rings and bands have been used:

– Peri-Guard annuloplasty consists of customized semicircular annuloplasty using bovine pericardium. A high rate of early and late recurrence of TR has been reported. This approach is not favored at the present time.

– Carpentier ring devised for the TV introduced more than 30 years ago has been extensively used. This semi-rigid ring has had excellent early and late outcome. Special care has to be taken to avoid injury to the AV node.

TABLE 3. Prevalence of Grade 3 or 4 TR Following Various Annuloplasty Techniques

Technique	1 Month	1 Year	5 Years	8 Years
Carpentier	15.2%	15.5%	17%	17%
Cosgrove	15.3%	18%	18%	N/A
De Vega	13.6%	18%	28%	33%
Peri-Guard	15.4%	20%	32%	37%

TR indicates tricuspid regurgitation.
Modified from McCarthy et al.⁵

– Duran flexible ring has been proposed in order to preserve the normal annular function of dilatation in diastole and reduction in systole. Good early and late outcome has been reported using the flexible ring.

– Annuloplasty bands or incomplete rings are used to avoid risk of AV node injury. A partial ring specially devised with knowledge of 3-dimensional geometry of the TV (MC3 ring) has been introduced with promising early and mid-term outcome.

– Edge to edge annuloplasty technique consisting of stitching together free edges of the tricuspid leaflets to produce a clover shaped valve has been described.^{21,22}

Tricuspid valve replacement: although most studies have reported a better early and long term outcome with valve repair, there are some cases with marked distortion of the annulus and severe leaflet tethering in which valve replacement may be necessary. Generally bioprosthetic valves are preferred, since valve thrombosis and infection following mechanical valve replacement are distinct risks.²³ Some studies have shown no significant difference in long term outcome between tissue and mechanical valves.²⁴⁻²⁶ Residual regurgitation following TV replacement is lower than after valve repair; however, the perioperative midterm survival and event free survival is better with valve repair (Table 4).⁴

The 2006 American College of Cardiology / American Heart Association (ACC/AHA) Guidelines for management of patients with valvular heart disease pertaining to TV and pulmonary valve are summarized in tables 5 and 6.²⁷⁻²⁹

Surgical Treatment of Primary Tricuspid Valve Regurgitation

Rheumatic Valve Disease

The surgical options include valve repair techniques similar to those employed for rheumatic

TABLE 4. Tricuspid Valve Repair Versus Replacement: Midterm Outcomes

Study design	Retrospective analysis, a single center experience
Patient groups	178 with TV repair, 72 with TV replacement (54 bioprosthesis, 18 mechanical)
Type of follow-up	Clinical and echocardiographic
Duration of follow-up	5.2 (4.1) years
In hospital deaths	Repair, 4%; replacement, 22%
Survival	
5 years	Repair, 90 ± 3%; replacement, 63 ± 6%
0 years	Repair, 76 ± 5%; replacement, 55 ± 6%

Modified from: Singh et al.⁴**TABLE 5. 2006 American College of Cardiology/American Heart Association (ACC/AHA) Guidelines for Management of Patients with Valvular Heart Disease. Bonow RO et al²⁷**

Class I	TV repair is beneficial for severe TR in patients with MV disease requiring MV surgery. <i>(Level of evidence: B)</i>
Class IIa	1. TV replacement or annuloplasty is reasonable for severe primary TR when symptomatic. <i>(Level of evidence: C)</i> 2. TV replacement is reasonable for severe TR secondary to diseased/abnormal tricuspid valve leaflets not amenable to annuloplasty or repair. <i>(Level of evidence: C)</i>
Class IIb	Tricuspid annuloplasty may be considered for less-than-severe TR in patients undergoing MV surgery when there is pulmonary hypertension or tricuspid annular dilatation. <i>(Level of evidence: C)</i>
Class III	1. TV replacement or annuloplasty is not indicated in asymptomatic patients with TR whose pulmonary artery systolic pressure is less than 60 mmHg in the presence of a normal MV. <i>(Level of evidence: C)</i> 2. TV replacement or annuloplasty is not indicated in patients with mild primary TR. <i>(Level of evidence: C)</i> ⁸⁰

MV indicates mitral valve; TR, tricuspid regurgitation; TV, tricuspid valve.

mitral valve disease. In rare cases with extreme fibrotic distortion of the valve, TV replacement may need to be considered. In a study of 328 patients followed over a mean 8.7 years, in-hospital mortality was 7.6% and late mortality was 52.1%. Valve repair had a more favorable outcome.³⁰

Ebstein's Anomaly

TV repair may be feasible in milder cases, although the majority requires valve replacement. Good long term outcomes and survival are reported. A study examined outcome of 40 consecutive patients at one center. The valve was repaired in 18 patients, in 12 in association with cavo-pulmonary shunt. Twenty-two underwent replacement, 11 with cavo pulmonary shunt. There were 2 postoperative deaths and 5 late deaths during follow-up of 6.7 (4.8) years. Arrhythmias were the most common late complication.³¹ The experience reported from the Mayo Clinic in 539 patients showed survival at 5, 10, 15, and 20 years of 94%, 90%, 86%, and 76% respectively. Thirty-six percent experienced atrial fibrillation or flutter and 27% had endocarditis.²⁸

Carcinoid Heart Disease

Symptomatic patients with severe TV dysfunction despite treatment with somatostatin analogues generally require valve replacement. Surgical intervention, aside from relief of symptoms, is also credited with improved survival in this lethal disease. Balloon valvuloplasty has been used in rare cases with predominant tricuspid stenosis. This represents a high risk surgical group.²⁹

Infective Endocarditis

Infection of the tricuspid is commonly related to intravenous drug abuse and poses a significant challenge in management. Early cases may undergo successful valve repair with resection of vegetation, focal leaflet resection and annuloplasty. However, the large majority have significant valve destruction and are candidates for valve replacement. The chances of reinfection in drug addicts is considerable and medical follow-up is likely to be sporadic. Hence, tricuspid valvectomy has been utilized with good initial results, since the resulting TR in absence

TABLE 6. 2006 American College of Cardiology/American Heart Association (ACC/AHA) Guidelines for the Management of Patients with Valvular Heart Disease. Bonow RO et al²⁶**Evaluation of Pulmonic Stenosis in Adolescents and Young Adults**

- Class I
1. An ECG is recommended for the initial evaluation of pulmonic stenosis in adolescent and young adult patients, and serially every 5 to 10 years for followup examinations. (*Level of evidence: C*)
 2. Transthoracic Doppler echocardiography is recommended for the initial evaluation of pulmonic stenosis in adolescent and young adult patients, and serially every 5 to 10 years for followup examinations. (*Level of evidence: C*)
 3. Cardiac catheterization is recommended in the adolescent or young adult with pulmonic stenosis for evaluation of the valvular gradient if the Doppler peak jet velocity is greater than 3 meter per second (estimated peak gradient greater than 36 mm Hg) and balloon dilatation can be performed if indicated. (*Level of evidence: C*)
- Class III
- Diagnostic cardiac catheterization is not recommended for the initial diagnostic evaluation of pulmonic stenosis in adolescent and young adult patients. (*Level of evidence: C*)

Indications for Balloon Valvotomy in Pulmonic Stenosis

- Class I
1. Balloon valvotomy is recommended in adolescent and young adult patients with pulmonic stenosis who have exertional dyspnea, angina, syncope, or presyncope and a right ventricle (RV)-to-pulmonary artery peak-to-peak gradient greater than 30 mmHg at catheterization. (*Level of evidence: C*)
 2. Balloon valvotomy is recommended in asymptomatic adolescent and young adult patients with pulmonic stenosis and RV-to-pulmonary artery peak-to-peak gradient greater than 40 mmHg at catheterization. (*Level of evidence: C*)
- Class IIb
- Balloon valvotomy may be reasonable in asymptomatic adolescent and young adult patients with pulmonic stenosis and an RV-to-pulmonary artery peak-to-peak gradient 30 to 39 mmHg at catheterization. (*Level of evidence: C*)
- Class III
- Balloon valvotomy is not recommended in asymptomatic adolescent and young adult patients with pulmonic stenosis and RV-to-pulmonary artery peak-to-peak gradient less than 30 mmHg at catheterization. (*Level of evidence: C*)³¹

Modified from Bonow et al.²⁶

of pulmonary hypertension is hemodynamically well tolerated. However, the long-term results are discouraging. Replacement with bioprosthesis may be preferred despite young age of the patient, owing to lack of reliance on oral anticoagulation therapy in this group of patients.³²

Cleft Tricuspid Valve

Most adult patients presenting with cleft TV have milder pathology and are successfully repaired. Younger patients with extremely malformed valves may require valve replacement.

Iatrogenic Tricuspid Regurgitation

TR associated with pacemaker trauma is generally amenable to valve repair. Rare cases with secondary fibrotic changes may require valve replacement.

PULMONARY VALVE DISEASE

The overwhelming majority of lesions resulting in pulmonary valve disease are either congenital or a consequence of surgical treatment of congenital lesions. The acquired conditions are rare. Generally, disorders affecting right ventricular infundibulum, pulmonary root and artery are considered together with the pulmonary valve. The etiologies of pulmonary valve disease are listed in Table 7.

Clinical Presentation

Symptoms: these may result from reduced cardiac output in advanced cases with right ventricular dysfunction. Dynamic infundibular stenosis in presence of ventricular septal defect may bring about cyanotic spells observed in children with Tetralogy of Fallot.

TABLE 7. Etiology of Pulmonary Valve Disease

Congenital	Pulmonary valve stenosis
	Pulmonary atresia
	Supravalve pulmonary stenosis
	Infundibular pulmonary stenosis
	Idiopathic pulmonary artery dilatation
	Anomalous origin of coronary artery from pulmonary trunk
Acquired	Coronary arteriovenous fistula
	Rheumatic valve disease
	Infective endocarditis
	Carcinoid heart disease
Iatrogenic	Tumors
	Homograft dysfunction following Ross operation
	Homograft reconstruction for total correction of:
	Pulmonary atresia
	Complex form of Tetralogy of Fallot
	Common arterial trunk
	Transposition of great arteries with Pulmonary stenosis
Pulmonary regurgitation following total correction of Tetralogy of Fallot or following balloon valvotomy.	

Physical signs: bedside examination may provide important clues. Pulmonary valve stenosis is associated with characteristic auscultatory findings depending on severity. Mild stenosis is characterized by a systolic ejection click and short early systolic murmur. With progressive severity, the murmur gets louder, longer and peaks later in systole. The ejection click is often more prominent in expiration. This seemingly paradoxical behavior of the pulmonary ejection click is explained by an inspiratory increase in right ventricular end-diastolic pressure, which opens the valve in late diastole and, hence, causes absence of systolic ejection click during inspiratory phase. Thus, ejection click may be absent in the most severe stenosis where right ventricular end-diastolic pressure is consistently above the pulmonary arterial pressures. The behavior of the second heart sound is also of diagnostic importance. In milder cases the pulmonary component of second heart sound (P_2) is delayed, but retains further widening with inspiration. As stenosis increases in severity, the pulmonary component becomes softer and the murmur in the very severe cases spills past aortic component and the pulmonary component is inaudible.

Clinical assessment of pulmonary regurgitation (PR) is often more challenging. A high-pitched diastolic murmur following a prominent P_2 may be evident in patients with PR secondary to pulmonary hypertension. This murmur is often described as

the Graham Steell murmur and may be erroneously interpreted to indicate aortic regurgitation as they both may be heard best along the left sternal border. Mild or even moderate PR may be present without an audible murmur.

Clinical assessment of infundibular pulmonary stenosis (PS) reveals a systolic murmur peaking in late systole and well-preserved, but delayed, P_2 .

Clinical assessment of supravalvular PS often provides diagnostic clues. The murmur is often prolonged through systole and may spill past P_2 . The murmur is audible in axillary region and over the back. It is often soft and may be easily heard after cessation of respiration.

Laboratory Diagnosis

Electrocardiography

Twelve lead ECG provides valuable clues in the diagnosis of pulmonary valve disease. The features of right ventricular hypertrophy and right atrial enlargement are commonly observed. Severe right ventricular hypertrophy and strain often indicate supra-systemic right ventricular pressure.

Chest X-Ray

A routine PA and lateral chest x-ray also yield useful clues. The pulmonary trunk is dilated in

pulmonary valve stenosis. Reduced pulmonary arterial vasculature indicates severe stenosis. The pulmonary trunk is not dilated in infundibular stenosis, or in pulmonary atresia. Signs of right ventricular enlargement may be present.

Echocardiography

The echocardiogram provides diagnostic and quantitative assessment of pulmonary valve stenosis, infundibular PS, and PR. The pulmonary valve morphology shows doming and incomplete opening in presence of pulmonary valve stenosis. Although the valve cusps are normal in infundibular stenosis, a characteristic midsystolic closure and prominent presystolic “a” wave are often diagnostic clues. The pulmonary artery and branches are dilated in pulmonary hypertension, idiopathic pulmonary artery dilatation and severe PR. In rare cases of pulmonary valve endocarditis, a mobile vegetation may be observed. Hypertrophied and dynamic right ventricular infundibulum are characteristic for infundibular stenosis, be it congenital or associated with hypertrophic cardiomyopathy. The spectral Doppler and color-flow Doppler reveal high-velocity turbulent flow in the main pulmonary artery in patients with pulmonary valve stenosis, and a late-peaking, high-velocity flow with turbulence in the right ventricular outflow tract is noted in infundibular PS. Trivial or mild PR are normal findings in most children, as well as adults. However, moderate and severe regurgitation are associated with right ventricular volume overload and subsequent dilatation and dysfunction. The PR velocity waveform provides a unique insight into pressure difference between pulmonary artery and right ventricle during diastole. Because right ventricular diastolic pressure equilibrates with right atrial pressure in absence of tricuspid stenosis, an estimation of pulmonary arterial diastolic pressure is obtained using the end-diastolic velocity of PR and size of the inferior vena cava, which is used to estimate right atrial pressure (Table 6).²⁷

Cardiac Catheterization and Selective Angiography

Diagnostic right-heart catheterization is useful to measure pulmonary artery pressures and pulmonary wedge pressure, and to calculate pulmonary vascular resistance. These are useful to differentiate and quantify precapillary and postcapillary pulmonary arterial hypertension. Although quantification of pulmonary valve stenosis is generally made using echo Doppler methods, catheter-based measurements before and after pulmonary balloon valvotomy are used

to evaluate successful dilatation of the stenotic pulmonary valve. Selective angiography is less useful for diagnostic or therapeutic interventions.

Treatment

Medical Treatment

The only medical treatment is palliative for relief of right heart failure with hepatic congestion and peripheral edema. No patient should get to this stage since there are a number of interventional and surgical options to treatment of pulmonary outflow disorders. Palliative medical treatment in form of beta adrenergic blockers is used for cyanotic spells in Tetralogy of Fallot.

Interventional Treatment

– *Pulmonary balloon valvoplasty*: this procedure is often carried out in childhood even in absence of symptoms. Patients with peak Doppler gradients in excess of 40 mm Hg are generally suitable candidates for percutaneous balloon valvoplasty. The procedure is highly successful in patients with pulmonary valve stenosis, with marked decrease in transvalvular gradient and increase in pulmonary artery pressures.³³ There is also normalization of right ventricular end diastolic pressures and regression of hypertrophy. Sudden reduction in gradient may lead to subvalvular stenosis requiring the use of beta adrenergic blocking agent. This is observed infrequently and only in those with severe pulmonary valve stenosis. The procedure may result in rare complications including perforation, cardiac tamponade or sudden cardiac arrest. Another complication related to use of larger diameter balloons is occurrence of PR.^{34,35} Although initially mild or moderate, this may progress with time and require future interventions.

– *Percutaneous pulmonary valve replacement*. Following the first successful human percutaneous implantation of a catheter based stent valve in pulmonary position by Bonhoeffer in 2000, the first series included 8 patients with surgically repaired congenital pulmonary valve disease.³⁶ A later experience in 59 patients was reported in 2006, using Melody bovine jugular vein valve³⁷ (Medtronic; Minneapolis, Minnesota). More recent experience in 155 patients illustrated the impact of evolving technology and operator learning curve.³⁸ A prospective multicenter clinical trial confirms safety and efficacy of implantation of the Melody transcatheters pulmonary valve in patients with a dysfunctional right ventricular outflow tract conduit.³⁹ This technique has also been used in pulmonary homograft stenosis after Ross operation.

The use of both the percutaneous valve replacement and of placement of stents are promising interventions in experienced hands.

Surgical Treatment

Surgical valvotomy for severe pulmonary valve stenosis is a well established procedure with a considerable track record. Early complication includes subvalvular stenosis, requiring beta adrenergic blocker as treatment of choice. It improves spontaneously as hypertrophy regresses. Additional complication is development of PR, which may progress in severity with late sequelae.

The surgical procedures designed to reconstruct the outflow tract using conduit are commonly used. These have late complications including stenosis of the conduits and development of progressive PR.

REFERENCES

- Shah PM, Raney AA. Tricuspid valve disease. *Curr Probl Cardiol.* 2008;33:47-84.
- Bruce CJ, Connolly HM. Right-sided valve disease deserves a little more respect. *Circulation.* 2009;119:2726-34
- Guenther T, Norbauer C, Mazzitelli D, Busch RB, Tassani-Prell P, Lange R. Tricuspid valve surgery: a thirty-year assessment of early and late outcome. *J Cardiothorac Surg.* 2008;34:402-9.
- Singh SK, Tang GHL, Maganti MD, Armstrong S, Williams WG, David TE, et al. Midterm outcomes of tricuspid valve repair versus replacement for organic tricuspid disease. *Ann Thorac Surg.* 2006;82:1735-41
- McCarthy PM, Bhudia SK, Rajeswaran J, Hoercher KJ, Lytle BW, Cosgrove DM, et al. Tricuspid valve repair: Durability and risk factors for failure. *J Thorac Cardiovasc Surg.* 2004;127:674-85.
- Tei C, Pilgrim JP, Shah PM, Ormiston JA, Wong M. The tricuspid valve annulus: Study of size and motion in normal subjects and in patients with tricuspid regurgitation. *Circulation.* 1982;6:665-71.
- Joudinaud TM, Flecher EM, Duran CM. Functional terminology for the tricuspid valve. *J Heart Valve Dis.* 2006; 15:382-8.
- Waller BF, Moriarty AT, Eble JN, Davey DM, Hawley DA, Pless JE. Etiology of pure tricuspid regurgitation based on annular circumference and leaflet area: Analysis of 45 necropsy patients with clinical and morphologic evidence of pure tricuspid regurgitation. *J Am Coll Cardiol* 1986;7:1063-74.
- Waller BF, Howard J, Fess S. Pathology of tricuspid valve stenosis and pure tricuspid regurgitation - part III. *Clin Cardiol.* 1995;18:225-30.
- Shiran A, Sagie A. Tricuspid regurgitation in mitral valve disease. *J Am Coll Cardiol.* 2009;53:401-8.
- Wooley CF, Fontana ME, Kilman JW, Ryan JM. Tricuspid stenosis: atrial systolic murmur, tricuspid opening snap, and right atrial pressure pulse. *Am J Med.* 1985;78:375-84.
- Tei C, Shah PM, Tanaka H. Phonographic-echographic documentation of systolic honk in tricuspid prolapse. *Am Heart J.* 1982; 103:294-5.
- Tei C, Shah PM, Cherian G, Trim PA, Wong M, Ormiston JA. Echocardiographic evaluation of normal and prolapsed tricuspid valve leaflets. *Am J Cardiol.* 1983; 52:796-800.
- Fuster V, O'Rourke RA, Poole-Wilson P. Tricuspid valve, pulmonary valve and multiple valve disease. *Hurst's The Heart* 2009;13:79;1745-56.
- Rivera JM, Vandervoort PM, Vazquez de Prada JA, Mele D, Karson TH, Morehead A. Which physical factors determine tricuspid regurgitation jet area in the clinical setting? *Am J Cardiol.* 1993; 72:1305-9.
- Zoghbi WA, Enriquez-Sarano M, Foster E, Grayburn PA, Kraft CD, Levine RA et al. Recommendations for evaluation of the severity of native valvular regurgitation with two-dimensional and Doppler echocardiography. A report from the American Society of Echocardiography's Nomenclature and Standards Committee and the Task Force on valvular regurgitation. *J Am Soc Echocardiogr.* 2003;16:777-802.
- Dreyfus GD, Corbi PJ, Chan KM, Bahrami T. Secondary tricuspid regurgitation or dilatation: which should be criteria for surgical repair? *Ann Thorac Surg.* 2005; 79:127-32.
- Skudicky D, Essop MR, Darel P. Efficacy of mitral balloon valvotomy in reducing the severity of associated tricuspid valve regurgitation. *Am J Cardiol.* 1994; 73:209-11.
- Sagie A, Schwammenthal E, Newell JB, Harrell L, Joziatis TB, Weyman AE, et al. Significant tricuspid regurgitation is a marker for adverse outcome in patients undergoing percutaneous balloon valvuloplasty. *J Am Coll Cardiol.* 1994;24:696-702.
- DeVega NF. La anuloplastia selectiva, regulable y permanente. *Rev Esp Cardiol.* 1972;25:555-6.
- Alfieri O, de Bonis M, Lapenna E, Agricola E, Quarti A, Maisano F. The "clover technique" as a novel approach for correction of post-traumatic tricuspid regurgitation. *J Thorac Cardiovasc Surg.* 2003;126:75-9.
- Lai YQ, Meng X, Bai T, Zhang C, Luo Y, Zhang ZG. Edge-to-edge tricuspid valve repair: an adjuvant technique for residual tricuspid regurgitation. *Ann Thorac Surg.* 2006;81:2179-82.
- SK, Tang GHL, Maganti MD, Armstrong S, Williams WG, David TE, et al. Midterm outcomes of tricuspid valve repair versus replacement for organic tricuspid disease. *Ann Thorac Surg.* 2006; 82:1735-41.
- Tanaka M, Ohata T, Fukuda S, Kigawa I, Yamashita Y, Wanibuchi Y. *Ann Thorac Surg.* 2001;71:582-6.
- Ratuatunga CP, Edwards MB, Dore CJ, Taylor KM. *Ann Thorac Surg.* 1998;66:1940-7
- Rizzoli G, Vendramin I, Nesseris G, Bottio T, Guglielmi C, Schiavon L. *Ann Thorac Surg.* 2004;77:1607-14.
- Bonow RO, Carabello BA, Kanu C, de Leon AC Jr, Faxon DP, Freed MD, et al. ACC/AHA 2006 guidelines for the management of patients with valvular heart disease; a report of the American College of Cardiology / American Heart Association Task Force on Practice Guidelines (writing committee to revise the 1998 Guidelines for the management of patients with Valvular Heart Disease): developed in collaboration with the Society of Cardiovascular Anesthesiologists; endorsed by the Society for Cardiovascular Angiography and Interventions and the Society of Thoracic Surgeons. *Circulation* 2006;114:e84-231.
- Brown ML, Dearani JA, Danielson GK, Cetta F, Connolly HM, Warnes CA, et al. Functional status after operation for Ebstein anomaly. *J Am Coll Cardiol.* 2008;6:460-6.
- Moller JE, Pellikka PA, Bernheim AM, Schaff HV, Rubin J, Connolly HM. Prognosis of Carcinoid heart disease analysis of 200 cases over two decades. *Circulation.* 2005;112: 3320-7.
- Bernal JM, Alejandro P, Begona D, Llorca J, Garcia I, Sarralde A. et al. Surgery for rheumatic tricuspid valve disease: A 30-year experience. *J Thorac and Cardiovasc Surg.* 2008;136: 476-81.
- Al-Najashi KS, Balint OH, Oechslin E, Williams WG, Silversides CK. Mid-term outcomes in adults with Ebstein

- anomaly and cavopulmonary shunts. *Ann Thorac Surg.* 2009;88:131-6.
32. Konstantinov IE. Total resection and complete reconstruction of the tricuspid valve in acute infective endocarditis. *J Thorac and Cardiovasc Surg.* 2008;136:531-2.
 33. Werynski P, Rudzinski A, Krol-Jawien W, Kuzma J. Percutaneous balloon valvuloplasty for the treatment of pulmonary valve stenosis in children - a single centre experience. *Kardiologia Polska.* 2009;67:4:369-375.
 34. Harrild DM, Powell AJ, Trang TX, Geva T, Lock JE, Rhodes J, et al. Long-term pulmonary regurgitation following balloon valvuloplasty for pulmonary stenosis. *J Am Coll Cardiol.* 2010;55:1041-7.
 35. Latson LA. Balloon pulmonary valvuloplasty, pulmonary regurgitation, and exercise capacity. *J Am Coll Cardiol.* 2010; 55:1048-9.
 36. Bonhoeffer P, Boudjemline Y, Saliba Z, Hausse AO, Aggoun Y, Bonnet D, et al. Transcatheter implantation of a bovine valve in pulmonary position: a lamb study. *Circulation.* 2000;102:813-6.
 37. Khambadkone S, Coats L, Taylor A, Boudjemline Y, Derrick G, Tsang V, et al. Percutaneous pulmonary valve implantation in humans: results in 59 consecutive patients. *Circulation.* 2005;112:1189-97.
 38. Lurz P, Coats L, Khambadkone S, Nordmeyer J, Boudjemline Y, Schievano A, et al. Percutaneous pulmonary valve implantation: impact of evoking technology and learning curve on clinical outcome. *Circulation.* 2008;117:1964-72.
 39. Zahn EM, Hellenbrand WE, Lock JE, McElhinney DB. Implantation of the Melody transcatheter pulmonary valve in patients with a dysfunctional right ventricular outflow tract conduit. *J Am Coll Cardiol.* 2009;54:1722-9.