

Transseptal Catheterization Using Electrophysiological Landmarks in Ablation Procedures

Asier Subinas, Virginia Montero, José M. Ormaetxe, Jesús D. Martínez-Alday, María F. Arcocha, and José M. Aguirre

Servicio de Cardiología, Hospital de Basurto, Bilbao, Spain

Since the development of radiofrequency catheter ablation for the treatment of atrial fibrillation, electrophysiology laboratories have experienced a significant rise in the number of transseptal catheterization procedures. Traditionally, the procedure requires the presence of an interventional cardiologist who carries out transseptal catheterization following arterial puncture and placement of a reference pigtail catheter in the aortic root.

Use of His bundle and coronary sinus catheters to provide anatomical and electrophysiological landmarks enables transseptal catheterization to be carried out without the need for arterial puncture or intracavity pressure measurement.

We report our experience with transseptal catheterization in an electrophysiology laboratory using only electrophysiological landmarks. The procedure was carried out on 68 occasions and was successful in all patients except one, in whom catheterization could not be performed for anatomical reasons and because the patient had previously received anticoagulation therapy. One other patient developed transient ST elevation, which was probably due to an air embolism.

Key words: *Electrophysiology. Transseptal catheterization. Radiofrequency ablation.*

Punción transeptal mediante referencias electrofisiológicas para procedimientos de ablación

Desde el desarrollo de la ablación con radiofrecuencia para el tratamiento curativo de la fibrilación auricular, los laboratorios de electrofisiología han experimentado un incremento considerable en el número de cateterismos transeptales. Tradicionalmente, el procedimiento requería la intervención de un hemodinamista que procedía a realizar el cateterismo transeptal previa punción arterial y colocación de un catéter *pigtail* de referencia en la raíz aórtica.

Utilizando el catéter del His y el del seno coronario como referencias anatomo-electrofisiológicas se puede llevar a cabo el cateterismo transeptal sin necesidad de realizar punción arterial ni medición de presiones intracavitarias.

Presentamos nuestra experiencia en cateterización transeptal en el laboratorio de electrofisiología utilizando referencias puramente electrofisiológicas. Hemos realizado el procedimiento en 68 ocasiones, con resultado exitoso en todos los casos salvo en uno, en el que la punción no pudo llevarse a cabo por dificultades en el acceso anatómico y porque el paciente se encontraba previamente anticoagulado. Un paciente presentó elevación transitoria del segmento ST, probablemente debida a un embolismo aéreo.

Palabras clave: *Electrofisiología. Cateterismo transeptal. Ablación con radiofrecuencia.*

INTRODUCTION

In recent years, there has been a considerable increase in the number of transseptal catheterizations performed in electrophysiology laboratories. This circumstance is mainly due to the development of pulmonary vein

ablation techniques for the treatment of atrial fibrillation. Given the lack of experience of electrophysiologists in the performance of this procedure, it requires the presence of an interventional cardiologist to carry out the arterial puncture, placement of a catheter in the aortic root and measurement of intracavity pressures.

Over the course of time, there have been a growing number of electrophysiologists who perform transseptal catheterizations, using a reference catheter placed in the aortic root to mark its location in preparation for transseptal puncture.

Correspondence: Dr. A. Subinas.
Jon de Arróspide, 26, 7.º C. 48014 Bilbao. Vizcaya. España.
E-mail: al.subinas@gmail.com

Received December 15, 2005.
Accepted for publication June 14, 2006.

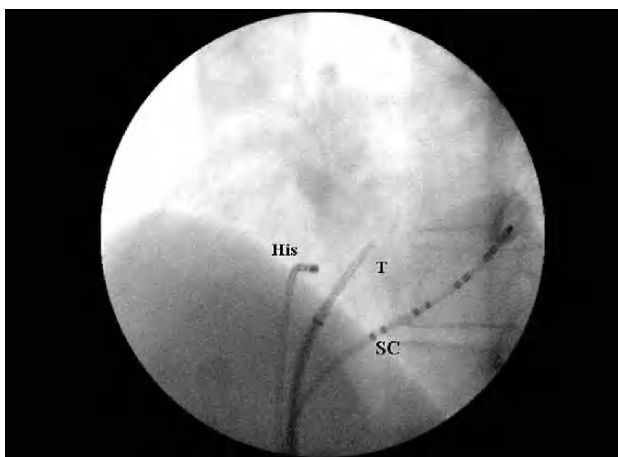


Figure 1. Catheters in left anterior oblique projection. The tip of the system is located to the right of the His bundle catheter, that is, posterior to and somewhat lower than this device, at a variable height between the catheter and the coronary sinus ostium. SC indicates coronary artery catheter; T, transseptal catheterization system.

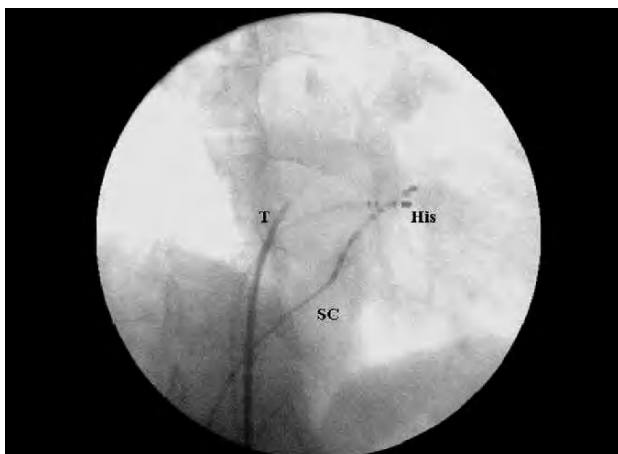


Figure 2. Catheters in right anterior oblique projection (30°). The tip of the system is situated a third of the way between the His bundle catheter and the right margin of the cardiac silhouette, parallel to the coronary sinus catheter, thus ensuring that it is situated posteriorly with respect to the aortic root. In left anterior oblique projection, the tip of the system is situated somewhat higher than or at the same height as the His bundle catheter. SC indicates coronary sinus catheter; T, transseptal catheterization system.

We perform transseptal catheterization using one catheter inserted in the coronary sinus and another in the His bundle, which enable us to identify the anatomical structures necessary to ensure an easy and safe transseptal puncture, with a high success rate.

Here, we describe the different phases of the procedure in detail and report the results obtained with this technique in our hospital.

METHODS

The transseptal catheterization system consists of a Brockenbrough needle (St Jude BRK or BRK1), a dilator and an introducer (Jude SL1, 8 French).

We use the coronary sinus and His bundle catheters as fundamental anatomical and electrophysiological landmarks. The entry site of the coronary sinus catheter (coronary sinus ostium) indicates the inferior margin of the interatrial septum. The body of the catheter inserted into the coronary sinus establishes the orientation of the mitral annulus and marks the site of the lateral and posterior aspects of left atrium. The catheter in the His bundle indicates the superior margin of the interatrial septum and is juxtaposed to the noncoronary leaflet of the aortic valve, thus enabling the identification of the aortic root without having to place a reference catheter in it.

First, the catheterization system, consisting of the dilator, introducer, and Brockenbrough needle, is set up externally in order to observe the correct adjustment of the entire system and improve the adaptation of the guiding catheter.

Subsequently, in anteroposterior projection, following introduction of a guide wire into superior vena cava, the dilator and introducer are advanced until they reach this vessel. Once the guide wire is withdrawn, the Brockenbrough needle is introduced up to a point at which it does not yet protrude through the tip of the system. Then, in left anterior oblique projection, and at a variable angle of inclination (45° to 60°), in such a way that the catheter in the His bundle is perpendicular in the fluoroscopic image, the needle is rotated in a clockwise direction to set the arrow on the external part of the needle at 4 o'clock. Subsequently, it is lowered from the superior vena cava to right atrium until the region of the fossa ovalis is reached, after a skip to the right in the fluoroscopy that is perceived only on occasion. In this region, we observe that the tip of the system is located to the right of the His bundle catheter, that is, posterior to and somewhat lower than this device, at a variable height between the catheter and the coronary sinus ostium (Figure 1). Prior to transseptal puncture, an image in 30° left anterior oblique projection should be visualized to confirm that the tip of the system is located to the left (and thus, posterior to) the catheter that records His bundle activation. This is normally situated a third of the way between the His bundle catheter and the right margin of the cardiac silhouette (the lateral aspect of right atrium), and parallel to the coronary sinus catheter. Thus, we ensure that it is situated posteriorly with respect to the aortic root. In right anterior oblique projection, the tip of the system is usually situated somewhat higher than or at the same height as the His bundle catheter (Figure 2).

If it falls below the fossa ovalis, the procedure should be reinitiated. The guide wire is reintroduced into superior vena cava and the system (introducer and dilator) is again

inserted. The attempt should never be made to advance the system without the guide wire because of the risk of perforation with the dilator tip.

Once we consider that the system has reached the fossa ovalis, again in left anterior oblique projection, a contrast medium is injected to label the wall. The labeling of the fossa ovalis reveals the characteristic “tenting” of the membrane, forming a triangle, the vertex of which is located to the right in the fluoroscopic image (Figure 3). Then, we advance the Brockenbrough needle, aspirate blood, which should be red, given its arterial origin, and inject a contrast medium to ensure that we have reached the left atrium, before advancing the rest of the system. The guide wire is often introduced into a pulmonary vein. At this point, systemic heparinization and heparinization of the introducer is carried out. For atrial fibrillation ablation, we place two catheters in left atrium, an ablation catheter and a circular catheter to map the pulmonary veins. This is normally done via transseptal puncture. For this purpose, we withdraw the system, leaving only the guide wire passing through the transseptal puncture hole. Using this landmark, we introduce the ablation catheter, once again advancing the system, through which we place the catheter for pulmonary vein mapping.

On some occasions, it is not possible to pass the ablation catheter through a single transseptal puncture hole. This makes it necessary to perform a second needle puncture, using the guide wire of the initial puncture as a landmark. In case of recurrence of atrial fibrillation following pulmonary vein ablation, we normally perform double transseptal puncture from the outset, and always employ this technique when the manipulation of the catheters was difficult during the first procedure.

The major risks associated with transseptal catheterization is an undetected puncture of left or right atrial wall or the coronary sinus and penetration into the aortic root, or pulmonary artery.

RESULTS

At our center, we have performed a total of 68 transseptal procedures (for pulmonary vein isolation in 41 patients, in 14 of whom the procedure was repeated, including two patients with left-sided accessory pathway, and 11 patients with left atrial tachycardia). Of all the atrial fibrillations treated by ablation, 7% were permanent, 19% were persistent and 74% were paroxysmal, with a mean atrial size of 41 (3) mm.

The procedure was successfully completed in all but one case, in which we decided not to perform puncture because it proved to be complicated and the patient had previously received anticoagulation therapy.

One patient developed ST segment elevation in inferior electrocardiographic leads, associated with mild precordial tightness. This occurred shortly after gaining access to left atrium and ceased spontaneously after three to four minutes. We suspect that it was provoked by an air

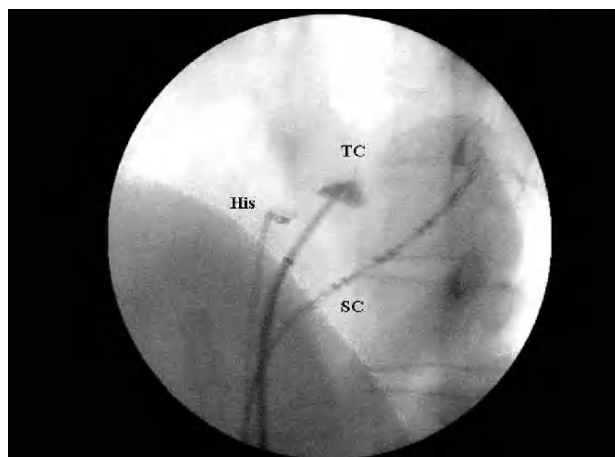


Figure 3. Labeling of the fossa ovalis in left anterior oblique projection. The labeling of the fossa ovalis reveals the characteristic “tenting” of the membrane, forming a triangle, the vertex of which is located to the right in the fluoroscopic image. SC indicates coronary sinus catheter; TC, “tenting” image.

embolism in right coronary artery due to introduction of air into the system during manipulation of the catheters. There were no other complications.

DISCUSSION

The procedure we employ has been utilized and described in the medical literature by a number of authors. de Ponti et al¹ performed 453 procedures in 411 consecutive patients over a four-year period, using a catheter in the His bundle and another in coronary sinus as landmarks.¹ Later, González et al² carried out a total of 108 procedures with the same technique, with an additional catheter in right atrial appendage, the distal and proximal ends of which locate the right atrial roof and posterior right atrial wall (intercaval region), respectively, while other authors consider it sufficient to use the body of the coronary sinus catheter in its descent as a landmark for locating posterior right atrial wall.¹

In the series studied by de Ponti et al,¹ there were no clinically relevant complications, although transseptal puncture had to be aborted in five cases because the safety of the procedure in its entirety did not appear to be guaranteed; in fact, the left atrial free wall was perforated by the Brockenbrough needle in two of the five patients, although this incident did not result in complications or sequelae.² According to a number of authors, needle puncture, when carried out as an isolated procedure, is not associated with significant complications.³⁻⁵ González et al² performed transseptal puncture successfully in all their patients, avoiding perforation of left atrium or aortic root in every case.

Transesophageal or intracardiac echocardiography can be employed to guide transseptal catheterization,⁶⁻⁹

although, at the present time, there is data to indicate that the use of adjuvant echocardiographic instrumentation is associated with a lower incidence of complications.

In conclusion, transseptal catheterization using only electrophysiological landmarks, with one catheter in the coronary sinus, and another in the His bundle, is a simple and safe procedure. Its performance is increasingly widespread in electrophysiology laboratories, where the performance of transseptal puncture by electrophysiologists is yielding satisfactory results with high rates of success.

REFERENCES

1. de Ponti R, Zardini M, Storti C, Longobardi M, Salerno-Uriarte JA. Transseptal catheterization for radiofrequency catheter ablation of cardiac arrhythmias. *Eur Heart J*. 1998;19:943-50.
2. González DM, Otomo K, Shah N, Arruda SM, Beckmann JK, Lazzara R, et al. Transseptal left heart catheterization for cardiac ablation procedures. *J Interv Card Electrophysiol*. 2001;5:89-95.
3. Clungston R, Lau FYK, Ruiz C. Transseptal catheterization update 1992. *Cathet Cardiovasc Diagn*. 1992;26:266-74.
4. Roelke M, Smith AJC, Palacios IF. The technique and safety of transseptal left Heart catheterization: the Massachussets general hospital experience with 1,279 procedures. *Cathet Cardiovasc Diagn*. 1994;32:332-9.
5. De Ponti R, Cappato R, Curnis A, Della Bella P, Padeletti L, Raviele A, et al. Trans-septal catheterization in the electrophysiology laboratory. Data from a Multicenter Survey Spanning 12 years. *J Am Coll Cardiol*. 2006;47:1037-42.
6. Daoud EG. Transseptal catheterization. *Heart Rhythm*. 2005;2:212-4.
7. Daoud EG, Klabfleisch SJ, Hummel JD. Intracardiac echocardiography to guide transseptal left heart catheterization for radiofrequency catheter ablation. *J Cardiovasc Electrophysiol*. 1999;10:358-63.
8. Szili-Torok T, Kimman G, Theuns D, Res J, Roelandt JR, Jordaens LJ. Transseptal left heart catheterization guided by intracardiac echocardiography. *Heart*. 2001;86:E11.
9. Cooper JM, Epstein LM. Use of intracardiac echocardiography to guide ablation of atrial fibrillation. *Circulation*. 2001;104:3010-3.