

Transapical Aortic Valve Implantation. Initial Experience

Enrique Rodríguez,^a Luis Maroto,^a Javier Cobiella,^a Jacobo Silva,^a Camino Bañuelos,^b Rosana Hernández-Antolín,^b José L. Zamorano,^b and Fernando Ginestal^c

^aServicio de Cirugía Cardíaca, Hospital Clínico San Carlos, Madrid. Spain.

^bServicio de Cardiología, Hospital Clínico San Carlos, Madrid. Spain.

^cServicio de Anestesiología, Hospital Clínico San Carlos, Madrid. Spain.

We report our initial experience with transapical aortic valve implantation. All 6 of our patients were octogenarians, all had significant associated comorbid conditions and, according to the logistic EuroSCORE, their mortality was expected to be 22%. All procedures were performed successfully and there were no intraoperative or postoperative complications. Five patients were discharged between postoperative days 5 and 7 with normally functioning prostheses.

Key words: *Transapical. Aortic stenosis. Octogenarians.*

Implantación de prótesis aórticas vía transapical. Experiencia inicial

Presentamos nuestra experiencia inicial en la implantación de prótesis aórticas vía transapical. Se trata de 6 pacientes octogenarios, con morbilidad asociada importante y una mortalidad esperada por EuroSCORE logístico medio del 22%. Los procedimientos se realizaron con éxito, sin complicaciones operatorias ni postoperatorias. Cinco pacientes fueron dados de alta entre el quinto y el séptimo día postoperatorio con prótesis normofuncionantes.

Palabras clave: *Transapical. Estenosis aórtica. Octogenarios.*

INTRODUCCIÓN

The most common cardiac valve condition in octogenarians is aortic stenosis. When this is severe and symptomatic, the treatment of choice is aortic valve replacement with extracorporeal circulation (ECC).¹⁻³ The increase in life expectancy in Spain has resulted in an increasing number of elderly individuals who require surgery. These are often patients with significant comorbidities (renal failure, respiratory failure, ventricular dysfunction, pulmonary hypertension, peripheral artery disease, etc) with a high expected mortality according to the different risk models.^{4,5}

In recent years, a number of less invasive techniques have been developed for aortic valve replacement

in this subgroup of patients in an attempt to reduce the mortality and morbidity associated with conventional surgery.⁶ We present our initial experience with aortic bioprosthesis implantation by a transapical approach.

METHODS

The inclusion criteria were based on the protocol of the Leipzig group: severe symptomatic aortic stenosis, age >79 years, logistic EuroSCORE >14%, aortic annulus <25 mm (as measured by transthoracic echocardiography), no other significant valve disease, undilated aortic root, and symmetric calcium distribution in the annulus.

The prosthesis used was the trileaflet valve of bovine pericardium mounted on a stainless steel balloon-expandable stent (Edwards Sapiens THV, Edwards Lifesciences, California, United States). These are available in 2 sizes, 23 mm (for annuli measuring less than 22 mm) and 26 mm (for those measuring 22-24 mm). The prosthesis was mounted on the balloon stent in fully sterile conditions immediately prior to implantation.

Correspondence: Dr. J. Cobiella Carnicer.
Secretaría del Servicio de Cirugía Cardíaca. Hospital Clínico San Carlos.
Prof. Martín Lagos, s/n. 28040 Madrid. España.
E-mail: jcobiella@hotmail.com

Received July 11, 2008.

Accepted for publication November 25, 2008.

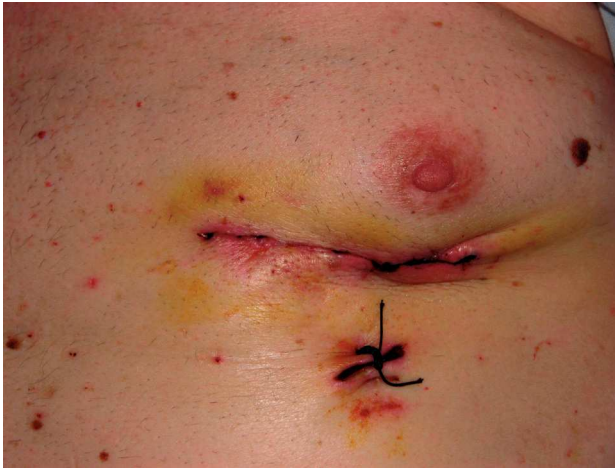

Figure 1. Skin incision of the anterolateral thoracotomy.

The procedure was performed in the operating theater, with fluoroscopic and 3-dimensional transesophageal echocardiographic guidance. With the patient under general anesthetic, the apex of the left ventricle was approached via an anterolateral minithoracotomy (Figure 1). With the patient in the theater, the exact site of incision was located using transthoracic echocardiography. After opening the pericardium, the surgeon performed a purse-string suture in the apex through which the different catheters were subsequently introduced. After advancing the guidewire to the abdominal aorta, aortic valvuloplasty was done with conventional balloon procedure through a 14 Fr introducer. Subsequently, the introducer was changed for a 33 Fr one, through which the system for implantation of the aortic bioprosthesis (Ascendra) was introduced. Both the valvuloplasty and implantation were done in ventricular tachycardia induced by epicardial pacing at 160-200 beats/min. If moderate or severe aortic valve regurgitation was observed after implantation, redilatation was done before withdrawing the device. After confirming the function and position of the prosthesis (Figure 2), the device was withdrawn and closed in standard fashion leaving a chest drainage tube in the pleural cavity. The bioprosthesis only required antiaggregant prophylaxis with aspirin.

RESULTS

The procedure was performed in 6 patients—66.6% of whom were men (mean age, 74.5 years)—with a mean EuroSCORE of 22.68%. Three patients had severe respiratory failure, 2 of whom required home oxygen therapy; 3 patients had peripheral artery disease, 1 with a 4 cm aneurysm in the abdominal aorta under observation, and 1 had been treated with a axillobifemoral bypass graft; 1 patient had diabetes

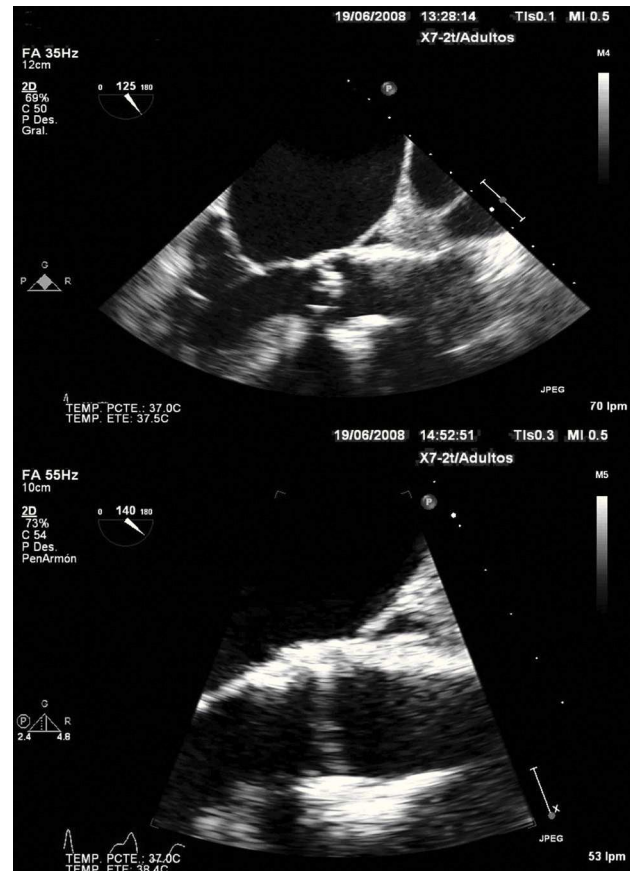


Figure 2. Echocardiographic images from patient 2. Top: prior to prosthesis implantation. Bottom: after implantation.

and 3 had chronic renal failure; 2 patients had permanent atrial fibrillation; and 4 had ischemic heart disease, 1 of whom had undergone an operation and 4 had undergone percutaneous transluminal coronary angioplasty plus stenting. All patients had resting dyspnea (NYHA III) except for 1 who had repeated syncope. In the transthoracic echocardiography, all patients had severe calcified aortic stenosis and 5 had moderate pulmonary hypertension. The catheterization study did not reveal any significant lesions. Three patients received a 26 mm prosthesis and a further 3 received a 23 mm one. All were extubated between 5 and 8 h after the operation. Three patients were released to the ward after 24 h, 2 after 72 h due to exacerbation of renal failure although both responded well to medical treatment, and 1 patient remained in the intensive care unit for 20 days because of heart failure that required vasoactive drugs and diuretics. All patients were discharged between 5 and 6 days after the operation except for 1 who was discharged after 40 days. After 1 month, 6 patients were in functional class I.

The perioperative results are shown in Table 1. The results of the preoperative and postoperative echocardiography are shown in Table 2.

TABLE 1. Perioperative Outcomes

	Patient 1	Patient 2	Patient 3	Patient 4	Patient 5	Patient 6
Aortic annulus by TEE, mm	23	23	22	18	18	18
Prosthesis size, mm	26	26	26	23	23	23
Positioning	Optimum	Optimum	Optimum	Optimum	Optimum	Optimum
Quantity of contrast, mL	234	265	115	178	168	260
Fluoroscopy, min	23	18	18	12	12	16
Redilatation	No	No	No	No	No	No
Duration of surgery, min	110	100	80	80	63	80
Mean TAoVG, mm Hg	5	7	4	6	4	5
V _{max} , m/s	1.9	2	1.5	1.9	1.4	1.7
AR	Insignificant	Insignificant	Insignificant	Insignificant	Insignificant	Insignificant

AR indicates aortic regurgitation; TAoVG, transaortic valve gradient; TEE, transesophageal echocardiography; V_{max}, maximum velocity.

TABLE 2. Echocardiographic Results in Preoperative Period and at 1 Month After Surgery

	Patient 1	Patient 2	Patient 3	Patient 4	Patient 5	Patient 6
Preoperative						
Mean TAoVG, mm Hg	85	61	29	52	43	49
Area, cm ²	0.4	0.5	0.5	0.5	0.4	0.4
EF, %	65	62	40	45	64	48
AR	Mild	Mild	No	Mild	No	Moderate
At 1 month						
Mean TAoVG, mm Hg	6	9	8	6	8	11
Area, cm ²	1.8	2.1	2.5	1.7	1.5	1.1
EF, %	65	60	45	42	68	50
AR	Mild	Mild	Mild	Insignificant	Mild	Mild

AR indicates aortic regurgitation; EF, ejection fraction; TAoVG, transaortic valve gradient.

DISCUSSION

Implantation of aortic prostheses by minimally invasive techniques has been developed in response to the progressive increase in the number of elderly patients who often have many comorbid conditions and who therefore have a high surgical risk. The objective is to be able to maintain the excellent long-term results of conventional surgery while decreasing in-hospital mortality and morbidity by avoiding medial sternotomy and ECC.

Implantation of aortic valves without ECC using catheters in humans started 6 years ago and, currently, there are 2 devices under clinical investigation: The Edwards Sapiens bioprosthesis (Edwards Lifesciences Inc, California, United States) and the CoreValve bioprosthesis (Core Valve Inc, California, United States), which comprises 3 leaflets of porcine aortic valve mounted in a nitinol inflatable stent. The transfemoral approach was the first to be used and, currently, more than 900 prostheses have been implanted using this technique.⁷ The transapical approach offers a series of advantages in that it is independent of the vascular tree anatomy, offers an antegrade and more direct approach (less and simpler manipulation is required because the valve is

only a few centimeters away), and is not limited by the size of the introducer (it is easier to use a bigger prosthesis to reduce perivalvular leaks). Currently, smaller prostheses are in phases of development to allow implantation in annuli of less than 25 mm.

More than 300 patients have been treated with this technique,^{8,9} and one of the groups with the most extensive experience is that of the Herzzentrum in Leipzig, Germany. This group has published a series of 30 consecutive patients with a mean age of 82 years and a mean logistic EuroSCORE of 27%. The procedure was successful in 29 patients. In only 1 case was it necessary to resort to a medial sternotomy due to poor positioning of the prosthesis. Only 2 patients had moderate (grade II-IV) aortic valve regurgitation and the mean postoperative gradient was 7.5 mm Hg. No patients experienced perioperative myocardial infarctions or cerebrovascular accidents. Three in-hospital deaths were reported (10%). The low incidence of neurologic complications found is probably due to the fact that ECC is not necessary as the procedure uses an antegrade approach with limited manipulation of the catheters in the ascending aorta and aortic arch.

The ideal environment for performing the procedure is a hybrid operating theater that combines

the surgical environment of an operating theater (sterility, anesthesia, availability of ECC) with the flexibility of a catheterization laboratory (high-quality imaging, immediate access to percutaneous procedures...). In any case, use of these techniques requires an open mind in a multidisciplinary setting as success can only be attained with close cooperation between cardiologists (catheterization and echocardiography specialists), heart surgeons, and anesthesiologists.

Our limited experience points only to the feasibility of the technique. We consider this surgery in patients at high surgical risk, not in patients not eligible for surgery with a life expectancy of less than 1 year. The surgical risk in this subgroup of patients is not measured only with the EuroSCORE, and it is important to consider risk factors that are very common in these patients and that are not included in these scores, such as porcelain aorta, prior coronary artery surgery bypass surgery, hepatic disease, etc.

Experience is still limited, but the preliminary results are promising. Implantation of aortic bioprosthesis using the transapical approach is a simple and reproducible technique, with excellent short-term hemodynamic outcomes. The medium- and long-term outcomes, the durability of the prosthesis, and the incidence of endocarditis and thromboembolism have yet to be established. More patients are needed and, above all, randomized studies to provide an answer to these questions. The randomized multicenter PARTNER study is currently recruiting patients. This study will include high-risk patients with severe symptomatic stenosis and compare medical treatment, conventional aortic valve replacement, and valve replacement using the transfemoral and transapical approach. The aim is to recruit 1040 patients and the primary outcome measure is mortality at 12 months.

Technology progresses quickly, and we will soon have smaller, more manageable devices that are easier to implant. The new imaging techniques

will help us better define the correct position of the prosthesis, and these techniques might be combined with mapping devices that allow almost automatic implantation. This is a vision for the future, but currently, we should not forget that aortic valve replacement with ECC remains the standard treatment for severe symptomatic aortic valve stenosis.

REFERENCES

1. Bonow RO, Carabello BA, Chatterjee K. ACC/AHA 2006 Guidelines for the management of patients with valvular heart disease: Executive summary. *Circulation*. 2006;114:450-527.
2. Banbury MK, Cosgrove DM 3rd, Thomas JD, Blackstone EH, Rajeswaran J, Okies JE, et al. Hemodynamic stability during 17 years of the Carpentier-Edwards aortic pericardial bioprosthesis. *Ann Thorac Surg*. 2002;73:1460-5.
3. Chukwumeka A, Borger MA, Ivanov J, Armstrong S, Feindel CM, David TE. Valve surgery in octogenarians: a safe option with good medium-term results. *J Heart Valve Dis*. 2006;15:191-6.
4. Kolh P, Kerzmann A, Honore C, Comte L, Limet R. Aortic valve surgery in octogenarians: Predictive factors for operative and long-term results. *Eur J Cardiothorac Surg*. 2007;31:600-6.
5. Varadarajan P, Kapoor N, Bansal RC, Pai RG. Clinical profile and natural history of 453 nonsurgically managed patients with severe aortic stenosis. *Ann Thorac Surg*. 2006;82:2111-5.
6. Walther T, Dewey T, Wimmer-Greinecker G, Doss M, Hambrecht R, Schuler G, et al. Trans-apical approach for sutureless stent-fixed aortic valve implantation: Experimental results. *Eur J Cardiothorac Surg*. 2006;29:703-8.
7. Cribier A, Eltchaninoff H, Tron C, Bauer F, Agatiello C, Sebah L, et al. Early experience with percutaneous transcatheter implantation of heart valve prosthesis for the treatment of end-stage inoperable patients with calcific aortic stenosis. *J Am Coll Cardiol*. 2004;43:698-703.
8. Walther T, Simon P, Dewey T, Wimmer-Greinecker G, Falk V, Kasimir MT, et al. Transapical Minimally Invasive Aortic Valve Implantation: Multicenter Experience. *Circulation*. 2007;116:I240-5.
9. Svensson LG, Dewey T, Kapadia S, Roselli EE, Stewart A, Williams M, et al. United States Feasibility Study of Transcatheter Insertion of a Stented Aortic Valve by the Left Ventricular Apex. *Ann Thorac Surg*. 2008;86:46-55.