

latest-generation micro-TEE probes might represent a very valid alternative not only for LAAO but also for other percutaneous structural heart interventions and could be an option in patients without intubation or general anesthesia, in particular in elderly patients or those with severe comorbidities. Additional experience will be necessary to confirm that high quality imaging is also observed in a larger sample of patients.

Gustavo Jiménez Brítez,* Laura Sanchis, Ander Regueiro, Manel Sabate, Marta Sitges, and Xavier Freixa

Instituto Cardiovascular, Hospital Clínic de Barcelona, Institut d'Investigacions Biomèdiques August Pi i Sunyer (IDIBAPS), Barcelona, Spain

* Corresponding author:

E-mail address: freixa@clinic.ub.es (G. Jiménez Brítez).

Available online 23 June 2018

REFERENCES

1. Wunderlich NC, Beigel R, Swaans MJ, Ho SY, Siegel RG. Percutaneous interventions for left atrial appendage exclusion: options assessment, and imaging using 2D and 3D echocardiography. *JACC Cardiovasc Imaging*. 2015;8:472–488.
2. Zangrillo A, Mazzone P, Votta CD, Villari N, Della Bella P, Monaco F. Prolonged transesophageal echocardiography during percutaneous closure of the left atrial appendage without general anesthesia: the utility of the Janus Mask. *Can J Anesth*. 2016;63:962–965.
3. Barreiro-Pérez M, Li CH, Mesa D, Fernandez-Golfin C, López-Fernández T, Pérez de Isla L. Selection of the Best of 2017 in Cardiac Imaging and Structural Interventionism. *Rev Esp Cardiol*. 2018;71:125–126.
4. Toole BJ, Slenick TC, Kreeger J. The Miniaturized multiplane Micro-Transesophageal echocardiography: A comparative evaluation of its accuracy and image quality. *J Am Soc Echocardiogr*. 2015;28:802–807.
5. Nijenhuis VJ, Alipour A, Wunderlich NC, et al. Feasibility of multiplane microtransesophageal echocardiographic guidance in structural heart disease transcatheter interventions in adults. *Neth Heart J*. 2017;25:669–674.
6. Freixa X, Martín V. Cierre percutáneo de orejuela izquierda. *Rev Esp Cardiol*. 2013;66:919–922.

<https://doi.org/10.1016/j.rec.2018.05.016>

1885-5857/

© 2018 Sociedad Española de Cardiología. Published by Elsevier España, S.L.U. All rights reserved.

Three-dimensional Image Fusion of Precatheter CT and MRI Facilitates Stent Implantation in Congenital Heart Defects



La fusión de imágenes tridimensionales por TAC y RM antes del cateterismo facilita el implante de stent en defectos cardiacos congénitos

To the Editor,

Advances in 3-dimensional (3D) image fusion software have enabled easy application of preintervention imaging, including computed tomography (CT) and magnetic resonance imaging (MRI) scans, to create a reliable roadmap for swift manipulation through complex cardiac anatomy.^{1,2} In an article published in *Revista Española de Cardiología*, Sandoval et al.³ presented an elegant case report of image fusion of a CT-derived 3D roadmap for aortic stent implantation.

We performed a retrospective review of stent implantation guided by novel image fusion software (VesselNavigator, Philips Healthcare) during the first 9 months since its introduction (Figure). Patient characteristics and catheterization data were reviewed with a focus on the fusion of preintervention imaging and intervention guidance, including structures used for registration, accuracy of 3D reconstruction overlay, and the need for intraprocedural roadmap readjustment.

VesselNavigator was used in all consecutive patients with available precatheterization CT or MRI scans. The 4-step workflow with VesselNavigator, including segmentation, planning, registration and live guidance, has been described elsewhere.^{4,5} For the registration, stored fluoroscopy images in 2 projections were fused with the 3D roadmap (2D-3D registration) using a combination of internal markers such as bony structures, the cardiac silhouette, areas of calcification, previously implanted devices, and vessel borders visualized with injection of a small amount of contrast medium.

Eighteen patients underwent transcatheter stent implantation for the creation of a “landing zone” prior to percutaneous pulmonary valve implantation (n = 7), pulmonary artery stenosis (n = 5), aortic coarctation (n = 3; [video of the supplementary material](#)), aortopulmonary collateral (n = 2) and arterial duct (n = 1) (Table). A 3D roadmap was created from existing CT (n = 17) or MRI (n = 1) datasets. For registration, the spine and vertebrae (n = 17; 94%), calcifications (n = 7, 39%), test angiogram (n = 5, 28%) or a previously placed device (n = 4, 22%) served as reference points for orientation of the 3D roadmap against live fluoroscopy. Accurate overlay was achieved in all but 2 patients (11%) with an additional 2 patients (11%) requiring intraprocedural realignment due to the introduction of a stiff wire and balloon/stent assembly. All stents were deployed at desired locations with no complications. In 13 patients (72%), the stent was positioned and deployed without prior contrast injection.

To date and to our knowledge, this is the first series focusing on application of preregistered 3D datasets exclusively for guidance of stent implantation in congenital heart defects. Our initial experience shows that, with modern fusion software, noninvasive 3D images may be easily and effectively reused for positioning and implantation of stents to various locations.^{2,4,5} A simple registration protocol requires only stored fluoroscopy in 2 projections, akin to the typical setup of isocenter at the beginning of each heart catheterization, and uses a combination of anatomical or iatrogenic landmarks or the injection of a small contrast volume. This 2D-3D registration enabled a shortening of the duration of interventional procedures and a reduction in contrast and radiation exposure.⁶ In several more recent patients, we felt confident enough to perform stent implantation without prior contrast injection.

To test the reproducibility of these promising individual results, we have initiated a prospective, international registry with contributions from Berlin (Germany), Sejong (South Korea), Mexico City (Mexico), Denver (United States), and Lodz (Poland).

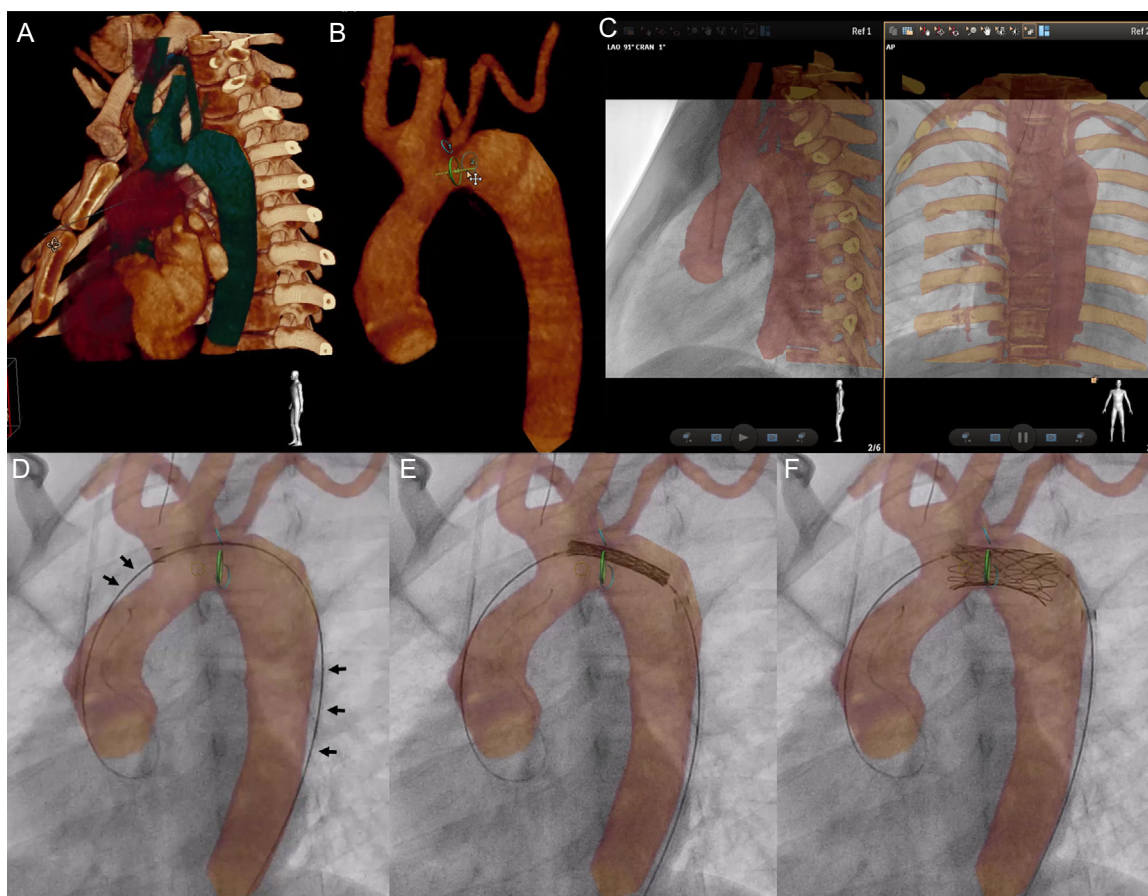


Figure. VesselNavigator assisted aortic arch stent implantation in a 12-year-old patient after surgical treatment of interrupted aortic arch (video of the supplementary material). Automatic 3-dimensional (3D) reconstruction was manipulated to outline the aortic arch, proximal branches, and the thoracic aorta (A). A marking ring (green) was placed at the narrowest site, and a marking point (yellow) at the desired proximal end of the stent (B). Further 2 rings (blue) were placed to indicate the origins of the subclavian arteries. Stored fluoroscopy in 2 perpendicular projections, was utilized for manual alignment of the roadmap and live fluoroscopy with bony structures serving as reference structures (C). Introduction of the delivery system led to slight distortion of the anatomy, which is reflected by wire position on the outer curvature of the 3D reconstruction (black arrows, D). The stent was positioned (E) and deployed (F) with the sole 3D roadmap guidance.

Table

Patient Characteristics and Procedural Data

		N = 18
Demographic data	Age (years)	8.6 (2 weeks-15.9)
	Weight (kg)	30.5 (2.4-55)
	BSA (m ²)	1.1 (0.2-1.6)
	Sex male (%)	11 (61)
Precatheterization imaging	Interval from CT or MRI (days)	31 (0-787)
	DLP (mGy*cm) for CT	43.3 (12-327.7)
	Contrast dose for CT (mL)	26 (5-73)
Catheterization data	DAP (μGy*m ²)	2072 (86.2-16 694.1)
	Indexed DAP (μGy*m ² /kg)	118.2 (35.9-344.7)
	Contrast dose (mL)	39.5 (3-130)
	Indexed contrast dose (mL/kg)	1.4 (0.8-8.8)
	Fluoroscopy time (min)	19.8 (3.3-53.5)
	Procedural time (min)	100 (15-185)

BSA, body surface area; CT, computed tomography; DAP, dose area product; DLP, dose length product; MRI, magnetic resonance imaging.

In conclusion, 3D image fusion facilitates precise stent implantation into various anatomical locations. In selected patients, contrast injection may be spared prior to stent implantation.

SUPPLEMENTARY MATERIAL



Supplementary material associated with this article can be found in the online version available at <https://doi.org/10.1016/j.rec.2018.05.013>.

Sebastian Goreczny,^{a*} Tomasz Moszura,^a Maciej Lukaszewski,^b Michał Podgorski,^b Jadwiga Anna Moll,^a and Paweł Dryzek^a

^aDepartment of Cardiology, Polish Mother's Memorial Hospital, Research Institute, Lodz, Poland

^bDepartment of Radiology, Polish Mother's Memorial Hospital, Research Institute, Lodz, Poland

* Corresponding author:

E-mail address: sebastiangoreczny@yahoo.pl (S. Goreczny).

Available online 15 June 2018

REFERENCES

1. Stangenberg L, Shuja F, Carelsen B, Elenbaas T, Wyers MC, Schermerhorn ML. A novel tool for three-dimensional roadmapping reduces radiation exposure and contrast agent dose in complex endovascular interventions. *J Vasc Surg.* 2015;62:448–455.
2. Goreczny S, Dryzek P, Moszura T, Kühne T, Berger F, Schubert S. 3D image fusion for live guidance of stent implantation in aortic coarctation magnetic resonance imaging and computed tomography image overlay enhances interventional technique. *Postepy Kardiologii Interwencyjnej.* 2017;13:269–272.
3. Sandoval JP, Aristizabal G, Zabal-Cerdeira C. Aortic Stent Implantation Using Live 3-Dimensional Image Fusion Guidance. *Rev Esp Cardiol.* 2018;71:750.
4. Goreczny S, Dryzek P, Moszura T. Stent implantation to ductus arteriosus in a patient with interrupted aortic arch guided by CT image overlay. *Cardiol Young.* 2017;27:1229–1231.
5. Goreczny S, Dryzek P, Morgan GJ, Lukaszewski M, Moll JA, Moszura T. Novel three-dimensional image fusion software to facilitate guidance of complex cardiac catheterization. *Pediatr Cardiol.* 2017;38:1133–1142.
6. Goreczny S, Moszura T, Dryzek P, et al. Three-dimensional image fusion guidance of percutaneous pulmonary valve implantation to reduce radiation exposure and contrast dose: A comparison with traditional two-dimensional and three-dimensional rotational angiographic guidance. *Neth Heart J.* 2017;25:91–99.

<https://doi.org/10.1016/j.rec.2018.05.013>
1885-5857/

© 2018 Sociedad Española de Cardiología. Published by Elsevier España, S.L.U. All rights reserved.