

6. Huisman A, Beun R, Sikma M, Westerink J, Kusadasi N. Involvement of ADAMTS13 and von Willebrand factor in thromboembolic events in patients infected with SARS-CoV-2. *Int J Lab Hematol*. 2020. <http://doi.org/10.1111/ijlh.13244>.
7. Huber-Lang M, Younkin EM, Sarma JV, et al. Generation of C5a by phagocytic cells. *Am J Pathol*. 2002;161:1849–1859.

<https://doi.org/10.1016/j.rec.2020.08.021>  
1885-5857/

© 2020 Sociedad Española de Cardiología. Published by Elsevier España, S.L.U. All rights reserved.

## Arterial thrombotic complications in hospitalized patients with COVID-19. Response to related letters



### Complicaciones arteriales trombóticas en pacientes hospitalizados con COVID-19. Respuesta a cartas relacionadas

#### To the Editor,

We appreciate the interest shown by Kow et al. in our work.<sup>1</sup> We fully agree with the comment that the lower cardiovascular risk profile in the cohort of patients with coronavirus disease 2019 (COVID-19), as well as the simultaneous thrombosis in different territories, supports the hypothesis of a systemic prothrombotic state in close relation to the inflammatory response associated with the severe acute respiratory syndrome coronavirus 2 (SARS-CoV-2)<sup>1,2</sup>.

Regarding the potential use of prophylactic antiplatelet therapy for its antithrombotic effect and perhaps even, as noted by the authors, its antiviral effect in patients with COVID-19, we recognize that this is an attractive proposal, but currently there is no clear clinical evidence of its usefulness in SARS-CoV-2 infection. There is no doubt about the importance of antiplatelet therapy in patients with arterial thrombotic complications, but its use in patients with high cardiovascular risk without established disease provides minimal benefit and an increased risk of bleeding complications.<sup>3</sup> One might think that with COVID-19 this would be different due to the endothelial dysfunction and inflammatory response it causes, but we must avoid empiricism and not support its de novo use in patients with COVID-19 without a specific cardiovascular reason, except in research studies specifically designed to test its efficacy.

We also thank and congratulate Valga et al.<sup>4</sup> for their recent publication on the role played by endothelial injury, complement, and coagulation in the pathogenesis of coronavirus disease. In our scientific letter,<sup>1</sup> we focused exclusively on the 1.8% (n = 38) of COVID-19 positive patients with arterial thrombotic complications treated at our hospital in March 2020. Although they had a higher

score according to the International Society on Thrombosis and Haemostasis (ISTH) diagnostic criteria for disseminated intravascular coagulation (DIC), only 3 strictly met the diagnostic criteria. As other authors have noted,<sup>5</sup> it is likely that patients with COVID-19 have a severe hypercoagulability, more so than a consumption coagulopathy, as is the case of classical DIC. Indeed, the pattern is different, as in patients with COVID-19, fibrinogen is characteristically elevated and thrombocytopenia is uncommon, and if it occurs, it is usually mild or moderate. We agree with the hypothesis of Valga et al. of multiple interactions between the immune system, coagulation (immunothrombosis), and associated endothelial dysfunction as a response to SARS-CoV-2 to explain the prothrombotic state of coronavirus disease.

Juan R. Rey,\* José Luis Merino, Ángel M. Iniesta, and Juan Caro-Codón, CARD-~~COVID~~ investigators  
Servicio de Cardiología, Hospital Universitario La Paz, Madrid, Spain

\*Corresponding author:

E-mail address: [juanr.rey@salud.madrid.org](mailto:juanr.rey@salud.madrid.org) (J.R. Rey).

Available online 12 October 2020

#### REFERENCES

1. Rey JR, Caro-Codón J, Poveda Pineda D, et al. Arterial thrombotic complications in hospitalized patients with COVID-19. *Rev Esp Cardiol*. 2020;73:769–771.
2. Rey JR, Jiménez Valero S, Poveda Pineda D, et al. COVID-19 and simultaneous thrombosis of two coronary arteries. *Rev Esp Cardiol*. 2020;73:676–677.
3. ASCEND Study Collaborative Group, Bowman L, Mafham M, et al. Effects of aspirin for primary prevention in persons with diabetes mellitus. *N Engl J Med*. 2018;379:1529–1539.
4. Valga F, Vega-Díaz N, Macía M, et al. Targeting complement in severe coronavirus disease 2019 to address microthrombosis. *Clin Kidney J*. 2020;13:477–479.
5. Fogarty H, Townsend L, Ni Cheallaigh C, et al. More on COVID-19 coagulopathy in Caucasian patients. *Br J Haematol*. 2020;189:1060–1061.



<https://doi.org/10.1016/j.rec.2020.09.020>  
1885-5857/

© 2020 Sociedad Española de Cardiología. Published by Elsevier España, S.L.U. All rights reserved.

#### SEE RELATED CONTENT:

<https://doi.org/10.1016/j.rec.2020.08.009>

<https://doi.org/10.1016/j.rec.2020.08.021>

## Telematic cardiology consultation in the elderly. The 5 M framework can help



### Consulta telemática de cardiología para ancianos. La regla de las 5 M puede ser una ayuda

#### To the Editor,

We read with great interest the excellent consensus document of the Spanish Society of Cardiology on teleconsulta-

tions for clinical cardiologists in the era of COVID-19 by Barrios et al.<sup>1</sup> Telematic cardiology consultations are now a reality in Spain<sup>2</sup> and a document to help organize them will always be welcome. However, as active members of the Geriatric Cardiology Section, we were disappointed to see that there was no specific reference to elderly patients, who make up a very high percentage of the patients we see in our everyday practice. Elderly patients, who are particularly vulnerable to coronavirus infection,<sup>3</sup> need more help to understand that telematic medicine can be an effective way to communicate with their cardiologists and to be able to use it effectively. With this in mind, the 5 M framework<sup>4,5</sup> (figure 1) can be a useful guide for teleconsultations:

#### SEE RELATED CONTENT:

<https://doi.org/10.1016/j.rec.2020.06.032>

<https://doi.org/10.1016/j.rec.2020.09.022>

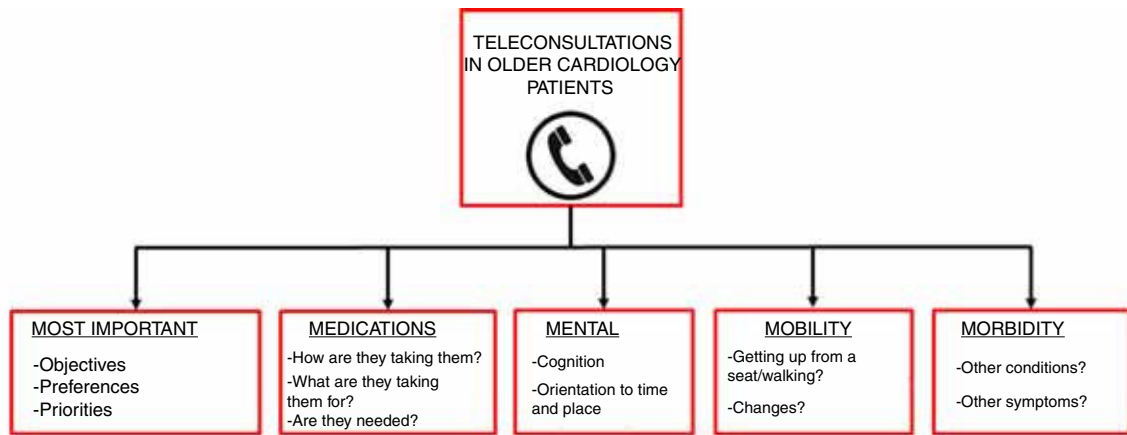


Figure 1. 5 M framework for teleconsultations with older cardiology patients.

- **Most important:** ask the patient about their objectives, preferences, and priorities. This is an excellent way to establish a good relationship at the beginning of a teleconsultation.
- **Medications:** checking which medications the patient is taking is straightforward in most of the autonomous communities in Spain due to the electronic prescribing system. It is important to check how patients take their medication and if they know what it is for, as well as to assess possible withdrawal of unnecessary drugs.
- **Mental:** it is essential to address the patient's cognition in each consultation. A brief evaluation of possible cognitive decline will help to ensure that any discussion is understood and remembered. Assessment of orientation to time and place and cognitive status can be performed quickly and easily with questions such as: "What day of the week is it?" or "Can you tell me the months of the year backwards, starting with December?"
- **Mobility:** basic mobility can be assessed during a teleconsultation by enquiring about the patient's ability to get up from a chair and walk. Recent changes in mobility can also be assessed by comparing their current and previous status.<sup>6</sup>
- **Morbidity:** it is essential to consider the other conditions that may be present in our patients, often with a marked effect on prognosis, and that these can also cause symptoms that may be confused with those of some cardiac processes.

During this time of pandemic when older patients are suffering the stress of a public health crisis compounded by the need to adapt to newer technologies, any action that can help make teleconsultations safer, easier, and more person-centered are welcomed. The 5-M framework is a simple way to personalize telemedicine and support our older patients.

Pablo Díez-Villanueva,<sup>a</sup> Clara Bonanad,<sup>b</sup> Albert Ariza-Solé,<sup>c</sup> and Manuel Martínez-Sellés<sup>d,e,\*</sup>

<sup>a</sup>Servicio de Cardiología, Hospital Universitario de La Princesa, Madrid, Spain

<sup>b</sup>Servicio de Cardiología, Hospital Clínico Universitario de Valencia, Valencia, Spain

<sup>c</sup>Servicio de Cardiología, Hospital Universitario de Bellvitge, IDIBELL, L'Hospitalet de Llobregat, Barcelona, Spain

<sup>d</sup>Servicio de Cardiología, Hospital General Universitario Gregorio Marañón, Universidad Europea, Universidad Complutense, Madrid, Spain

<sup>e</sup>Centro de Investigación Biomédica en Red de Enfermedades Cardiovasculares (CIBERCV), Spain

\* Corresponding author:

E-mail address: [mmselles@secardiologia.es](mailto:mmselles@secardiologia.es) (M. Martínez-Sellés).

Available online 21 October 2020

## REFERENCES

1. Barrios V, Cosín-Sales J, Bravo M, et al. La consulta telemática para el cardiólogo clínico en tiempos de la COVID-19: presente y futuro. Documento de consenso de la Sociedad Española de Cardiología. *Rev Esp Cardiol.* 2020;73:910–918.
2. Postigo A, González-Mansilla A, Bermejo J, Elizaga J, Fernández-Avilés F, Martínez-Sellés M. Telecardiology in times of the COVID-19 pandemic. *Rev Esp Cardiol.* 2020;73:674–675.
3. Bonanad C, García-Blas S, Tarazona-Santabalbina FJ, et al. Coronavirus: the geriatric emergency of 2020. Joint document of the Section on Geriatric Cardiology of the Spanish Society of Cardiology and the Spanish Society of Geriatrics and Gerontology. *Rev Esp Cardiol.* 2020;73:569–576.
4. Fulmer T, Mate KS, Berman A. The Age-friendly health system imperative. *J Am Geriatr Soc.* 2018;66:22–24.
5. Tinetti M, Huang A, Molnar F. The Geriatrics 5M's: a new way of communicating what we do. *J Am Geriatr Soc.* 2017;65:2115.
6. Díez-Villanueva P, Arizá-Solé A, Vidán MT, et al. Recomendaciones de la Sección de Cardiología Geriátrica de la Sociedad Española de Cardiología para la valoración de la fragilidad en el anciano con cardiopatía. *Rev Esp Cardiol.* 2019;72:145–153.



<https://doi.org/10.1016/j.rec.2020.08.019>  
1885-5857/

© 2020 Sociedad Española de Cardiología. Published by Elsevier España, S.L.U. All rights reserved.