

Table
Clinical Profile of Referred Patients Who Underwent Surgery

	Referred	Operated
Patients	75 (3.4/month)	44 (2/month)
Men	62 (82.7)	37 (84.1)
Age (y)	68.15 (43-84)	66.48 (43-82)
Isolated coronary artery bypass graft	42 (56)	27 (61.3)
Systolic dysfunction (LVEF < 35%)	19 (25.3)	8 (18.2)

LVEF, left ventricular ejection fraction.

Values are expressed as no (%) or mean (range).

practice guidelines of the European Society of Cardiology¹ clearly state that CABG is indicated in diabetic patients with disease in 2 or more vessels (class 1, level A). The number of patients who met this criterion in our study and who, according to the recommendations, were candidates for CABG as the first therapeutic option, was 287 (20.3%). CABG should also be considered in other anatomical contexts, such as main artery disease and multivessel disease with complex SYNTAX score, etc.

We believe that the results of this study are consistent with standard practice in Spain; while our data have the limitation of being from a single center, and one that does not have a cardiac surgery department, they indicate that CABG is used sparingly and that there is a lack of adherence to some of the recommendations of the European Society of Cardiology clinical practice guidelines on coronary revascularization, which have been adopted by the Spanish Society of Cardiology. Even if the comparison between our data and the general situation in Spain and other countries should not be considered rigorous because it relied on data from voluntary registries and did not include patients who, despite residing in our catchment area, were not treated at or referred from our center, the available information indicates that CABG is used to a lesser extent in Spain, and probably with significant regional differences.

Scientific societies for cardiology and cardiac surgery should appraise this situation, which, among other consequences, hampers cardiac surgeons' ability to acquire and maintain new

skills. If indeed there are specific circumstances that advise against applying the European guidelines in Spain, then we should develop our own national guidelines. Otherwise, we need to determine the causes that have created and continue to promote this attitude and develop measures to correct them.

Eduardo Vázquez Ruiz de Castroviejo,*
Juan Ángel Herrador Fuentes, Manuel Guzmán Herrera,
Víctor Aragón Extremera, Edgardo Maxim Alania Torres,
and Juan Carlos Fernández Guerrero

Unidad de Gestión Clínica de Cardiología, Complejo Hospitalario de Jaén, Jaén, Spain

* Corresponding author:

E-mail address: vazquez89@arrakis.es

(E. Vázquez Ruiz de Castroviejo).

Available online 2 May 2015

REFERENCES

- Windecker S, Kolh P, Alfonso F, Collet JP, Cremer J, Falk V, et al. 2014 ESC/EACTS Guidelines on myocardial revascularization. *Eur Heart J*. 2014;35:2541–619.
- Centella T, Igual A, Hornero F. Cirugía cardiovascular en España en el año 2011. Registro de intervenciones de la Sociedad Española de Cirugía Torácica-Cardiovascular. *Cir Cardiovasc*. 2013;20:74–88.
- Funkat AK, Beckmann A, Lewandowski J, Frie M, Schiller W, Ernst M, et al. Cardiac surgery in Germany during 2011: A report on behalf of the German Society for Thoracic and Cardiovascular Surgery. *Thorac Cardiovasc Surg*. 2012; 60:371–82.
- Go AS, Mozaffarian D, Roger V, Benjamin EJ, Berry JD, Blaha MJ, et al. Heart disease and stroke statistics—2014 Update. A report from the American Heart Association. *Circulation*. 2013;129:e228–92.
- Díaz JF, de La Torre JM, Sabate M, Goicolea J. Registro Español de Hemodinámica y Cardiología Intervencionista. XXI Informe Oficial de la Sección de Hemodinámica y Cardiología Intervencionista de la Sociedad Española de Cardiología (1990–2011). *Rev Esp Cardiol*. 2012;65:1106–16.
- Morales Salinas A. Tratamiento médico óptimo: ¿es la peor opción en la enfermedad coronaria multivascular? *Rev Esp Cardiol*. 2014;67:1074.

<http://dx.doi.org/10.1016/j.rec.2015.02.022>

Switch From a Long-term to a Short-term Ventricular Assist Device as a Bridge to Heart Transplantation



Cambio de dispositivo de asistencia ventricular de larga duración a dispositivo de corta duración como puente al trasplante cardíaco

To the Editor,

Despite the success of the Spanish heart transplant program, in recent years the number of optimal donors has diminished, leading to longer waiting times and an increase in urgent heart transplantation (HT).¹

Patients undergoing urgent transplantation have worse survival and therefore it is recommended that their clinical status be improved by the use of ventricular assist devices. Currently, 15% of patients in Spain are bridged to HT with ventricular assist devices. Because waiting times are below 6 months for an elective HT and

less than 1 month for urgent HT,¹ most patients can be bridged with short- or mid-term ventricular assist devices. The Berlin Heart EXCOR[®] (Berlin Heart AG, Berlin, Germany) left ventricular assist devices (LVAD) are a common choice.

We report 2 cases in which an EXCOR[®] LVAD was replaced by a short-term continuous flow ventricular assist device CentriMag[®] (Thoratec Corp, Pleasanton, California, United States) as a bridge to transplantation because of thromboembolic complications.

The first case was a 55-year-old man with ischemic dilated cardiomyopathy, who underwent EXCOR[®] implantation as a bridge to HT candidacy due to irreversible severe pulmonary artery hypertension. Ten days after implantation, while transitioning from heparin to acenocoumarol (international normalized ratio [INR] of 2) and aspirin 100 mg, he developed a transient ischemic attack. On day 17, with an INR of 3, a red thrombus was seen in the sinuses of the polyurethane valves (PUVs). Dipyridamole 300 mg/d and heparin were added with thrombus resolution. Aggregometry showed arachidonic acid inhibition of 80%. Clopidogrel 75 mg/d was added because of persistent white fibrin deposits. On day 40, a right heart catheterization showed reversibility of the pulmonary



Figure 1. Red thrombus in the PUV of the EXCOR[®] (arrow).

hypertension. However, in the context of a change to heparin, the patient developed an ischemic stroke. Red thrombi were seen in the sinuses of the PUVs (Figure 1). The EXCOR[®] LVAD was replaced by a CentriMag[®] LVAD without re sternotomy using the EXCOR[®] cannulas. One week later, without neurological deficit, the patient was included on the urgent HT list. However, we observed white fibrin deposits in the adaptor that connected the EXCOR[®] and CentriMag[®] cannulas (Figure 2). Seventeen days after inclusion on

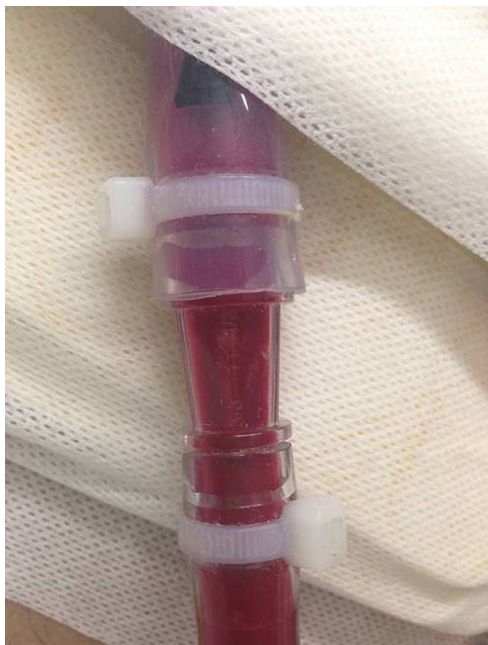

Figure 2. Connection between EXCOR[®] and CentriMag[®] cannulas.

the HT list, the patient developed a catheter-related bacteremia and during transient reduction of heparin for a change of catheter, he developed a new ischemic stroke with hemorrhagic transformation and died.

The second case was a 44-year-old man with ischemic dilated cardiomyopathy who was admitted with decompensated heart failure and needed support with inotropes and intra-aortic balloon pump. The patient was included on the urgent HT list, status 1. Fourteen days later, an EXCOR[®] LVAD was implanted as a bridge to transplantation. The patient developed cardiac tamponade on the fifth postoperative day, which required the cessation of anticoagulation and surgery. After surgery, heparin and aspirin 100 mg/d were restarted but the patient had an ischemic stroke with left hemianopsia and a large red thrombus at the level of the PUV of the outflow cannula. Aggregometry showed no arachidonic acid inhibition and the heart team decided to replace the EXCOR[®] with a CentriMag[®] LVAD using the EXCOR[®] cannulas. Over the next few days, white fibrin deposits were observed in the adaptor connecting the EXCOR[®] and CentriMag[®] cannulas, despite treatment with heparin and clopidogrel, but no new neurological deficit developed, so the patient was included for urgent HT, status 0, and was successfully transplanted 17 days after LVAD change.

The incidence of neurological complications in patients with EXCOR[®] varies among series.² Management is complex and neurological status frequently becomes a contraindication for HT. We present 2 cases in which EXCOR[®] implanted as a bridge to transplantation were replaced with short-term continuous flow devices. The reasons for this substitution and for not using another EXCOR[®] were the following:

1. Thromboembolic complications seemed to be related to a particular component of the EXCOR[®] LVAD: the PUVs. Until 2014, implanted EXCOR[®] in adults had mechanical tilting-disk valves. We had no thromboembolic complications in our previous experience. In 2014, we implanted 3 devices with the new PUVs. We suspect that the thrombotic risk in the sinuses of PUVs of the EXCOR[®] for adults is higher than with the previous mechanical valves, as any reduction of anticoagulation was followed by thromboembolic events. In addition, adults with ischemic cardiomyopathy may have a higher thrombotic risk than pediatric patients, the population in which the safety of these PUVs has been tested.² The strategy for prevention of thromboembolic complications with the new EXCOR[®] LVAD is not entirely established. It is likely that more aggressive antiplatelet therapy (by using clopidogrel instead of aspirin) or frequent assessment of platelet function will be recommended for patients with ischemic cardiomyopathy.
2. Waiting times on the urgent HT list, status 0, are still usually below 1 month. The CentriMag[®] has little thrombogenicity and can give support for up to 1 month, although longer supports have been reported. Because the EXCOR[®] cannulas can be connected to the CentriMag[®] LVAD without re sternotomy, this strategy is safe in patients with thrombotic complications affecting the extracorporeal circuit of the VAD when the waiting time for urgent HT is short. The only caveat to this approach is that the connection requires an adaptor and we saw thrombus deposition at this level.

In conclusion, we report 2 adult patients in whom we exchanged a long-term LVAD for a short-term LVAD as a bridge to transplantation. We believe the design of the PUVs of the EXCOR[®] could be partially responsible for the thrombotic

complications. A switch to a short-term LVAD is feasible within the Spanish heart transplant program.

* Corresponding author:

E-mail address: couto.mallon.david@gmail.com (D. Couto-Mallón).

Available online 8 May 2015

David Couto-Mallón,^{a,*} José González-Costello,^a
José Carlos Sánchez-Salado,^a Albert Miralles-Cassina,^b
Nicolás Manito-Lorite,^a and Ángel Cequier-Fillat^a

^aÀrea de Malalties del Cor, Departament de Cardiologia, Hospital Universitari de Bellvitge, L'Hospitalet del Llobregat, Barcelona, Spain

^bÀrea de Malalties del Cor, Departament de Cirurgia Cardíaca, Hospital Universitari de Bellvitge, L'Hospitalet del Llobregat, Barcelona, Spain

REFERENCES

- González-Vílchez F, Gómez-Bueno M, Almenar L, Crespo-Leiro MG, Arizón JM, Palomo J, et al. Spanish Heart Transplantation Registry. 25th Official Report of the Spanish Society of Cardiology Working Group on Heart Failure and Heart Transplantation (1984-2013). *Rev Esp Cardiol.* 2014;67:1039-51.
- Malaisrie SC, Pelletier MP, Yun JJ, Sharma K, Timek TA, Rosenthal DN, et al. Pneumatic ventricular assist device in paracorporeal infants and children: initial Stanford experience. *J Heart Lung Transplant.* 2008;27:173-7.

<http://dx.doi.org/10.1016/j.rec.2015.02.020>

Short-term Heparin Re-exposure During Heart Transplantation in Patients With Ventricular Assist Devices and Acute Heparin-induced Thrombocytopenia



Reexposición temprana a heparina durante el trasplante cardíaco de pacientes con trombocitopenia inducida por heparina y asistencia ventricular

To the Editor,

The increasing use of ventricular assist devices as a bridge to heart transplantation improves survival in candidates for

transplantation. Intravenous unfractionated heparin (UFH) is routinely used to prevent the thromboembolic complications associated with the pump and support cannulae. Occasionally, UFH can trigger a specific immunological response, characterized by the development of antibodies against UFH/platelet factor 4 complex, activating platelets, and leading to heparin-induced thrombocytopenia (HIT). In such cases, UFH must be switched to an alternative anticoagulation, usually parenteral direct thrombin inhibitors.¹

After 3 months, anti-UFH/platelet factor 4 antibodies are usually undetectable, and the risk of recurrent HIT on re-exposure to heparin is reduced. For patients with acute or subacute HIT requiring cardiopulmonary bypass (CPB) surgery, clinical

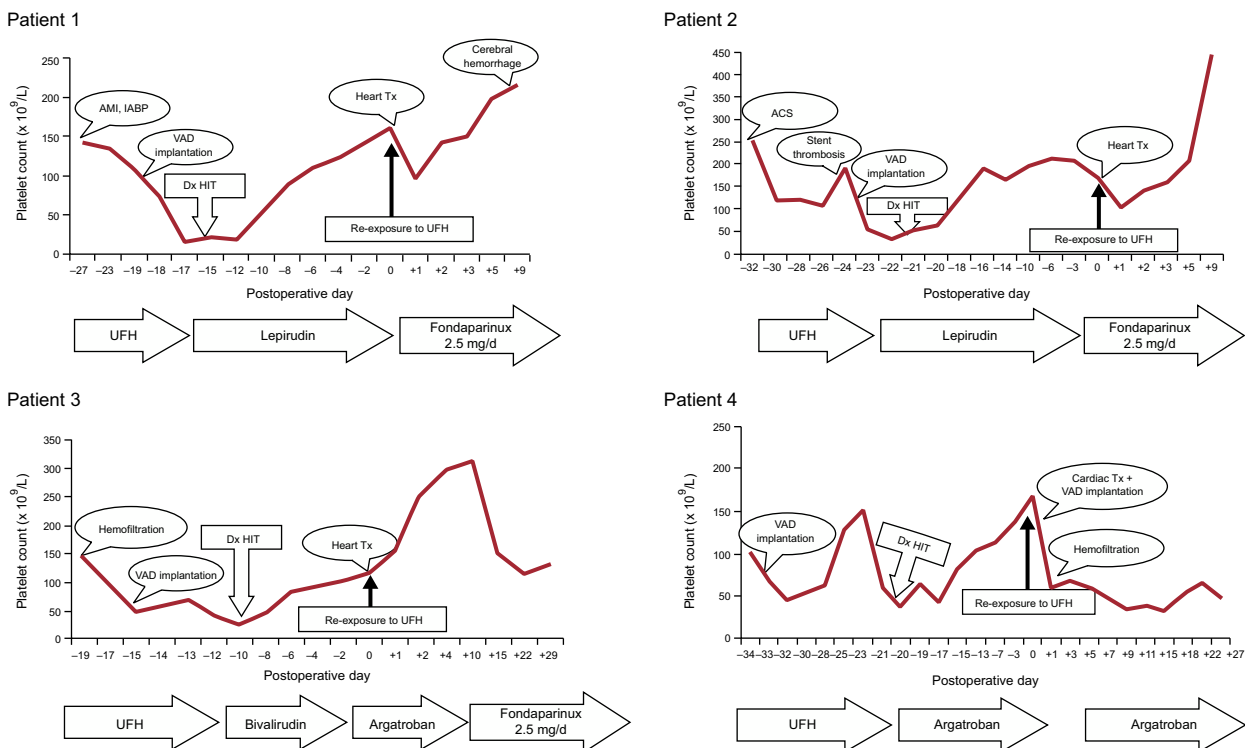


Figure. Trends in platelet count. ACS, acute coronary syndrome; AMI, acute myocardial infarction; Dx HIT, diagnosis of heparin-induced thrombocytopenia; IABP, intra-aortic balloon pump; Tx, transplant; UFH, unfractionated heparin; VAD, ventricular assist device.