

## Image in cardiology

## Successful Clinical and Therapeutic Approach for Valve-in-valve Leaflet Thrombosis



## Exitoso abordaje clínico y terapéutico de trombosis en procedimiento valve-in-valve

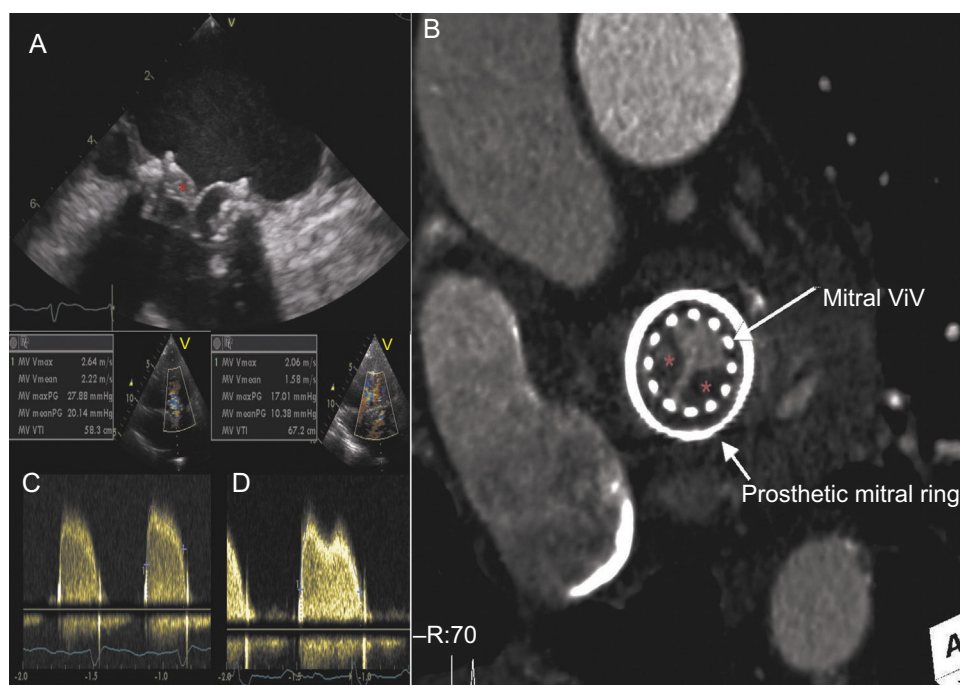
Francisco Gama,<sup>a,\*</sup> Rui Campante Teles,<sup>b</sup> and Pedro Freitas<sup>a</sup><sup>a</sup> Cardiology Department, Hospital de Santa Cruz, Lisbon, Portugal<sup>b</sup> Cardiology Department, Hospital de Santa Cruz, Nova Medical School, Lisbon, Portugal

Figure.

An 87-year-old woman with rheumatic valve disease underwent aortic, mitral (Hancock II 27) and tricuspid biological prosthetic valve implantation in 2010.

In 2016, a transapical mitral valve-in-valve procedure (ViV; Edwards Sapien 26) was performed because of prosthesis degeneration with predominant intraprosthesis regurgitation. The patient was in sinus rhythm and a long-term clopidogrel antithrombotic regimen was started.

She was admitted in December 2017 with a 3-week history of exertional dyspnea and orthopnea. A transthoracic echocardiogram (TTE) revealed a severely obstructed mitral prosthesis (mean gradient of 20 mmHg and right ventricle-right auricle gradient of 96 mmHg). A transesophageal echocardiogram suggested the presence of a prosthetic thrombosis (asterisk), as hypoechoic material overlapped the atrial surface of the posterior leaflet (Figure A).

Restrictive motion of the prosthetic leaflets, covered by hypodense thrombotic material (asterisk), was also depicted by computed tomography (Figure B). Given the patient's hemodynamic stability and high surgical risk, a conservative strategy with unfractionated intravenous heparin and clopidogrel was attempted. The clinical course was favorable with a gradual increase in exercise tolerance and normalization of prosthetic gradients at the first month, confirmed by transthoracic echocardiography (Figure C and Figure D).

The incidence of transcatheter heart valve thrombosis after mitral ViV procedures remains largely unknown and scarcely reported, with uncertain treatment and undefined antithrombotic regimens. It is particularly interesting in the era of the upcoming percutaneous mitral bioprosthesis. We found this case notable for its rarity and favorable outcome under anticoagulation and antiplatelet therapy. Complementary use of multimodality imaging improved our confidence in its diagnosis and the treatment strategy selected.

\* Corresponding author:

E-mail address: francisfogama@gmail.com (F. Gama).

Available online 7 July 2018