

In all patients except 1, a guidewire was introduced from the contralateral femoral artery, as described previously.<sup>2</sup> In 4 patients, balloon angioplasty was carried out at the start of the procedure at the level of the left or right common iliac artery; the procedure was performed with an 8 × 40 mm Wanda balloon (Boston Scientific, Ratingen, Germany) in 3 patients and with a nonexpandable 5 × 15 mm Euphora balloon (Medtronic) in the other patient.

In 3 patients, we also took advantage of the dynamic expansion mechanism available with the Edwards eSheath and the Novaflex + delivery system: the whole system was withdrawn to a region of wider diameter as the valve was advanced, allowing introduction of the delivery system through the narrower segment.

In 1 patient with severe peripheral vascular disease and trouser-like stenting at the iliac bifurcation, the distal iliac border of the stent was supported by balloon angioplasty during sheath introduction (Figure). In all patients, percutaneous closure was achieved with the Prostar XL system (Abbott Vascular; Santa Clara, California, United States). In 1 patient, active bleeding was observed at the end of the procedure; the failure of the Prostar XL system in this patient was likely due to large-scale vessel calcification impeding wound suturing. The hemorrhage resolved immediately upon implantation of a 10 × 38 mm Advanta v12 polytetrafluoroethylene-coated stent (Atrium Medical Corp; Hudson, New Hampshire, United States). In another patient, with moderate bleeding, internal hemostasis was restored by prolonged inflation of the balloon used for predilation. In all patients, outcome was monitored by angiography from the contralateral femoral artery. There were no major intraprocedural complications, and patients were discharged from hospital 3.5 ± 4.3 days after the procedure.

In the only previous report of transfemoral TAVI with narrow femoral access, predilation was used in 17 patients, resulting in 6 cases of iliac dissection.<sup>6</sup> In our series, there were no dissections; however, this might reflect the predominant use of the latest generation Edwards-SAPIEN 3 prosthesis, which is introduced through a narrow-bore and highly compliant sheath. When treating patients with difficult femoral access, contralateral guidewire placement is essential to ensure immediate and effective access in the event of complications.

With appropriate planning and familiarity with established percutaneous techniques, transfemoral TAVI is a safe and effective procedure in patients with small diameter femoral access.

Leire Unzué,<sup>a,\*</sup> Eulogio García,<sup>a</sup> Rodrigo Teijeiro,<sup>a</sup> Miguel Rodríguez del Río,<sup>b</sup> Jorge Solís,<sup>a</sup> and Belén Rubio Alonso<sup>a</sup>

<sup>a</sup>Servicio de Cardiología, Hospital Universitario Madrid Montepríncipe, Madrid, Spain

<sup>b</sup>Servicio de Anestesiología, Hospital Universitario Madrid Montepríncipe, Madrid, Spain

\*Corresponding author:

E-mail address: leireunzue@yahoo.es (L. Unzué).

Available online 22 November 2016

## REFERENCES

1. Biancari F, Rosato S, D'Errigo P, et al. Immediate and intermediate outcome after transapical versus transfemoral transcatheter aortic valve replacement. *Am J Cardiol*. 2016;117:245–251.
2. García E, Martín-Hernández P, Unzué L, Hernández-Antolín RA, Almería C, Cuadrado A. Usefulness of placing a wire from the contralateral femoral artery to improve the percutaneous treatment of vascular complications in TAVI. *Rev Esp Cardiol*. 2014;67:410–412.
3. Sari C, Ayhan H, Aslan AN, Durmaz T, Keleş T, Baştuğ S. Predictors and incidence of access site complications in transcatheter aortic valve implantation with the use of new delivery systems. *Perfusion*. 2015;30:666–674.
4. Criqui MH, Ninomiya JK, Wingard DL, Ji M, Fronck A. Progression of peripheral arterial disease predicts cardiovascular disease morbidity and mortality. *J Am Coll Cardiol*. 2008;52:1736–1742.
5. Kapadia SR, Tuzcu EM, Makkar RR, Svensson LG, Agarwal S, Kodali S. Long-term outcomes of inoperable patients with aortic stenosis randomly assigned to transcatheter aortic valve replacement or standard therapy. *Circulation*. 2014;130:1483–1492.
6. Ruparelia N, Buzzatti N, Romano V, Longoni M, Figini F, Montorfano M. Transfemoral transcatheter aortic valve implantation in patients with small diseased peripheral vessels. *Cardiovasc Revasc Med*. 2015;16:326–330.

<http://dx.doi.org/10.1016/j.rec.2016.10.008>  
1885-5857/

© 2016 Sociedad Española de Cardiología. Published by Elsevier España, S.L.U. All rights reserved.

## “Subclinical” Leaflet Thrombosis in Transcatheter Aortic Valve Implantation: A Latent Risk?



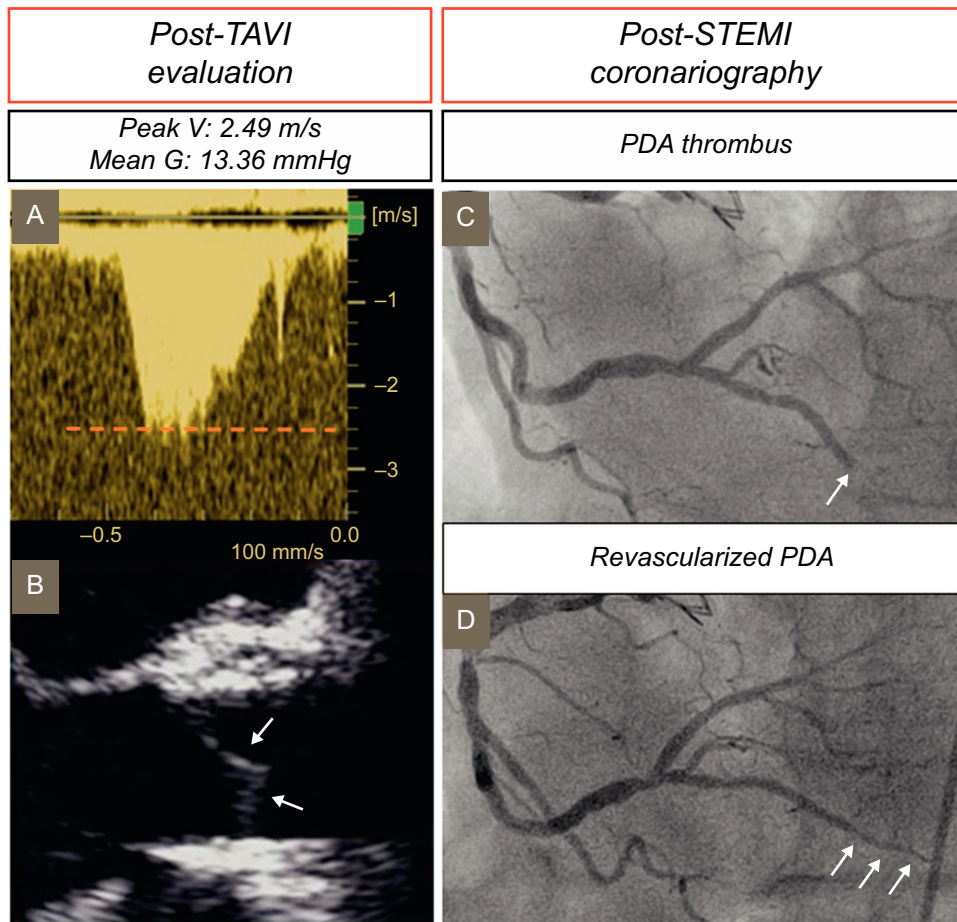
### Trombosis valvular “subclínica” tras implante percutáneo de válvula aórtica: ¿un riesgo latente?

#### To the Editor,

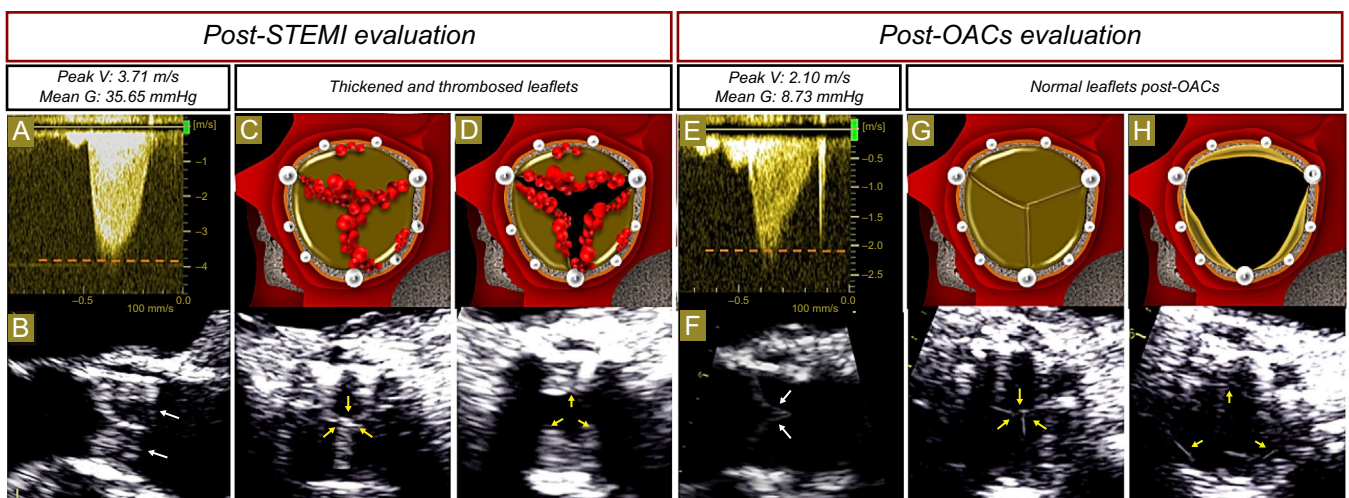
An 87-year-old man with symptomatic severe aortic valve stenosis and a previous percutaneous coronary intervention in the right coronary artery underwent transcatheter aortic valve implantation (TAVI) with a balloon-expandable prosthesis (Edwards Sapien XT). No complications were detected during the procedure guided by transesophageal echocardiography (TEE) (Video 1 of the supplementary material). Posterior transthoracic echocardiography (TTE) demonstrated a normal mean transvalvular gradient (Figure 1A–1B). The patient was discharged with antithrombotic treatment consisting of aspirin 100 mg/d indefinitely and clopidogrel 75 mg/d for 3 months. One year later, the patient was admitted with inferior ST-segment elevation myocardial infarction and underwent coronary angiography, which showed an abrupt obstruction in the distal part of the posterior

descending segment of the right coronary artery, with the typical angiographic appearance of coronary embolism (Figure 1C). Percutaneous coronary intervention was performed with a low profile balloon inflated at very low atmospheres due to the small diameter of the vessel segment where the embolus had stopped (Figure 1D). No evidence of atrial fibrillation during follow-up or hospitalization was observed. Nevertheless, an aortic systolic murmur was detected on exploratory evaluation, with no anemia on laboratory tests or clinical signs of infection. Postprocedural TTE showed an increase in transvalvular aortic gradients compared with a previous study (Figure 2A). The TEE showed an increase in the thickness of the 3 leaflets with restricted motion compared with the previous echocardiographic study, and an aortic valve area of 1.1 cm<sup>2</sup> assessed by planimetry (Figure 2B–2D, and Video 2 of the supplementary material). With a suspected diagnosis of subclinical leaflet prosthetic thrombosis, anticoagulation consisting of acenocoumarol was initiated. Three months later, a follow-up TTE and TEE showed normal transvalvular aortic gradients (Figure 2E) with thinning of the 3 valvular leaflets (Figure 2F–2H, and Video 3 of the supplementary material).

Subclinical leaflet thrombosis in TAVI has been reported in 3% to 4% of patients with balloon-expandable prostheses beyond the first month postprocedure,<sup>1,2</sup> and also in other types of TAVI



**Figure 1.** TTE continuous wave Doppler and 2-dimensional TEE evaluation post-TAVI. A: Postimplantation follow-up TTE shows normal peak velocity and mean transvalvular gradient. B: TEE in the midesophageal long-axis view depicts thin aortic leaflets (arrows). C, D: Coronary angiography images showing a typical embolism lesion with abrupt closure in the posterior descending artery (C arrow), with posterior recanalization after percutaneous transluminal coronary angioplasty (D arrows). Mean G, mean gradient; PDA, posterior descending artery; Peak V, peak velocity; STEMI, ST-segment elevation myocardial infarction; TAVI, transcatheter aortic valve implantation; TEE, transesophageal echocardiography; TTE, transthoracic echocardiography.



**Figure 2.** TTE continuous wave Doppler, TEE in 2-dimensional midesophageal long-axis and TEE in 2-dimensional short-axis views with explanatory colored illustrations. A: One year after TAVI, there is an increase in peak velocity and mean gradient. B: Aortic leaflets are significantly thickened (white arrows). Thrombosis of the 3 leaflets (yellow arrows) in TAVI in diastole (C) and systole (D) with restricted valve opening demonstrated by TEE images. E: After 3 months of anticoagulation therapy, peak velocity and mean gradient have become normal. F: Aortic leaflets again exhibit thinning (white arrows). Thinning of aortic leaflets (yellow arrows) after anticoagulation medication in diastole (G) and systole (H) observed by TEE. Mean G, mean gradient; OACs, oral anticoagulants; Peak V, peak velocity; STEMI, ST-segment elevation myocardial infarction; TAVI, transcatheter aortic valve implantation; TEE, transesophageal echocardiography; TTE, transthoracic echocardiography.

and surgical biological prosthetic valves.<sup>3</sup> The diagnosis is based on leaflet thickening and restricted motion detected by echocardiography or multidetector computed tomography.<sup>1–3</sup> Nevertheless, in vitro models have shown mean transvalvular gradients to be increased only when at least 2 leaflets are affected, as in our patient.<sup>3</sup> These patients are not under anticoagulation therapy or receive antiplatelet medication alone, and anticoagulation therapy is the first option.<sup>3</sup> Although these findings have been described as “subclinical” leaflet thrombosis, patients with this complication have recently been reported to have a higher incidence of stroke and transient ischemic attacks.<sup>3,4</sup> Coronary thrombosis has been reported during TAVI.<sup>5</sup> However, there have been no previous reports of coronary embolism in the chronic phase secondary to leaflet thrombosis in TAVI, as in our patient. These complications raise the need to review imaging follow-up protocols and antiplatelet/anticoagulation therapy in TAVI patients during the first year after implantation.

#### SUPPLEMENTARY MATERIAL



Supplementary material associated with this article can be found in the online version available at doi:10.1016/j.rec.2016.08.007.

Sergio Moral,<sup>a,\*</sup> Juli Carballo,<sup>a</sup> Esther Ballesteros,<sup>b</sup> Alejandro Panaro,<sup>a</sup> and Arturo Evangelista<sup>a,c</sup>

<sup>a</sup>Departamento de Cardiología, Centro Cardiovascular Sant Jordi, Hospital del Pilar, Barcelona, Spain

<sup>b</sup>Departamento de Radiología, Centro de Atención Primaria Pare Claret, Instituto Catalán de la Salud, Barcelona, Spain

<sup>c</sup>Departamento de Cardiología, Hospital Universitario Vall d'Hebron, Barcelona, Spain

\*Corresponding author:

E-mail address: [moral.sergio@yahoo.es](mailto:moral.sergio@yahoo.es) (S. Moral).

Available online 1 October 2016

#### REFERENCES

1. Leetmaa T, Hansson NC, Leipsic J, et al. Early aortic transcatheter heart valve thrombosis: diagnostic value of contrast-enhanced multidetector computed tomography. *Circ Cardiovasc Interv*. 2015. <http://dx.doi.org/10.1161/CIRCINTERVENTIONS.114.001596>
2. Abdel-Wahab M, Neumann FJ, Mehilli J, et al. 1-Year Outcomes After Transcatheter Aortic Valve Replacement With Balloon-Expandable Versus Self-Expandable Valves: Results From the CHOICE Randomized Clinical Trial. *J Am Coll Cardiol*. 2015;66:791–800.
3. Makkar RR, Fontana G, Jilaihawi H, et al. Possible Subclinical Leaflet Thrombosis in Bioprosthetic Aortic Valves. *N Engl J Med*. 2015;373:2015–2024.
4. Salinas P, Moreno R, Calvo L, et al. Long-term follow-up after transcatheter aortic valve implantation for severe aortic stenosis. *Rev Esp Cardiol*. 2016;69:37–44.
5. Mori Junco R, Domínguez Melcón F, Moreno Yangüela M. Coronary obstruction during transcatheter aortic valve replacement. *Rev Esp Cardiol*. 2015;68:893.

<http://dx.doi.org/10.1016/j.rec.2016.08.007>  
1885-5857/

© 2016 Sociedad Española de Cardiología. Published by Elsevier España, S.L.U. All rights reserved.