

and the participants that correctly diagnosed the condition (-0.09; confidence interval, -0.24 to 0.33).

There were statistically significant differences in the subjective perception of seriousness between the participants and the experts for most of the ECGs. The exceptions were the ECGs showing hypertrophic cardiomyopathy, Brugada pattern, and alternating bundle branch block (Figure).

Of note was a tracing with a QT interval of 580 ms, which received a median seriousness score of 42 (0–100) from the participants who diagnosed it correctly, compared with 72.5 (70–75) from the cardiologists.

For Wellens syndrome, the median seriousness score from the participants was 56 (20–100), while the cardiologists assigned a score of 90.

Of the bradyarrhythmias, 2 deserve comment: complete atrioventricular block and Mobitz type II second degree atrioventricular block. Complete atrioventricular block was correctly identified by just 33%, with a median seriousness score of 65 (20–100) vs 87.5 (85–90) according to the experts. Mobitz type II was correctly diagnosed by 20.2% of participants, with a median seriousness score of 40 (10–90) compared with 85 (80–90) from the cardiologists.

Figure shows how similar discrepancies occurred in the interpretation of all 10 ECG tracings.

Despite the fundamental role played by ECG in the diagnosis of cardiovascular disease, these findings demonstrate that ECG interpretation is in need of remedial action, particularly for physicians who are the first medical contact. This conclusion is in line with the findings of other available studies.³

Our study shows an extremely low percentage of correct diagnoses and poor recognition of electrocardiographic patterns in the population analyzed.

Another even more shocking finding of this study is the incorrect perception of seriousness for several potentially fatal cardiovascular conditions that are diagnosed primarily from ECG. On many occasions, these were considered harmless, highlighting

the need for training programs for such physicians on the correct interpretation of ECGs.

Juan Carlos Gómez-Polo,^{a,*} Javier Higuera Nafria,^a Pedro Martínez-Losas,^a Victoria Cañadas-Godoy,^b Ramón Bover-Freire,^c and Julián Pérez-Villacastín^b

^aServicio de Cardiología, Hospital Clínico San Carlos, Madrid, España

^bUnidad de Electrofisiología y Arritmias, Servicio de Cardiología, Hospital Clínico San Carlos, Madrid, España

^cUnidad de Insuficiencia Cardiaca, Servicio de Cardiología, Hospital Clínico San Carlos, Madrid, España

*Corresponding author:

E-mail address: jc.gomezpolo@gmail.com (J.C. Gómez-Polo).

Available online 27 October 2016

REFERENCES

- Martínez-Losas P, Higuera J, Gómez-Polo JC, Cañadas-Godoy V. The influence of clinical information in electrocardiogram interpretation. *Rev Clin Esp.* 2016; 216:171–172.
- Retana-Puigmartí M, De Frutos-Echaniz E, Castro-Acuña-Baixaui I, Val-Jimenez A. Diagnosticar un síndrome de Brugada: el papel de la atención primaria. *Semergen.* 2011;37:569–572.
- Borrás X, Murga N, Fiol M, Pedreira M. Novedades en cardiología clínica: electrocardiografía de superficie, enfermedad vascular y mujer y novedades terapéuticas. *Rev Esp Cardiol.* 2010;63(Supl 1):3–16.
- Kadish AH, Buxton AE, Kennedy HL, Knight BP, Mason JW, Schuger CD, et al. ACC/AHA clinical competence statement on electrocardiography and ambulatory electrocardiography. *Circulation.* 2001;104:3169–3178.

<http://dx.doi.org/10.1016/j.rec.2016.09.021>
1885-5857/

© 2016 Sociedad Española de Cardiología. Published by Elsevier España, S.L.U. All rights reserved.

Subacute Retrograde TAVI Migration Successfully Treated With a Valve-in-valve Procedure



Migración retrógrada subaguda de TAVI solucionada con un procedimiento valve-in-valve

To the Editor,

A 65-year-old man with severe degenerative aortic stenosis (Figures 1A and 2A) and preserved systolic function was evaluated by the Heart Team of our institution for surgical aortic valve replacement vs transcatheter aortic valve implantation (TAVI). A TAVI procedure was chosen because he had a heavily calcified aorta. He underwent a preprocedure computed tomography angiography to select the route, prosthesis type and prosthesis size for the procedure. He had no significant peripheral artery disease, and we therefore chose a transfemoral route. His aortic root area measured 430 mm² on computed tomography angiography. The aortic root diameter measured on 2-dimensional transesophageal echocardiography was 24 mm. We therefore chose an Edwards Sapien XT 26 mm valve. The TAVI procedure was undertaken (under transesophageal echocardiography) with balloon predilation, and no postdilation, without immediate complications. The balloon was prepared according to the

manufacturer's recommendations (ie, no soft preparation, by using a lower amount of balloon saline, was undertaken). Fluoroscopy (Figure 1A and Figure 1B, and video 1 and video 2 of the supplementary material), and transesophageal and transthoracic echocardiography (Figure 2A and Figure 2B, and video 3 and video 4 of the supplementary material) confirmed appropriate prosthetic positioning with a mean gradient of 9 mmHg and absence of relevant paravalvular leaks. However, 24 hours after the procedure, a follow-up transthoracic echocardiogram was performed and a de novo mean aortic gradient of 42 mmHg was revealed (Figure 2C). The prosthetic valve had migrated retrogradely into the outflow tract, thereby uncovering the native valve, which was functioning again (Figure 1C and Figure 2D, video 5 and video 6 of the supplementary material). We reviewed the case and concluded that the prosthetic valve might have been positioned slightly too low and might have suboptimally expanded during the procedure. After discussion of the case in the Heart Team, a valve-in-valve procedure with a second 26-mm Edwards Sapien XT valve was chosen (Figure 1D and video 7 of the supplementary material). This enabled successful treatment of the aortic stenosis and prevented further migration of the original prosthesis. The patient was discharged 3 days after the second procedure and at 1 year of follow-up he is free of heart failure and the prosthesis is working adequately.

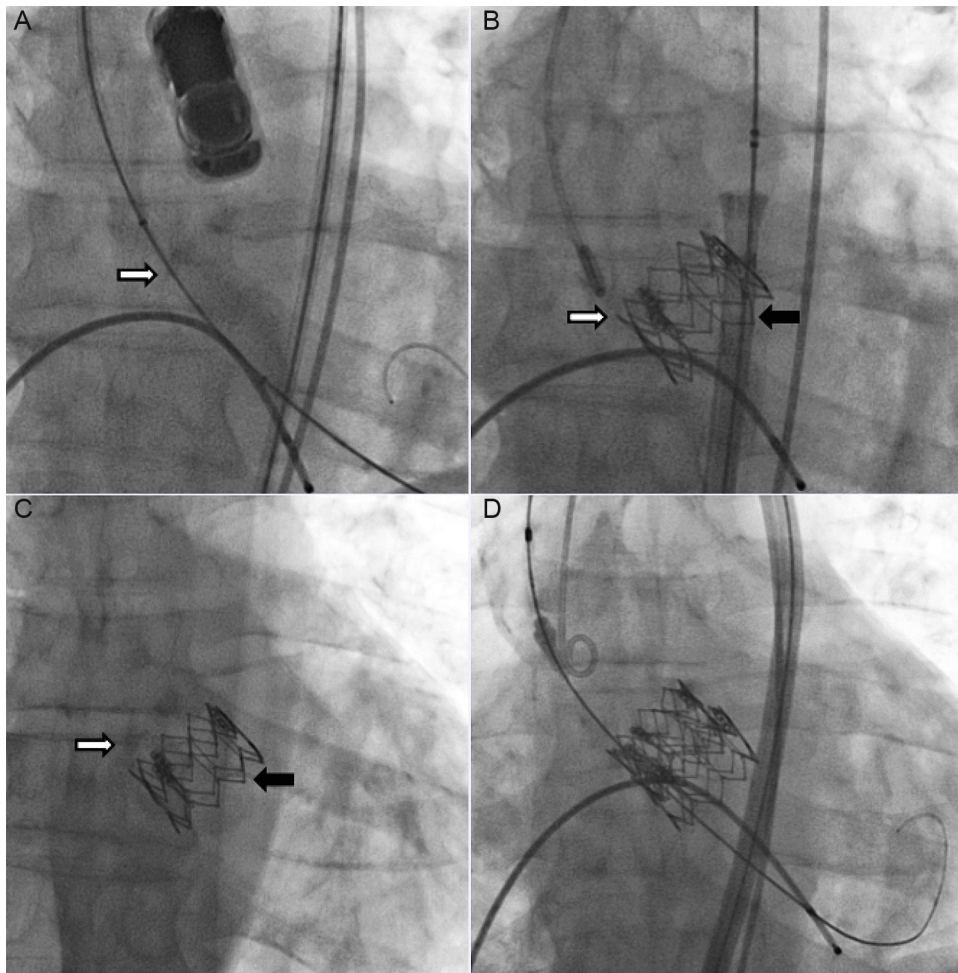


Figure 1. A, Fluoroscopy images depicting preimplantation. B, Immediate postimplantation. C, Prosthesis position following migration. D, Final result after the valve-in-valve procedure. White arrow pointing toward native valve. Black arrow pointing toward prosthesis.

Retrograde migration of the prosthetic valve following TAVI is rare. It can occur during the procedure,¹ within the first few days after the procedure² or subsequently.^{3,4} The first step in developing a solution is to identify the contributing factors for migration. These range from prosthesis malpositioning (ie, too low),¹ suboptimal valve expansion, uneven or insufficient aortic annulus calcification leading to inadequate prosthesis fixation, aortic paravalvular regurgitation, valve undersizing,⁴ and anatomical or functional bicuspid valves. In our patient, the first cause was deemed responsible for this complication, although we cannot be sure that underexpansion did not also occur. It is as important to identify the true causes of migration as it is to exclude other factors. This enables appropriate solutions to be selected and also avoids potentially damaging ones. For example, wrongly considering valve undersizing as a cause of migration may lead to the subsequent use of an oversized valve with a high risk of further damage. Additionally, the use of fully repositionable valves may reduce the risk of malposition and migration. We also speculate that direct implantation (without predilation) could reduce the risk of this complication.

Once the causes of the migration have been determined, a surgical or percutaneous approach must be quickly chosen in a Heart Team setting, as the consequences of valve migration can be catastrophic if the valve extends beyond the outflow tract into the left ventricle cavity. In the few reports describing this complication, surgery was the preferred method in almost all published cases. Indeed, we found only 1 case in which this problem was solved by a percutaneous approach,⁵ but that was a case of valve undersizing and the complication still occurred during the procedure.

While surgery was considered in this case, we believed a valve-in-valve procedure was the safest way to solve the problem because the prosthesis was not interfering with the mitral apparatus, the patient had a porcelain aorta, and the migration was a consequence of valve subexpansion and slightly low positioning. The second prosthesis would be fixed not only in the native annulus but also on the original prosthesis, thereby preventing migration of both valves. This approach seems to have been justified by the patient's favorable outcome.

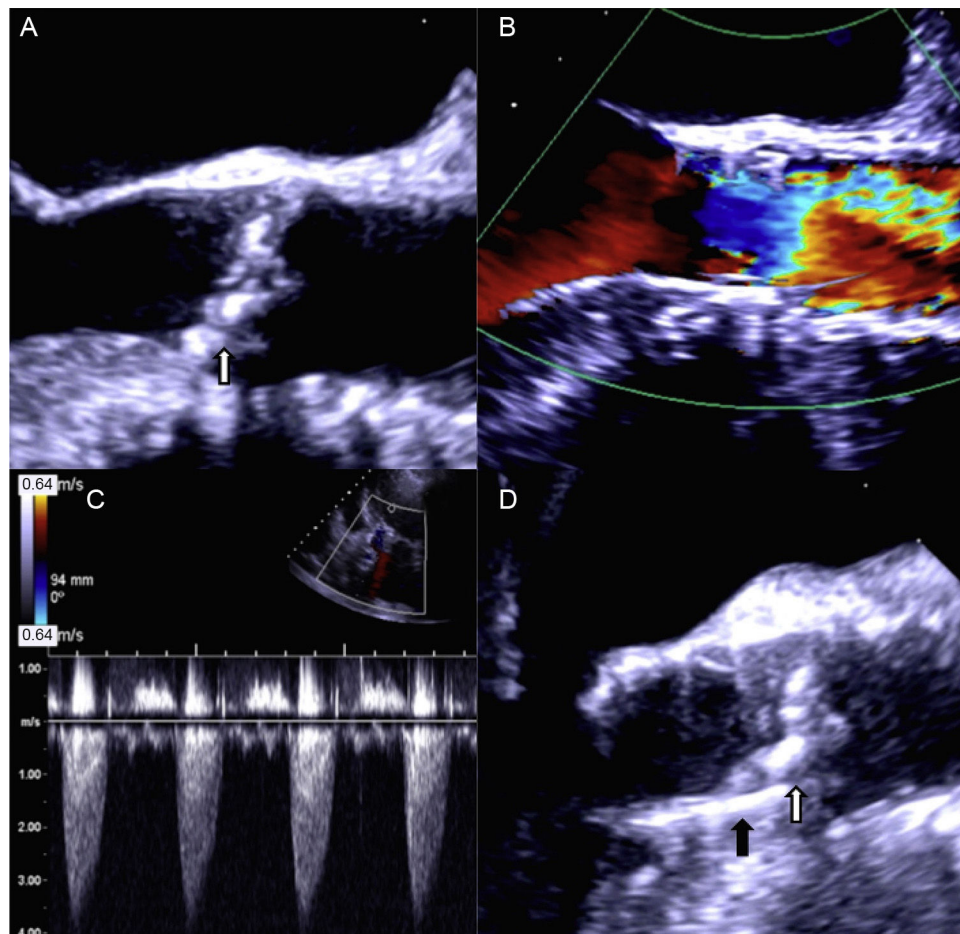


Figure 2. A, Echocardiographic images depicting preimplantation. B, Immediate postimplantation flow through prosthesis. C, Left ventricle-aorta gradient following prosthesis migration. D, Two-dimensional image of the prosthesis after migration. White arrow pointing toward native valve calcium. Black arrow pointing toward prosthesis.

SUPPLEMENTARY MATERIAL



Supplementary material associated with this article can be found in the online version available at [doi:10.1016/j.rec.2016.08.003](https://doi.org/10.1016/j.rec.2016.08.003).

Miguel Nobre Menezes,^{a,*} Pedro Canas da Silva,^a Ângelo Nobre,^b Eduardo Infante de Oliveira,^a Pedro Carrilho Ferreira,^a and Fausto J. Pinto^a

^aCardiology Department, University Hospital Santa Maria/Centro Hospitalar de Lisboa Norte/CCUL, Lisbon, Portugal

^bCardiothoracic Surgery Department, University Hospital Santa Maria/Centro Hospitalar de Lisboa Norte/CCUL, Lisbon, Portugal

* Corresponding author:

E-mail address: mnmeneses.gm@gmail.com (M. Nobre Menezes).

Available online 15 September 2016

REFERENCES

1. Cao C, Ang SC, Vallely MP, Ng M, Adams M, Wilson M. Migration of the transcatheter valve into the left ventricle. *Ann Cardiothorac Surg.* 2012;1:243–244.
2. Clavel M-A, Dumont E, Pibarot P, Doyle D, De Laroche R, Villeneuve J, et al. Severe valvular regurgitation and late prosthesis embolization after percutaneous aortic valve implantation. *Ann Thorac Surg.* 2009;87: 618–621.
3. Nkomo VT, Suri RM, Pislaru SV, Greason KL, Sinak LJ, Holmes DR, et al. Delayed transcatheter heart valve migration and failure. *JACC Cardiovasc Imaging.* 2014;7:960–962.
4. Prakash R, Crouch G, Joseph MX, Bennetts J, Selvanayagam JB, Sinhal A. Very late ventricular displacement of transcatheter aortic valve resulting in severe paravalvular regurgitation. *JACC Cardiovasc Interv.* 2014;7:e13–e15.
5. Showkathali R, Dworakowski R, MacCarthy P. Valve in valve implantation to prevent acute prosthetic valve migration in Transcatheter Aortic Valve Implantation (TAVI). *Indian Heart J.* 2015;67:598–599.

<http://dx.doi.org/10.1016/j.rec.2016.08.003>

1885-5857/

© 2016 Sociedad Española de Cardiología. Published by Elsevier España, S.L.U. All rights reserved.

Transcatheter Aortic Valve Implantation in Patients With Arterial Peripheral Vascular Disease



To the Editor,

Transcatheter aortic valve implantation (TAVI) via the transfemoral route appears to improve survival and cause fewer complications than transapical implantation. Whenever possible, the transfemoral route should therefore be the first choice.¹

Implante percutáneo transfemoral de válvula aórtica en pacientes con enfermedad arterial periférica