

# Stress Echocardiography in the Identification of Left Anterior Descending Coronary Artery Disease in Patients With Inferior Myocardial Infarction and a Positive Exercise Electrocardiography Result

Ángel M. Alonso-Gómez,<sup>a</sup> María C. Belló,<sup>a</sup> Miguel A. Fernández,<sup>a</sup> Alfonso Torres,<sup>a</sup> Maite Alfageme,<sup>a</sup> Felipe Aizpuru,<sup>b</sup> José Martínez-Ferrer,<sup>a</sup> Andrés Díaz,<sup>a</sup> and Fernando Arós<sup>a</sup>

<sup>a</sup>Servicio de Cardiología, Hospital Txagorritxu, Vitoria-Gasteiz, Álava, Spain.

<sup>b</sup>Unidad de Investigación, Hospital Txagorritxu, Vitoria-Gasteiz, Álava, Spain.

**Introduction and objectives.** In patients with an inferior myocardial infarction (IMI), ST-segment depression in left precordial leads during exercise electrocardiography (ExECG) has been associated with left anterior descending coronary artery (LADCA) disease. The aim of this study was to assess the value of stress echocardiography in identifying LADCA disease in patients with IMI and a highly abnormal ExECG result.

**Methods.** The study included patients with an IMI and an abnormal ExECG result whose coronary angiography findings were available. A highly abnormal ExECG result was defined as ST-segment depression in three or more leads, including V<sub>5</sub>. The wall motion score index was calculated and each patient was evaluated echocardiographically for ischemia in LADCA territory.

**Results.** Of 241 patients who underwent stress ECG, 100 (mean age 57 [11] years) met inclusion criteria. Some 38 had significant LADCA stenosis and, in 75, ExECG gave a highly abnormal result. The sensitivity, specificity and accuracy of a highly abnormal ExECG result for detecting LADCA disease were 74% (60%-88%), 26% (15%-37%), and 44% (34%-54%), respectively. Echocardiographic detection of ischemia had similar sensitivity, at 74%, but higher specificity, at 92% ( $P<.001$ ), and accuracy, at 85% ( $P<.001$ ). Multivariate analysis of clinical, exercise test, and stress echocardiography variables revealed that the only independent predictors of LADCA disease were age (OR=1.070), recent IMI (OR=0.136), and ischemia in LADCA territory (OR=19.9).

**Conclusions.** Stress echocardiography is a good noninvasive technique for detecting LADCA disease in patients with an IMI. The diagnostic accuracy of a highly

abnormal ExECG result is not sufficient for its use in this clinical setting.

**Key words:** Left anterior descending coronary artery. Stress echocardiography. Inferior myocardial infarction. Stress testing.

## Ecocardiografía de estrés en la detección de enfermedad de la arteria descendente anterior en pacientes con infarto de miocardio inferior y test de esfuerzo positivo

**Introducción y objetivos.** En pacientes con infarto de miocardio inferior (IMI), el descenso del segmento ST en las derivaciones precordiales izquierdas en la prueba de esfuerzo electrocardiográfica (PE-ECG) se ha asociado con enfermedad de la arteria descendente anterior (DA). El objetivo del estudio fue analizar el valor de la ecocardiografía de estrés para detectar enfermedad de la DA en pacientes con IMI y PE-ECG severamente positiva.

**Métodos.** Se seleccionó para el estudio a pacientes con IMI y una PE-ECG positiva que disponían de coronariografía. Se consideró que la PE-ECG severa era positiva si había un descenso significativo del segmento ST en  $\geq 3$  derivaciones, incluida V<sub>5</sub>. Se calculó un índice de motilidad regional (IMR) y en cada caso se definió la presencia de isquemia ecocardiográfica en el territorio de la DA (ISQ-DA).

**Resultados.** De 241 pacientes con infarto inferior que realizaron ecocardiografía de estrés se seleccionó a 100, con una edad media de  $57 \pm 11$  años. En total, 38 pacientes tenían lesión significativa de la DA y 75 presentaron una PE-ECG severamente anormal. La eficacia diagnóstica de predecir enfermedad de la DA en pacientes con PE-ECG severa alcanzó una sensibilidad del 74% (60-88), una especificidad del 26% (15-37) y una precisión diagnóstica del 44% (34-54). La ISQ-DA obtuvo una sensibilidad similar (74%), una especificidad mejor (92%;  $p < 0,001$ ) y una mayor precisión diagnóstica (85%;  $p < 0,001$ ). El análisis multivariable de variables clínicas y PE-ECG y la ecocardiografía de estrés mostraron como

SEE EDITORIAL ON PAGES 531-3

Correspondence: Dr. A.M. Alonso-Gómez.  
Pintor Vera Fajardo, 11 C, 5.º A. 01008 Vitoria-Gasteiz. Álava. España.  
E-mail: angelmago@euskalnet.net

Received August 22, 2005.

Accepted for publication March 28, 2006.

## ABBREVIATIONS

LAD: left anterior descending coronary artery.  
 DASE: dobutamine-atropine stress echocardiography.  
 SECG: stress echocardiography.  
 IMI: inferior myocardial infarction.  
 WMSI: wall motion score index.  
 EX-ECG: exercise electrocardiography.

predictores independientes únicamente la edad (*odds ratio* [OR] = 1,070), un IMI reciente (OR = 0,136) e ISQ-DA (OR = 19,9).

**Conclusiones.** La ecocardiografía de estrés es un buen método no invasivo para detectar enfermedad de la DA en el IMI. La PE-ECG severa no proporciona una precisión diagnóstica suficiente para ser utilizada con este fin en la clínica.

**Palabras clave:** Arteria descendente anterior. Ecocardiografía de estrés. Infarto de miocardio inferior. Prueba de esfuerzo.

## INTRODUCTION

Exercise electrocardiography (EX-ECG) in patients with previous myocardial infarction provides useful information that offers prognostic value and help in therapeutic decision-making.<sup>1</sup> In patients with inferior myocardial infarction (IMI), ST-segment depression in left precordial leads has been associated with multivessel disease and specifically with left anterior descending coronary artery (LAD) disease, although not all studies have confirmed this finding.<sup>2-5</sup> Stress echocardiography is a technique that makes it possible to establish with great reliability the culprit artery involved in an ischemic territory, mainly in patients with previous myocardial infarction.<sup>6,7</sup> However, few works have studied the value of stress echocardiography in detecting LAD disease in a group of patients whose exercise electrocardiographic findings indicate disease in this artery. Thus, the main aim of this study is to evaluate the role of stress echocardiography in the detection of LAD disease in a group of patients with IMI and whose exercise electrocardiographic findings indicate the presence of multivessel disease. We also studied the advantage of presenting a positive exercise electrocardiography test to identify this finding.

## METHODS

### Patient Selection

Between June 1994 and June 2001, stress echocardiography was done in 241 patients with IMI. The patients selected were those whose coronary angiography findings were available and where EX-ECG which had yielded positive outcomes. The 3 studies were done in <30 days, >70% in 1 week. Inferior myocardial infarction was diagnosed when typical pain was present, there were increases in creatine kinase (CK) and CK-MB isoenzyme (CK-MB) greater than twice the baseline and ST-segment elevation  $\geq 0.1$  mV in 2 or more lower leads. Indications for coronary angiography were made in line with the clinical criteria for our group: angina and heart failure, severe ischemia under exercise electrocardiography, and reduced ejection fraction in the echocardiographic study. Of the 100 patients who fulfilled all the criteria, 81 had presented a recent infarction (<15 days). The study design and data collection were done prospectively and all patients gave written consent to the tests.

### Exercise Electrocardiography

A peak symptom-limited treadmill test was done according to the Bruce protocol. The patients with recent IMI underwent the test 6-10 days after the acute episode. A 12-lead electrocardiogram was constantly monitored and blood pressure checked every minute during exercise and 5 min after recovery. ST-segment depression  $\geq 0.1$  mV was considered significant compared to the baseline 80 ms after the J point and present in 3 or more consecutive heart beats. The test was stopped when the following were present: angina, severe ST-segment depression, decrease in systolic blood pressure >10 mm Hg compared to the previous stage and significant arrhythmias. Severe electrocardiographic ischemia was defined when there were horizontal or downsloping ST-segment depression  $\geq 0.1$  mV in 3 or more consecutive precordial leads, one of which was always V5.

### Stress Echocardiography

Stress echocardiography was done in patients with recent IMI 24 to 72 h after EX-ECG. Two different stress echocardiography protocols were used: 25 patients underwent dobutamine-atropine stress echocardiography (DASE) and the remaining 75 patients, stress echocardiography (SECG). The basic reason for this was logistic, since at the beginning of our series no stress echocardiography infrastructure was available in our center and all the stress echocardiography studies were done with dobutamine. DASE was carried out according to

standard protocol: an initial dose of 10 µg/kg for 3 min, increasing by 10 µg/kg every 3 min until reaching a final dose of 40 µg/kg. If 85% of the theoretical maximum heart rate was not reached (220 less age in years), 1 mg atropine was injected. SECG was done via treadmill according to the Bruce protocol. Baseline images were obtained in left lateral decubitus position and those under peak stress in the first 60 s post-exercise in decubitus position, or during peak stress when this was possible.<sup>8</sup> The ECG was continuously monitored and blood pressure at every stage during exercise and 5 min after recovery. Parasternal long axis, short axis, and apical 4- and 2-chamber views were visualized and a sufficient number of heart beat sequences were recorded on video for analysis. A record was obtained of the 4 views mentioned in quad-screen format, permitting the simultaneous comparison of a cycle at baseline and at peak stress. The same stopping criteria were used in both protocols: reaching 85% of the theoretical maximum heart rate, developing echocardiographic ischemia in the LAD territory, blood pressure >220/110 mm Hg, hypotension with systolic arterial pressure <90 mm Hg, angina, dyspnea, arrhythmias, or significant side effects.

### Echocardiographic Analysis

All the echocardiographic studies were done before coronary angiography and were analyzed by an experienced observer (>1000 studies). Regional contractility was evaluated according to the recommendations of the American Society of Echocardiography: the left ventricle left was divided into 16 segments, each of which was classified according to the following: normal =1, hypokinesia =2, akinesia =3, and dyskinesia =4, and a wall motion score index (WMSI) calculated as the total score for every segment divided by the number of segments.<sup>9</sup> The test was considered positive for ischemia when any of the following findings were confirmed: a new regional anomaly in a segment with normal contractility and/or worsening in the degree of dyssynergy in a segment with baseline alterations, as long as this was not from akinesia to dyskinesia. The following were considered as LAD-dependent territory: anterior basal and medial segments, septal anterior basal and medial segments, septal lower medial segment and apical segments (septal, anterior, lateral, and lower). In each case ischemia was defined as being present in the LAD territory and in the infarcted territory.

### Coronary Angiography

This was done in all patients using the Judkin technique according to standard practice. The degree

of stenosis in each main coronary artery was estimated visually. Lesions  $\geq 70\%$  of the vessel diameter and  $\geq 50\%$  in the left main coronary artery were considered significant. The ejection fraction (EF) was determined based on the ventricular volumes calculated by the area-length method in a single plane. LAD disease was defined when disease was present in the left main coronary artery or its diameter was reduced by  $\geq 70\%$ , independently of whether the affected area was proximal, medial, or distal.

### Statistical Analysis

Continuous variables are expressed as mean  $\pm$  standard deviation (SD), once the assumption of statistical normality was validated with the Kolmogorov-Smirnov test. Discrete variables were analyzed via the absolute frequency and percent distribution of each value. The association between the dependent variable and the covariates was studied via the Student *t* test when the independent variable was continuous, and via the Fisher exact test when discrete. The variables associated ( $P < .15$ ) with the dependent variable—presence of LAD disease or otherwise—were used to build a conditional logistic model with forward selection of covariates.<sup>10</sup> The resulting goodness-of-fit of the model was assessed via the Hosmer-Lemeshow statistic.

Angiographic stenosis  $\geq 70\%$  in the LAD or the presence of stenosis  $> 50\%$  in the left main coronary artery was the reference test used in this study of the validity of diagnostic tests. Indicators of diagnostic efficacy, sensitivity, specificity, diagnostic precision, and positive and negative predictive value were calculated according to standard formulas and are presented as percentages at the 95% confidence interval (CI). The total diagnostic efficacy of the different methods studied as predictors of disease—peak WMSI, logistic models—was compared via building ROC curves and calculating the corresponding areas under the curve and their CI. *P*-values  $< .05$  was considered significant. All statistical calculations were done with the SPSS 10.0.6 package for Windows (SPSS Inc., Chicago, Ill., USA).

## RESULTS

### Selected Patients

Of the 100 patients with IMI who fulfilled the selection criteria, 91 were male. The mean age of the group was  $57 \pm 10$  years (range, 34-77 years). The patients received thrombolytic treatment in 50% of cases. All patients were treated with aspirin and 67% with beta-blockers ( $n=60$ ) or calcium antagonists

**TABLE 1. Clinical Features of Exercise Electrocardiography and Stress Echocardiography, Statistically Associated With Left Anterior Descending Coronary Artery Disease ( $P<.15$ ) in the Univariable Analysis\***

	Without LADCA Disease (n=62)	With LADCA Disease (n=38)	P
Age, mean±SD, y	54±9	61±9	<.0005
Recent myocardial infarction	59 (95)	22 (58)	<.0005
Thrombolysis	36 (58)	14 (37)	.063
Beta-blockers with stress echocardiography	43 (69)	17 (44)	.021
Angiographic EF, %	52.9±8	55.7±9	.146
MET in EX-ECG	7.4±2	6.6±2	.074
Maximal HR EX-ECG	117±17	111±19	.123
ST-segment increase in infarcted wall	30 (48)	9 (24)	.020
Angina in stress echocardiography	2 (3)	7 (18)	.025
MET in stress echocardiography	8.5±2	7.2±2	.011
WMSI under maximal stress	1.59±0.2	1.83±0.3	<.0005
Ischemia in the LADCA territory	5 (8)	28 (73)	<.0005

\*LADCA indicates left anterior descending coronary artery; HR, heart rate; EF, ejection fraction; WMSI, wall motion score index; MET, number of metabolic equivalents; BP, blood pressure; EX-ECG, exercise electrocardiography.

Values are expressed as number of cases and percentage in relation to the reference number.

**TABLE 2. Diagnostic Efficiency Parameters of Severe EX-ECG and Stress Echocardiography Calculated From the 2x2 Tables Displayed\***

	With LADCA Disease (n=38)	Without LADCA Disease (n=62)
Severe positive EX-ECG	TP=28	FP=46
Severe negative EX-ECG	FN=10	TN=16
Positive stress echocardiography	TP=28	FP=5
Negative stress echocardiography	FN=10	TN=57

\*LADCA indicates left anterior descending coronary artery; FN, false negative; FP, false positive; EX-ECG, exercise electrocardiography; TN, true negative; VP, true positive.

(n=7). The mean ejection fraction for the group was 55±9%; ejection fraction was ≤45% in 13 patients. Coronary angiography demonstrated left main coronary artery disease in 6 patients, 3-vessel disease in 20, 2-vessel disease in 26 and single-vessel disease in 48. There was significant LAD disease in 38 cases (6 left main coronary arteries, 20 in three vessels, 8 anterior descending and right coronary artery, 3 anterior descending and circumflex artery, and 1 isolated anterior descending artery disease).

### Exercise Electrocardiography

The number of metabolic equivalents (MET) and the peak heart rate (HR) were somewhat greater in the group without LADCA disease (Table 1), probably because the treated patients were younger, since the percentage above the theoretical peak HR

was similar (70±10 vs 70±11;  $P=.806$ ). The presence of angina during the test (9/62 vs 6/38;  $P=.539$ ) or of severe electrocardiographic alterations (46/62 vs 28/38;  $P=.567$ ) was not used to differentiate one group from the other. When the diagnostic efficacy was analyzed of presenting an electrocardiographic pattern of severe ischemia to detect LAD disease (Table 2) the following were obtained: sensitivity, 74% (60-88); specificity, 26% (15-37); diagnostic precision, 44% (34-54); positive predictive value, 38% (27-49); and negative predictive value, 62% (43-80).

### Stress Echocardiography

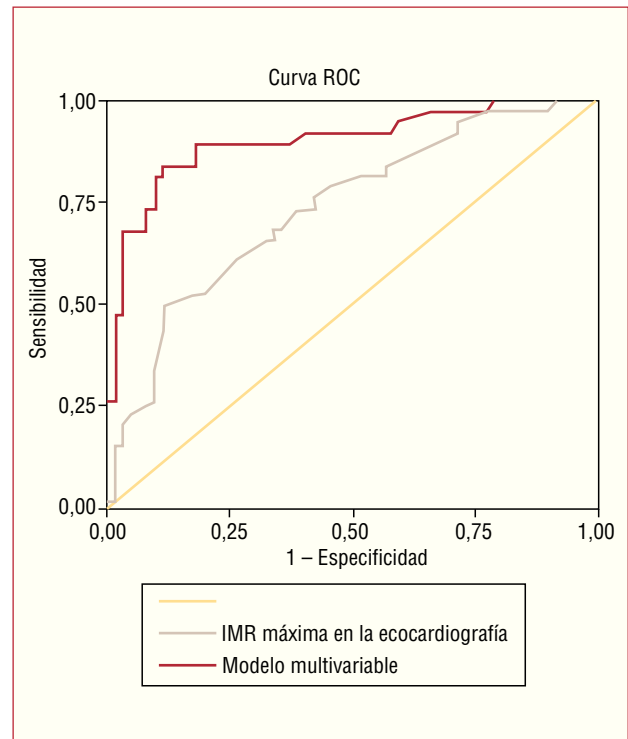
No major complications occurred during the SECG studies. A maximum dose of 38±6 µg/kg dobutamine was achieved in the 25 patients undergoing DASE and atropine was used in nine cases. There were ventricular arrhythmias in 5 patients and minor side effects in 6. Reasons to end the test were: completing the protocol in 14 patients, echocardiographic anomalies in 8, ventricular arrhythmias in 2, and angina in 1. The 75 patients who underwent SECG achieved external work of 8±2 MET, 8 patients had angina; 2, ventricular arrhythmias and 1, bouts of supraventricular tachycardia. The leading causes for ending the test were muscular exhaustion in 37 cases, positive echocardiograph in 14, dyspnea in 12, achieving 85% of the submaximal HR in 4, hypotension in 2, claudication of the lower limbs in 2, angina in one and other causes in 3. There was a higher proportion of individuals who underwent SECG among the 60 patients who carried out the test while under the effect of beta-blockers (51/75 vs 9/25;  $P=.008$ ).

## Left Anterior Descending Coronary Artery Disease and Stress Echocardiography

Although the patients with LAD disease underwent more pharmacological than stress echocardiographies, this difference was not significant (12/38 vs 13/62;  $P=.170$ ). The peak HR ( $118\pm 21$  vs  $114\pm 23$  beat/min;  $P=.432$ ), maximum BP ( $149\pm 22$  vs  $148\pm 29$  mm Hg;  $P=.898$ ) and baseline WMSI ( $1.38\pm 0.2$  vs  $1.45\pm 0.3$ ;  $P=.210$ ) were similar in patients with and without LAC disease. Logically, WMSI under peak stress was higher in the patients with stenosed left anterior descending coronary artery (Table 1), since they presented ischemia in this territory more frequently. The proportion of echocardiographic ischemia in the infarct territory was similar (48/62 vs 29/38;  $P=.542$ ). When the diagnostic efficacy of presenting an echocardiographic pattern of ischemia in the LAC territory to detect LAC disease (Table 2) was analyzed, it yielded a sensitivity of 74% (60-88), specificity of 92% (85-99), diagnostic precision of 85% (78-92), positive predictive value of 85% (73-97), and negative predictive value of 85% (77-94). In relation to the diagnostic efficacy of severe EX-ECG findings, echocardiography was similar regarding sensitivity (74% vs 74%), but much higher regarding specificity (92% vs 26%;  $P<.001$ ) and diagnostic precision (85% vs 44%;  $P<.001$ ).

## Predicting Left Anterior Descending Coronary Artery Disease

Table 1 shows the variables associated with the presence of LAC disease in the univariate analysis with a statistical significance  $<.15$ . Among the clinical variables, age and the fact that the infarction was recent achieved the highest significance ( $P<.0005$ ). Among those related to EX-ECG, the ST-segment elevation in the lower leads was associated with a smaller probability of the LAC being affected ( $P=.020$ ). Logically, in the case of stress echocardiography, ischemia in the LAC territory and WMSI at peak stress were the variables that more strongly correlated with the lesions in the anterior interventricular artery ( $P<.0005$ ). Only the variables that reached a value of  $P<.15$  in the univariate analysis were used in the logistic regression analysis. A logistic regression model which included the variables age, recent myocardial infarction and echocardiographic ischemia in the LAC territory was the one that better predicted the association of IMI and LAC disease. The Hosmer-Lemeshow statistic ( $H-L=4.9$ ;  $P=.763$ ) showed the model had a good fit regarding the distribution of the data series studied. Table 3 shows the odds ratio (OR) for each variable, their 95% confidence intervals (CI) and the level of statistical significance. The predictive capacity of this



**Figure.** Receiver operating characteristic curve comparing the proposed multivariable model and the wall motion score index to predict left anterior descending coronary artery disease in inferior myocardial infarction.

multivariable analysis model was compared with the use of a single parameter of stress echocardiography, strongly associated with the presence of LAC disease, peak stress WMSI, via comparison of the ROC curves (Figure). The area under the curve of the multivariable model was 0.903 (95% CI, 0.84-0.97), whereas the maximum of the variable WMSI was 0.740 (0.64-0.84).

## DISCUSSION

The results of our study demonstrate that the presence of ST-segment depression in the left precordial leads is of no value in detecting significant LAC disease in patients with IMI, even when severe depression criteria are fulfilled. Our findings do not coincide with reports by Khoury et al,<sup>4</sup> who found

**TABLE 3. Multivariate Analysis\***

	Odds ratio	95% CI	P
Age	1.070	1.004-1.141	.038
Recent myocardial infarction	0.136	0.26-0.703	.017
Ischemia in the LADCA territory	19.975	5.738-69.532	.000

\*LADCA indicates left anterior descending coronary artery. Dependent variable: LADCA disease (yes/no).

82% of LAC disease in patients with IMI and ST-segment depression in V5-V6, which is much higher than that found by other authors.<sup>5</sup> The high prevalence of LAC disease in the total group (58%) and the high frequency of postinfarction angina indicates an obvious selection bias, and thus we agree that it does not represent the general population of patients with inferior myocardial infarction. In the study by González Vílchez et al,<sup>5</sup> the patients with ST-segment depression in V5-6 and V1-6 had a higher prevalence of LAC disease (35% and 50%) and logistic regression analysis demonstrated that these patterns and age serve to predict multivessel disease. In fact, their results regarding detection of LAC disease are as poor as ours, since the positive predictive values of patterns III (ST-segment depression in V5 and V6) and IV (ST-segment depression from V1 to V6) were 35% and 50%, similar to the 38% (27/49) we found. It seems clear that a strategy to locate LAC disease with a diagnostic precision of 44% cannot be applied in daily practice. In fact, there are few recent publications in this regard and the efforts of researchers are focused on the usefulness of ECG in the acute phase of inferior myocardial infarction to detect LAC disease.<sup>11</sup>

### **Stress Echocardiography and Left Anterior Descending Coronary Artery Disease**

Stress echocardiography helps to identify the culprit artery involved in the ischemic territory<sup>12</sup> and has been used for this purpose in patients with multivessel disease.<sup>13,14</sup> In our study, the presence of an echocardiographic pattern of ischemia in the LAC territory detected LAC disease with an 84% diagnostic precision, which makes it possible to use this parameter for decision-making in daily clinical practice. The sensitivity of 74% is less than that obtained by Peteiro et al<sup>14</sup> in patients with multivessel disease, partly because the test carried out in our group achieved a smaller maximal HR and/or 60% were done while patients were under the effects of beta-blockers. There were 5 false positives in our study, partly because disease in a very dominant right coronary artery can cause irrigation in the apex and partly because lesions that, from the angiographic standpoint, did not reach a 70% threshold (which occurred in 3 cases with stenosis reported as <50% in 2 and 50% in 1) could have a functional impact on blood flow.

### **Predicting Left Anterior Descending Coronary Artery Disease**

Age, ischemia in the LAC territory under stress echocardiography and the presence of recent IMI as a protective parameter were the only independent

predictors in the multivariate analysis. Age is a risk factor linked to greater extension of coronary disease,<sup>15</sup> since there is a longer exposure to risk factors and a greater number of events, and thus there would be more LAC disease in the older group. The most important predictor was ischemia in the LAC territory, since is the functional consequence of the anatomical lesion. Although previous studies have found an association between WMSI and multivessel disease,<sup>7,14,16</sup> it is noteworthy that this was not an independent predictor of LAC disease in our study, which is reasonable, since maximal WMSI can be high due to an ischemia induced in the infarcted territory or the circumflex artery. In fact, the presence of ischemic disorder in a distant area as a main predictor of multivessel disease is also a regular finding in all these studies. The fact that the area under the curve in our model is 0.903 versus 0.740 supports the clear superiority of the echocardiographic parameter of ischemia in the LAC territory over the WMSI.

### **Clinical Implications**

In patients with IMI and positive Ex-ECG, having a strategy that helps identify patients with LAC disease is of great importance because, in this case, coronary angiography and, possibly, a revascularization procedure is indicated, since the prognosis of IMI with multivessel disease is worse.<sup>17</sup> The systematic substitution of EX-ECG for stress echocardiography for prognostic stratification after an infarction is not justified, since conventional EX-ECG detects a large number of patients without poor prognosis.<sup>5</sup> Furthermore, at least currently, the availability, cost, and the need for experienced personnel to carry out stress echocardiography are more pressing issues. However, if multivessel disease needs to be detected with greater sensitivity and negative predictive value, a strategy that includes stress echocardiography is obligatory.<sup>14,17</sup> Although some authors have found that this strategy does not have an impact on predicting events,<sup>18</sup> others have in fact obtained positive results in this regard.<sup>19</sup> It has recently been verified that the location of ischemia in the LAC territory has an independent prognostic value in patients with and without previous infarction.<sup>20</sup>

### **Limitations**

There is a bias in patient selection, due to only selecting those who had undergone coronary angiography (in almost all patients who did not undergo this, this was due to the fact that they were asymptomatic and had a negative exercise electrocardiography), but these patients are in fact those in whom it is necessary to improve clinical decision-making.

We do not think that using 2 different techniques in stress echocardiography had an influence on the results, since the clinical usefulness of stress and pharmacological echocardiography in detecting LAC disease is similar,<sup>21</sup> whenever certain conditions are met, such as when DASE is done with atropine and the vessel lesions under study are really significant<sup>22</sup>; both circumstances were fulfilled in our study. Stress echocardiography is a technique highly dependent on the operator with a subjective quantification method, but its clinical use is justified when an experienced operator is available.<sup>23,24</sup> Furthermore, it has been shown that stress echocardiography more easily detects LAC disease than disease in the right coronary right or circumflex artery.<sup>20</sup>

The use of a non-quantitative method for assessing the degree of coronary stenosis could have modified the number of patients with LAC disease and changed the number of false positives or false negatives. Neither was the morphology of the lesion taken into account, which can play an important role in triggering myocardial ischemia. Given that the number of patients with non-recent IMI is low and the model we propose includes recent infarction, these findings should be interpreted with caution in this subgroup of patients.

## CONCLUSIONS

The identification of LAC disease in patients with IMI, in most cases, determines the course of coronary angiography and, possibly, a revascularization procedure. Our findings have confirmed that the use of EX-ECG, even when severity criteria are fulfilled, does not provide sufficient accuracy in the detection of LAC disease as to be used in clinical practice. Stress echocardiography is a good non-invasive method to detect LAC disease after an IMI and, given its high specificity, is an excellent tool to use in case of positive exercise electrocardiography.

## REFERENCES

1. van de Werf F, Ardissino D, Betriu A, Cokkinos DV, Falk E, Fox KA et al. Management of acute myocardial infarction in patients presenting with ST-segment elevation. The Task Force on the Management of Acute Myocardial Infarction of the European Society of Cardiology. *Eur Heart J*. 2003;24:28-66.
2. Kataoka H, Ohkubo T, Nakamura K, Hashimoto S. Exercise-induced precordial ST-segment depression in prior myocardial infarction with single-vessel disease: with special reference to its mechanisms and distinction from multi-vessel disease. *Int J Cardiol*. 1988;18:223-41.
3. Hosoya Y, Ikeda K, Yamaki M, Iuiki K, Yasui S. The clinical significance of exercise-induced ST segment changes in patients

with previous inferior myocardial infarction. *Am Heart J*. 1990;120:554-61.

4. Khoury Z, Keren A, Stern S. Correlation of exercise-induced ST depression in precordial electrocardiographic leads after inferior wall acute myocardial infarction with thallium-201 stress scintigraphy, coronary angiography and two-dimensional echocardiography. *Am J Cardiol*. 1994;73:868-71.
5. González Vilchez F, Tellez García J, Pérez Villoria J, Fernández Almeida A, Rodríguez Alonso A, Ayuela Azcarate J. Correlación angiográfica del descenso del segmento ST con el ejercicio en derivaciones precordiales después de un infarto agudo de miocardio inferior. *Rev Esp Cardiol*. 1997;50:331-6.
6. Roger VL, Pellikka PA, Oh JK, Bailey KR, Tajik AJ. Identification of multivessel coronary artery disease by exercise echocardiography. *J Am Coll Cardiol*. 1994;24:109-14.
7. Smart SC, Knickelbine T, Stoiber TR, Carlos M, Wynsen JC, Sagar KB. Safety and accuracy of dobutamine-atropine stress echocardiography for the detection of residual stenosis of the infarct-related artery and multivessel disease during the first week after acute myocardial infarction. *Circulation*. 1997;95:1391-401.
8. Peteiro J, Fabregas R, Monserrat L, Álvarez N, Castro-Beiras A. Comparison of treadmill exercise echocardiography before and after exercise in the evaluation of patients with known or suspected coronary artery disease. *J Am Soc Echocardiogr*. 1999;12:1073-9.
9. Schiller NB, Shah PM, Crawford M, deMaria A, Devereux R, Feigenbaum H, et al. Recommendations for quantitation of the left ventricle by two-dimensional echocardiography. (American Society of Echocardiography Committee on Standards, Subcommittee on Quantitation of Two-dimensional Echocardiograms). *J Am Soc Echocardiogr*. 1989;2:358-67.
10. Hosmer DW, Lemeshow S. Applied logistic regression. New York: John Wiley & Sons; 1989. p. 82-106.
11. Mager A, Sclarovsky S, Herz I, Adler Y, Strasberg B, Birnbaum Y. Value of the initial electrocardiogram in patients with inferior-wall acute myocardial infarction for prediction of multivessel coronary artery disease. *Coron Artery Dis*. 2000;11:415-20.
12. Arós F, Boraita A, Alegría E, Alonso AM, Bardaji A, Lamiel R, et al. Guías de práctica clínica de la Sociedad Española de Cardiología en pruebas de esfuerzo. *Rev Esp Cardiol*. 2000;53:1063-94.
13. Lancellotti P, Benoit T, Rigo P, Pierard LA. Dobutamine stress echocardiography versus quantitative technetium-99m sestamibi SPECT for detecting residual stenosis and multivessel disease after myocardial infarction. *Heart*. 2001;86:510-5.
14. Peteiro J, Monserrat L, Pérez R, Vázquez E, Vázquez JM, Castro-Beiras A. Accuracy of peak treadmill exercise echocardiography to detect multivessel coronary artery disease: comparison with post-exercise echocardiography. *Eur J Echocardiogr*. 2003;4:182-90.
15. Anderson KM, Odell PM, Wilson PW, Kannel WB. Cardiovascular disease risk profiles. *Am Heart J*. 1991;121:293-8.
16. Senior R, Khattar R, Lahiri A. Value of dobutamine stress echocardiography for the detection of multivessel coronary artery disease. *Am J Cardiol*. 1998;81:298-301.
17. Bigi R, Galati A, Curti G, Coletta C, Barlera S, Partesana N, et al. Prognostic value of residual ischemia assessed by exercise electrocardiography and dobutamine stress echocardiography in low-risk patients following acute myocardial infarction. *Eur Heart J*. 1997;18:1873-81.
18. Peteiro J, Monserrat L, Vázquez E, Pérez R, Garrido I, Vázquez N, et al. Comparison of exercise echocardiography to exercise electrocardiographic testing added to echocardiography at rest to risk stratification after uncomplicated acute myocardial infarction. *Am J Cardiol*. 2003;92:373-6.
19. Bigi R, Desideri A, Galati A, Bax JJ, Coletta C, Fiorentini C, et al. Incremental prognostic value of stress echocardiography as an adjunct to exercise electrocardiography after uncomplicated myocardial infarction. *Heart*. 2001;85:417-23.

20. Elhendy A, Mahoney DW, Khandheria BK, Paterick TE, Burger KN, Pellikka PA. Prognostic significance of the location of wall motion abnormalities during exercise echocardiography. *J Am Coll Cardiol.* 2002;40:1623-9.
21. Cohen JL, Ottenweller JE, George AK, Duvvuri S. Comparison of dobutamine and exercise echocardiography for detecting coronary artery disease. *Am J Cardiol.* 1993;72:1226-31.
22. Tousoulis D, Rallidis L, Cokkinos P, Davies G, Nihoyannopoulos P. Relation between exercise and dobutamine stress-induced wall motion abnormalities and severity and location of stenosis in single-vessel coronary artery disease. *Am Heart J.* 1999;138:873-9.
23. Makan M, Pérez JE. Perspectivas sobre la utilización de las modalidades de imagen de estrés en la valoración inicial de la cardiopatía isquémica. *Rev Esp Cardiol.* 2003;56:1010-5.
24. Peteiro-Vázquez J, Monserrat-Iglesias L, Marinas-Davila J, Garrido-Bravo IP, Bouzas-Caamano M, Muniz-García J, et al. Valor pronóstico de la ecocardiografía de ejercicio en cinta rodante. *Rev Esp Cardiol.* 2005;58:924-33.