

Nonetheless, we did not find any studies in the literature that systematically perform this technique using peripheral access.

In conclusion, UF in patients with decompensated HF and congestion resistant to combined diuretic therapy is effective, safe, and simple to perform on a conventional hospital ward and using peripheral venous access.

## FUNDING

None.

## AUTHORS' CONTRIBUTIONS

All the authors involved in the study have made substantial contributions, collaborated on the writing or critical review of the article, have reviewed and approved the final version, and agree with all aspects of the study to ensure that questions related to the accuracy or integrity of any part of this study may be investigated and resolved appropriately.

R. López-Vilella: study design, performing the study, data collection, data analysis, manuscript writing, manuscript review. I. Sánchez-Lázaro: study design, performing the study, data collection, data analysis, manuscript review. B. Guerrero Cervera: study design, performing the study, data collection, data analysis, manuscript writing. V. Donoso Trenado: study design, performing the study, data collection, data analysis, manuscript writing. A. Soldevila Orient: data analysis, manuscript writing, manuscript review. L. Almenar Bonet: study design, performing the study, data collection, data analysis, writing the manuscript, manuscript review.

## CONFLICTS OF INTEREST

None.

Aleksandra Mas-Stachurska,<sup>a,b,c,d,\*</sup> Berto J. Bouma,<sup>e</sup> Rianne de Bruin Bon,<sup>e</sup> Barbara Mulder,<sup>e</sup> Bart Bijlens,<sup>c,f</sup> and Marta Sitges<sup>a,b,c,g,h</sup>

<sup>a</sup>Institut Clínic Cardiovascular, Hospital Clínic de Barcelona, Barcelona, Spain

<sup>b</sup>Departamento de Medicina, Universitat de Barcelona, Barcelona, Spain

<sup>c</sup>Institut d'Investigacions Biomèdiques August Pi i Sunyer (IDIBAPS), Barcelona, Spain

<sup>d</sup>Institut Hospital del Mar d'Investigacions Mèdiques (IMIM), Barcelona, Spain

<sup>e</sup>Cardiology Department, Amsterdam University Medical Centers, Location Academisch Medisch Centrum, Amsterdam, Países Bajos

<sup>f</sup>Institució Catalana de Investigació y Estudios Avanzados (ICREA), Barcelona, Spain

<sup>g</sup>Centro de Investigación Biomédica en Red de Enfermedades Cardiovasculares (CIBERCV), Spain

<sup>h</sup>Centres de Recerca de Catalunya (CERCA), Generalitat de Catalunya, Barcelona, Spain

\* Corresponding author:

E-mail address: [astachur@gmail.com](mailto:astachur@gmail.com) (A. Mas-Stachurska).

Available online 3 June 2022

## REFERENCES

1. Costanzo MR, Guglin ME, Saltzberg MT, et al. Ultrafiltration versus intravenous diuretics for patients hospitalized for acute decompensated heart failure. *J Am Coll Cardiol.* 2007;49:675–683.
2. Bart BA. Treatment of congestion in congestive heart failure: Ultrafiltration is the only rational initial Treatment of volume overload in decompensated heart failure. *Circ Hear Fail.* 2009;2:499–504.
3. Kazory A. Ultrafiltration therapy for heart failure: Balancing likely benefits against possible risks. *Clin J Am Soc Nephrol.* 2016;11:1463–1471.
4. Costanzo MR, Ronco C, Abraham WT, et al. Extracorporeal ultrafiltration for fluid overload in heart failure: current status and prospects for further research. *J Am Coll Cardiol.* 2017;69:2428–2445.
5. ter Maaten JM, Valente MA, Damman K, Hillege HL, Navis G, Voors AA. Diuretic response in acute heart failure-pathophysiology, evaluation, and therapy. *Nat Rev Cardiol.* 2015;12:184–192.
6. Felker GM, Mentz RJ. Diuretics and ultrafiltration in acute decompensated heart failure. *J Am Coll Cardiol.* 2012;59:2145–2153.

<https://doi.org/10.1016/j.rec.2022.04.013>  
1885-5857/

© 2022 Sociedad Española de Cardiología. Published by Elsevier España, S.L.U. All rights reserved.

## Specific electrocardiographic findings in patients with pectus excavatum



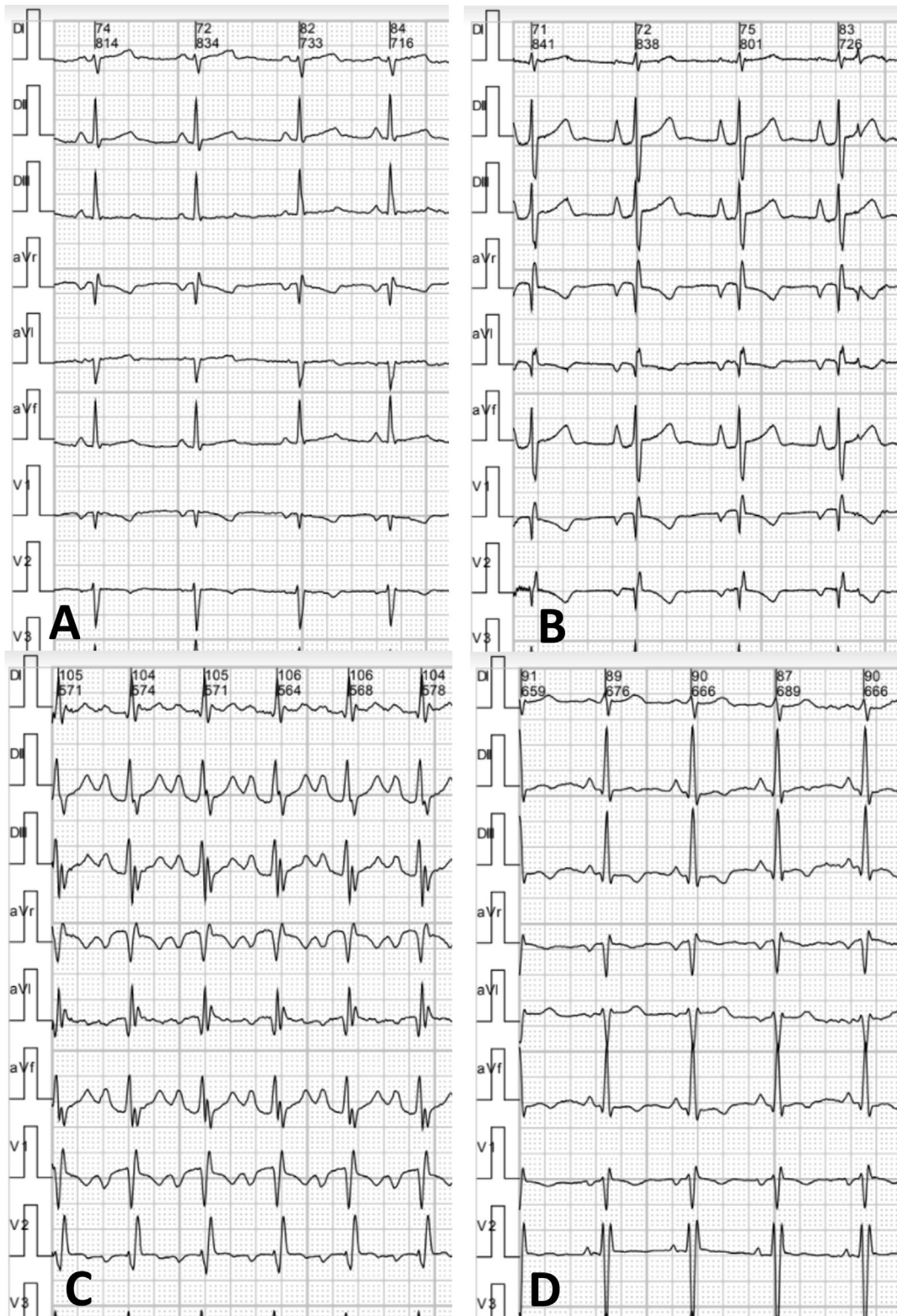
## Hallazgos electrocardiográficos específicos en pacientes con pectus excavatum

### To the Editor,

Pectus excavatum (PE) was previously considered to be a relatively common esthetic malformation; however, in the past decade it has been acknowledged to potentially affect cardiac function due to external compression on the right chambers of the heart.<sup>1</sup> The protocol used for risk stratification and to assess preoperative eligibility usually includes functional heart studies such as exercise stress echocardiography (ESE).<sup>2</sup> Electrocardiography (ECG) performed during ESE, using 12 thoracic leads, is often the only test available for these patients. However, there is scant information on its characteristics. Our aim was to analyze the ECG characteristics of patients with PE who underwent ESE as part of an eligibility assessment prior to surgery.

This retrospective, cross-sectional, observational study included patients diagnosed with PE who were assessed at an institution specializing in thoracic wall malformations and who had an indication for ESE to evaluate eligibility for a specific treatment. Patients were excluded if their ECG information was incomplete or of poor quality, if they had known lung or cardiovascular conditions, if there was a history of prior thoracic surgery, if they were currently receiving vacuum bell therapy, or if they did not grant informed consent for the use of their data (*habeas data*). The control group comprised young healthy participants with medical evaluations prior to participating in recreational amateur sports who showed no evidence of heart disease or thoracic malformations and who underwent ESE based on the same methodology as the PE patients. All procedures complied with the ethical standards of the teaching and research committee and with the Declaration of Helsinki of 1964 and its subsequent addenda. All patients underwent ESE using a bicycle in the supine position, based on a modified Astrand protocol.

The ECG analysis was performed by an experienced cardiologist blinded to the patients' clinical characteristics and the results of



**Figure 1.** A, normal tracing. B, “Eiffel tower” P waves and PR interval of 180 ms. C, “Eiffel tower” P waves, PR interval of 200 ms and right bundle-branch block. D, “Eiffel tower” P waves, with negative T wave in inferior aspect and right bundle-branch block.

**Table 1**  
Demographic data and thoracic electrocardiography findings in patients with pectus excavatum and in the control group

	PE (n=80)	Control (n=31)	P
<i>Demographic data</i>			
Age, y	17.2 ± 6.6	20.7 ± 6.0	.02
Men	75 (94)	19 (61)	<.0001
<i>Electrocardiography results</i>			
Ectopic atrial rhythm	3 (4)	1 (3)	.89
Heart rate, bpm	83.2 ± 14.0	84.6 ± 15.2	.65
PR, ms	156.0 ± 15.6	148.1 ± 18.9	.03
Frontal P axis, °	59.6 ± 16.4	60.0 ± 16.5	.91
Frontal P voltage, mm	1.94 ± 0.6	1.68 ± 0.5	.03
P duration, ms	89.4 ± 8.9	87.7 ± 9.2	.39
“Eiffel tower” P waves	53 (66)	4 (13)	<.0001
QRS, ms	92.1 ± 13.2	95.8 ± 14.8	.21
Frontal axis, °	72.4 ± 21.8	67.1 ± 20.4	.25
RV hypertrophy	3 (4)	1 (3)	.15
<i>Blocks</i>			.050
RBBB	26 (33%)	4 (13%)	
LAFB	0	1 (3%)	
RBBB+LAFB	1 (1%)	0	
LBBB	0	0	
<i>ST segment</i>			.75
Early repolarization	8 (10)	2 (7)	
Inferior ST-segment depression	1 (1)	0	
Precordial ST-segment depression	0	0	
Precordial and inferior ST segment	1 (1)	1 (3)	
<i>T wave</i>			.008
Abnormal FP	5 (6)	0	
Abnormal HP	0	0	0
Abnormal FP and HP	0	3	
Frontal T-wave axis, °	47.9 ± 21.6	50.7 ± 16.9	.52

FP, frontal plane; HP, horizontal plane; LAFB, left anterior fascicular block; LBBB, left bundle-branch block; P, P wave; PE, pectus excavatum; PR, duration of the PR interval; QRS, QRS complex; RBBB, right bundle-branch block; RV, right ventricle.

their other studies. The following parameters were analyzed: type of heart rhythm, heart rate, PR interval duration, axis, P-wave voltage and duration, prevalence of an “Eiffel tower” P-wave morphology (figure 1), defined as voltage > 2 mm, peaked shape with a narrow base (duration < 90 ms), QRS complex duration and axis in frontal plane, signs of right ventricular hypertrophy, presence and type of conduction disorder, presence and type of ventricular repolarization impairment as per conventional criteria, and frontal axis of T wave.

Between August 2012 and May 2018, 326 patients were diagnosed with PE on ESE at our hospital; 80 of these patients were included in the study, based on the inclusion and exclusion criteria (mean age, 17.2 ± 6.6 y). The control group included 31 participants (mean age, 20.7 ± 6.0 y). Patients with PE showed higher P-wave voltage in thoracic lead II (1.94 ± 0.6 vs 1.68 ± 0.5 mm; *P* = .03). Patients with PE showed a high prevalence of “Eiffel tower” P waves (PE vs control, 66% vs 13%; *P* < .0001), longer PR interval (156.0 ± 15.6 vs 148.1 ± 18.9 ms; *P* = .03), and higher prevalence of right bundle-branch block (34% vs 13%; *P* = .05). While no patients exhibited ST-segment downsloping, some did show abnormal T waves, specifically negative waves in thoracic leads II, III, and aVF (6% vs 0%; *P* = .008). Table 1 contains a detailed analysis of the electrocardiographic findings.

Regarding echocardiography variables, PE patients with “Eiffel tower” P waves had lower tricuspid annular plane systolic excursion (TAPSE, 18.8 ± 4.5 vs 21.6 ± 4.6 mm; *P* = .012), smaller tricuspid annulus diameter (10.0 ± 4.9 vs 13.3 ± 6.2 mm/m<sup>2</sup>;

*P* = .010), and a higher prevalence of paradoxical septal motion (79% vs 56%; *P* = .027) and diastolic dysfunction during exertion (59% vs 33%; *P* = .033) than those with normal P waves.

This study identified distinctive electrocardiography findings for PE patients, such as greater voltage and morphological P-wave abnormalities, longer PR intervals, and prevalence of right bundle-branch block and T-wave abnormalities in the inferior leads.

In addition to higher voltage, 66% of PE patients had peaked P-wave morphology with a narrow base in thoracic lead II (“Eiffel tower” P wave). Although the causes were not analyzed, the increased voltage and the P-wave morphology at least indicate functional impairment, presumably as a result of compression caused by the thoracic deformation. Compared with patients with PE and normal P waves, those who had “Eiffel tower” P waves had reduced right ventricular systolic function, extrinsic compression of the atrioventricular groove, and a higher prevalence of indicators of impaired ventricular filling.

Nevertheless, although its prevalence was low, the identification of negative T waves in inferior thoracic leads could indicate underlying right ventricular function impairment.<sup>3</sup>

Electrocardiographic tracing from multiple locations of the thorax has been studied in various situations.<sup>4,5</sup> In our setting, thoracic ECG obtained during ESE was often the only ECG available for PE patients other than ECG performed as part of a preoperative assessment.

The electrocardiographic abnormalities described may have multifactorial underlying mechanisms, and it is difficult to

attribute these abnormalities to a specific variable.<sup>6</sup> Prospective studies such as standard ECG should be undertaken to corroborate our findings.

As a limitation, demographic differences in sex and age could affect the results when comparing the control group with the PE patients.

In conclusion, PE patients often exhibit greater voltage and peaked “Eiffel tower” P-wave morphology, longer PR intervals, and higher prevalence of right bundle-branch block and negative T waves in inferior leads compared with a control group. Therefore, ECG could be an affordable and widely available tool for detecting potential cardiovascular conditions in PE patients.

## FUNDING

This study received no funding.

## AUTHORS' CONTRIBUTIONS

C.A. Ingino: concept and design, data analysis, and interpretation; writing of the article; final approval; acceptance of responsibility for all aspects of the article and for researching and resolving any issue regarding the accuracy and truthfulness of any part of the study. I. Raggio: data collection, analysis, and interpretation; critical review of the intellectual content; final approval; acceptance of responsibility for all aspects of the article and for researching and resolving any issue regarding the accuracy and truthfulness of any part of the study. L. Toselli: data collection; critical review of the intellectual content; final approval; acceptance of responsibility for all aspects of the article and for researching and resolving any issue regarding the accuracy and truthfulness of any part of the study. J. Farina: data collection, critical review of the intellectual content; final approval; acceptance of responsibility for all aspects of the article and for researching and resolving any issue regarding the accuracy and truthfulness of any part of the study. G. Bellia-Munzón: concept and design; critical review of the intellectual content; final approval; acceptance of responsibility for all aspects of the article and for researching and resolving any issue regarding the accuracy and truthfulness of any part of the study. M. Martínez-Ferro: concept and design; critical review of the intellectual content; final approval; acceptance of responsibility for all aspects of the article and for researching and resolving any issue regarding the accuracy and truthfulness of any part of the study.

## CONFLICTS OF INTEREST

None.

Carlos A. Ingino,<sup>a</sup> Ignacio Raggio,<sup>b,c,\*</sup> Luzia Toselli,<sup>d</sup> Juan Farina,<sup>b</sup> Gaston Bellia-Munzón,<sup>d</sup> and Marcelo Martínez Ferro<sup>d</sup>

<sup>a</sup>Departamento de Cardiología, Instituto Médico ENERI, Clínica La Sagrada Familia, Buenos Aires, Argentina

<sup>b</sup>Departamento de Cardiología, Clínica Olivos, Swiss Medical Group, Buenos Aires, Argentina

<sup>c</sup>Departamento de Ecocardiografía, Centro de Educación Médica e Investigaciones Clínicas Norberto Quirno (CEMIC), Buenos Aires, Argentina

<sup>d</sup>Fundación Hospitalaria Mother and Child Medical Center, Buenos Aires, Argentina

\*Corresponding autor.

E-mail address: [ignaciomaria.raggio@clinicaolivos.com.ar](mailto:ignaciomaria.raggio@clinicaolivos.com.ar)

(I. Raggio).

Available online 3 June 2022

## REFERENCES

- Jaroszewski DE, Velazco CS, Pulivarthi V, et al. Cardiopulmonary function in thoracic wall deformities: what do we really know? *Eur J Pediatr Surg.* 2018;28:327–346.
- Raggio IM, Martínez-Ferro M, Bellia-Munzón G, et al. Diastolic and systolic cardiac dysfunction in pectus excavatum: relationship to exercise and malformation severity. *Radiol Cardiothorac Imaging.* 2020;2:e200011.
- Obermeyer RJ, Cohen NS, Jaroszewski DE. The physiologic impact of pectus excavatum repair. *Semin Pediatr Surg.* 2018;27:127–132.
- Lefebvre C, Hoekstra J. Early detection and diagnosis of acute myocardial infarction: the potential for improved care with next-generation, user-friendly electrocardiographic body surface mapping. *Am J Emerg Med.* 2007;25:1063–1072.
- Ornato JP, Menown IB, Peberdy MA, et al. Body surface mapping vs 12-lead electrocardiography to detect ST-elevation myocardial infarction. *Am J Emerg Med.* 2009;27:779–784.
- Awad SF, Barbosa-Barros R, de Sousa Belem L, et al. Brugada phenocopy in a patient with pectus excavatum: systematic review of the ECG manifestations associated with pectus excavatum. *Ann Noninvasive Electrocardiol.* 2013;18:415–420.

<https://doi.org/10.1016/j.rec.2022.04.012>

1885-5857/

© 2022 Sociedad Española de Cardiología. Published by Elsevier España, S.L.U. All rights reserved.

## Endocardial ganglionated plexi ablation in a patient with cardioinhibitory carotid sinus syndrome



### Ablación endocárdica de plexos ganglionares en un paciente con síndrome del seno carotídeo de predominio cardioinhibitorio

#### To the Editor,

We present the case of a 54-year-old man referred to our hospital for consideration of endocardial neuromodulation. He had had recurrent presyncope and syncope for more than 10 years and had received a dual-chamber pacemaker 2 years after symptom onset and observation of marked symptomatic sinus bradycardia. Nine years later, on detection of ventricular lead dysfunction and left subclavian artery thrombosis, a new device was implanted via a right access, and the original leads were left in

place. The procedure was complicated by cardiac tamponade, so it was decided to remove the device, leaving the patient without pacing support. At the time, given the patient's age and the low ventricular pacing rate, we adopted a watch-and-wait approach. The symptoms, however, persisted (with an average of 2 pre-syncope/syncope episodes a month), and the patient was referred for evaluation of endocardial neuromodulation. After being duly informed, he consented to undergo the procedure and necessary tests and also agreed to the publication of this case report.

The tests performed at our hospital included 24-hour Holter monitoring, which showed no evidence of marked bradyarrhythmia; an exercise stress test, which showed adequate chronotropic competence; and right carotid sinus massage (CSM), which triggered syncope lasting 7.6 seconds (figure 1A). He was diagnosed with cardioinhibitory carotid sinus syndrome and