

## Sirolimus-Eluting Stents to Treat Lesions With a High Risk of Restenosis. Six-Month Clinical Follow-Up in the First 100 Patients

José M. de la Torre Hernández, Virginia Burgos, Susana González-Enrriquez, Manuel Cobo, Javier Zueco, Álvaro Figueroa, and Thierry Colman

Unidad de Hemodinámica y Cardiología Intervencionista, Hospital Universitario Marqués de Valdecilla, Santander, Spain.

**Introduction.** Sirolimus-eluting stents have been shown to be effective in de novo coronary lesions, reducing restenosis strikingly in a subset of lesions with a low or moderate risk of restenosis. We decided to assess their usefulness in lesions with a high risk of restenosis.

**Patients and Methods.** We included consecutive patients with lesions that met at least one of the following criteria: a) in-stent restenosis; b) diffuse lesion (>20 mm); c) small vessel ( $\leq 2.5$  mm); and d) total occlusion.

**Results.** Between June 2002 and December 2002, 100 patients were included ( $61 \pm 11$  years, 84% men, 21% with diabetes). In all, 154 lesions were treated (34% diffuse lesions, 36% in small vessels, 20% in-stent restenosis and 20% occlusions). An average of 1.6 (0.7) stents were implanted per patient. Mean diameter was 2.74 (0.26) mm, mean length was 21 (8.5) mm and total stent length per patient was 33 (16) mm. The acute success rate was 98%. After the procedure two (2%) non-Q wave infarctions were diagnosed. No episodes of acute or subacute thrombosis occurred. During a follow-up period of  $8.5 \pm 2$  months (range, 6-12 months) there were two (2%) late thromboses, one of which caused an infarction. Target lesion revascularization was required in three patients (3%), two of whom were the patients with late thrombosis.

**Conclusions.** Sirolimus-eluting stents can be used in lesions with a high risk of restenosis. The rate of thrombosis was low, and the use of these stents was associated with a strikingly low rate of target lesion revascularization during follow-up.

**Key words:** Lesion. Stent. Restenosis.

Full English text available at: [www.revespcardiol.org](http://www.revespcardiol.org)

Correspondence: Dr. J.M. de la Torre Hernández.  
Unidad de Hemodinámica y Cardiología Intervencionista.  
Hospital Universitario Marqués de Valdecilla.  
Avda. Valdecilla, s/n. 39008 Santander. España.  
E-mail: hemodinamica@humv.es

Received 13 June, 2003.

Accepted for publication 10 November, 2003.

### Stent liberador de rapamicina en el tratamiento de lesiones coronarias con alto riesgo de reestenosis. Seguimiento clínico a 6 meses de los primeros 100 pacientes

**Introducción y objetivos.** Los *stents* con rapamicina han demostrado reducir drásticamente la reestenosis en lesiones con un riesgo reestenótico entre ligero y moderado. No existen estudios amplios que evalúen su comportamiento en contextos lesionales de alto riesgo. Nos planteamos conocer el posible impacto de su empleo en este tipo de lesiones.

**Pacientes y método.** Se incluyó a pacientes consecutivos con indicación de angioplastia con alguna lesión que reuniera al menos una de las siguientes características: a) reestenosis intra-*stent*; b) difusa (> 20 mm); c) vaso pequeño ( $\leq 2,5$  mm), y d) oclusión total.

**Resultados.** Entre junio y diciembre de 2002 se incluyó a 100 pacientes ( $61 \pm 11$  años; un 84% varones; un 21% diabéticos) que tenían 154 lesiones tratadas (un 34% difusas, un 36% en un vaso pequeño, un 20% reestenosis intra-*stent* y un 20% oclusiones). Se implantaron  $1,6 \pm 0,7$  *stents*/paciente, con un diámetro de  $2,74 \pm 0,26$  mm, una longitud de  $21 \pm 8,5$  mm y una longitud total *stent*/paciente de  $33 \pm 16$  mm. Se obtuvo un éxito inmediato en el 98%. Se produjeron 2 infartos sin onda Q (2%) tras el procedimiento. No hubo ningún caso de trombosis agudas ni subagudas. Durante el seguimiento de  $8,5 \pm 2$  meses (rango, 6-12 meses) se produjeron 2 trombosis tardías (2%), a los 3 y 7 meses, una de las cuales ocasionó un infarto. Se efectuó revascularización de la lesión tratada en 3 casos (3%), 2 de los cuales correspondieron a las trombosis tardías.

**Conclusiones.** La utilización de *stents* con rapamicina en lesiones de alto riesgo para reestenosis fue segura y la necesidad de nueva revascularización en el seguimiento fue notablemente baja.

**Palabras clave:** Lesión. Stent. Reestenosis.

## INTRODUCTION

One of the main challenges facing coronary interventions is the restenosis rate which entails the consequent need for revascularization during follow-

up. In our context, percutaneous reinterventions account for 9%-10%<sup>1</sup> of total interventions. This figure is an underestimation of clinical restenosis, since it does not include patients who are sent for revascularization surgery after repeat or non-treatable restenosis, nor those who present recurrence of angina symptoms but are not sent for recatheterization.

In particular groups of patients, such as diabetics,<sup>2</sup> and in certain specific lesions such as diffuse lesions,<sup>3,4</sup> lesions in small vessels,<sup>5-9</sup> total occlusions<sup>10-13</sup>, and in-stent restenosis,<sup>14</sup> the need for a new intervention during follow-up is much higher, amounting to around 10%-30%.

However, treatment of in-stent restenosis continues to be a problem, since standard strategies, such as the use of balloons and stents, have a relatively high incidence of restenosis.<sup>14</sup> The technique that seems to yield better results in this context, brachytherapy, is not generally available due to its logistic and operational complexity.<sup>15,16</sup>

Sirolimus- and paclitaxel-eluting stents have proven to strongly reduce restenosis rates in lesions with a light to moderate risk of restenosis.<sup>17-20</sup> Little information exists regarding their safety and the benefits these stents can offer in higher-risk lesions, although some results have been reported in a small series of in-stent restenosis patients.<sup>21,22</sup> In addition, there is some data related to their use in the clinical context of acute coronary syndrome, including ST-elevation acute myocardial infarction.<sup>23,24</sup>

We evaluated the impact of stent use on clinical restenosis in a group of patients who had lesions with a high risk of restenosis.

## PATIENTS AND METHODS

From 1 June 2002 onwards, we included all patients sent to our unit with clinical indications for coronary angiography who were candidates for percutaneous revascularization, and in whom some or all of the lesions fulfilled at least one of the following criteria:

1. In-stent restenosis.
2. Total occlusion, however old.
3. Diffuse lesion (>20 mm).
4. Lesion in small vessel (2.5 mm).

Patients undergoing primary angioplasty and those in cardiogenic shock were excluded. If the same patient presented other target lesions that did not fulfill these criteria, a sirolimus-eluting stent was also used. Whether to implant the stent directly or not was left to the discretion of the surgeon, although a direct implant was never attempted in cases of total occlusion, where there was a need for a stent >23 mm and in vessels with evident calcification or marked angulation or tortuosity.

The procedure was done via the femoral artery and in all cases vascular closing devices were utilized. The

use of glycoprotein IIb/IIIa inhibitors remained the surgeon's decision. Angiography was considered successful when a residual stenosis <25% with TIMI III flow was achieved. Serial determination of enzymes was not performed systematically, unless there was electrocardiographic or clinical suspicion of necrosis following percutaneous coronary transluminal angioplasty (PTCA) (complications during procedure, ischemia and post-PTCA symptoms). All patients received 300 mg clopidogrel orally immediately after the procedure and, subsequently, 100 mg acetylsalicylic acid and 75 mg clopidogrel in combination for 3 months.

Clinical follow-up was done by checking medical records and a telephone call to all patients. They were monitored by their respective clinical cardiologists, who requested ischemia tests or coronary angiography in those patients for whom they considered it advisable.

## Statistical Analysis

Continuous variables are expressed as mean±SD and categorical variables as percentages. We obtained a Kaplan-Meier curve for event-free survival. Cox regression analysis was done to identify event predictor variables during follow-up. A value of  $P < .05$  was considered statistically significant. The statistical package SPSS 11.0 was used.

## RESULTS

Between June 2002 and December 2002, 100 consecutive patients were included in the study in whom 154 lesions were treated. This series forms 28% of the total number of patients treated in the unit during this period. The clinical characteristics of these patients are presented in Table 1 where the high rates of previous revascularization (31% PTCA, 11% surgery) stand out. The angiographic characteristics of the 154 lesions are described in Table 2. Of these, 109 (71%) fulfilled some or several of the selection criteria and, as required by the criteria, every patient had at least one of these high-risk lesions. Among the 45 target lesions that did not fulfill the criteria, there were some (3 ostial lesions and 6 bifurcational) that could also be regarded as having a high risk of restenosis, although these were not the focus of the study. With regard to total occlusions, of the 31 lesions, 10 were recent, according to clinical data (recent acute coronary syndrome, no primary angioplasty), and the remaining 21 were chronic. Aspects relating to the revascularization procedure and sizes of the stents used are detailed in Table 3. The total length of stents implanted per patient was quite high at 33±16 mm. The abciximab use rate (16%) was similar to that in our experience with standard stents. We attempted to

**TABLE 1. Clinical Characteristics of the 100 Patients\***

Age, years	6±11
Male gender	84 (84%)
Diabetics	21 (21%)
HBP	53 (53%)
Previous AMI	57 (57%)
Previous PTCA	31 (31%)
Previous surgery	11 (11%)
Statins	59 (59%)
Ejection fraction, %	5±9
Stable angina	34 (34%)
Unstable angina	51 (51%)
Silent ischemia	15 (15%)

\*HBP indicates high blood pressure; AMI, acute myocardial infarction; PTCA, percutaneous transluminal coronary angioplasty.

**TABLE 2. Angiographic Characteristics of the Target Lesions**

Right coronary artery	39 (25%)
Anterior descending artery	84 (54.5%)
Circumflex artery	22 (14.3%)
Left main coronary artery	5 (3.2%)
Left internal mammary artery	2 (1.3%)
Saphenous vein	2 (1.3%)
Lesion morphology and severity	
Total occlusion	31 (20.1%)
Recent	10
Chronic (>3 months)	21
In-stent restenosis	31 (20.1%)
Occlusive	7
Diffuse (>10 mm)	12
Focal (<10 mm)	12
Diffuse (>20 mm)	52 (33.74%)
Small vessel (2.5 mm)	55 (35.7%)
Bifurcational	9 (5.8%)
Ostial	3 (1.9%)
Lesion length, mm	19±8
Reference diameter, mm	2.6±0.2
Basal stenosis	69±10%

apply stents directly in 55 lesions, were successful in 52 (94.5%) cases and three needed predilatation. Angiographic success was achieved in 98% of the patients. Of the remaining two cases, one failed due to post-stent TIMI II flow (poor distal bed and competition with collateral circulation), and the other to residual stenosis >25% (fibrocalcified lesion).

### Procedural Complications and Hospitalization

Two non-Q wave infarctions occurred (2%). One was due to occlusive retrograde dissection after implanting a stent in the medial right coronary artery and was resolved with an additional stent. The other was caused by the occlusion of a small diagonal

**TABLE 3. Procedural Characteristics**

Target vessels/patient	1.26±0.46
Target lesions/patient	1.54±0.7
Stents/patient	1.6±0.7
Stent length, mm	21±8.5
Stent diameter, mm	2.74±0.26
Total stent length/patient, mm	33±16
Direct stenting	52 (33.7%)
Abciximab	16 (16%)
Procedural success	98%

**TABLE 4. Clinical Events During Follow-Up**

Hospitalization	
Non-Q wave infarction	2 (2%)
Transient ischemic attack	1 (1%)
Clinical follow-up	
Death	0
Q-wave infarction*	1 (1%)
Late thrombosis	2 (2%)
Target lesion revascularization†	3 (3%)
Other lesion revascularization	1 (1%)
Stroke	1 (1%)

\*Corresponding to one of the cases of late thrombosis

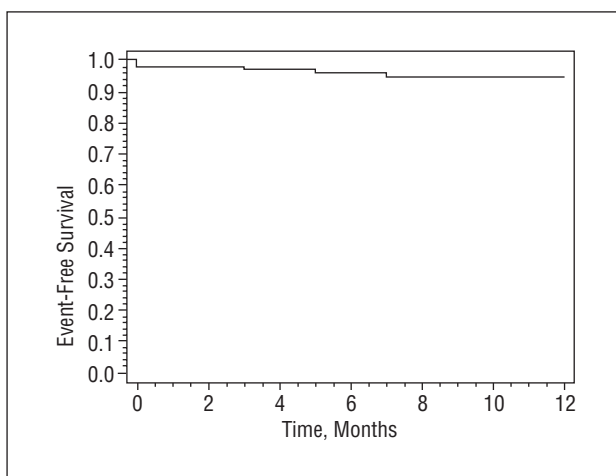
†Two of these correspond to the late thromboses previously mentioned.

branch (diameter <2 mm) after implanting a stent in the anterior descending artery. A transitory ischemic cerebral attack (1%) occurred in a hypertensive 66-year-old male patient (Table 4).

### Clinical Follow-Up

During the follow-up period of 8.5±2 months (6-12 months), during which no patient was lost, two late thromboses occurred (2%) one of which caused an infarction. Three target lesion revascularizations were done (3%), two of which corresponded to the late thromboses mentioned before (Table 4). At the end of follow-up, only 2 patients (2%) presented stable angina class II symptoms but were not sent for further tests due to effective medical control. The event-free survival curve (death, infarction or revascularization of the target lesion) is shown in the Figure.

With regard to late thrombosis, one occurred in a 76-year-old male patient who suffered previous occlusive and diffuse restenosis with a standard stent placed in the proximal-medial part of the anterior descending artery. The distal bed of the vessel was diffusely diseased and was visualized perfectly through the large collateral vessels from the posterior interventricular branch of the right coronary artery. After predilatation, a Cypher® stent was implanted (length, 33 mm; diameter, 2.75 mm), without ever achieving adequate flow (TIMI II). At 3 months, and immediately after suspending clopidogrel use, the



**Fig. 1.** Kaplan-Meier curve of event-free survival (death, infarction or revascularization of the target lesion).

patient began to present unstable angina and high troponin I levels. Coronary angiography revealed total occlusion of the stent, with the vessel distal to the stent filled because of excellent collateral circulation. Surgical revascularization from the left internal mammary artery to the anterior descending artery was successfully done without extracorporeal circulation.

The other case also involved a 76-year-old patient and occurred 7 months after an initial procedure in which a 33-mm stent was implanted in a de novo lesion in the proximal-medial anterior descending artery. Coronary angiography showed an occlusive lesion located immediately distal to the stent (which was 50% in the initial study) in the medial anterior descending artery. This had produced a thrombosis extending toward the stent. After the thrombotic material was extracted with an X-Sizer® device, an angiography revealed a certain degree of focal restenosis in the stent. A stent was implanted again following angioplasty.

A 45-year-old diabetic patient treated with insulin presented progressive effort angina 5 months after the procedure. She initially presented three-vessel disease with vascular beds in poor condition for surgery. Percutaneous revascularization was therefore performed with Cypher® stents implanted in the anterior descending artery (3/33 mm and 3/8 mm), in the circumflex artery (2.5/33 mm), and in the right artery (3/18 mm). Coronary angiography carried out 5 months later due to recurrence of symptoms showed two non-marginal in-stent restenotic lesions, severe and focal (<5 mm) in the anterior descending artery and the circumflex artery. Cutting-balloon angioplasty was done in both lesions. Four months after the second procedure, the patient again presented progressive effort angina. Coronary angiography showed focal restenosis in the same locations in the circumflex artery stent, as well

as others more distally located in the anterior descending artery stent which were treated by the in-stent implantation of short Cypher® stents.

Finally, 3 patients needed a new coronary angiogram for recurrent symptoms. In one patient, progression was observed in a previously moderate lesion in the target vessel but far from the stent (>10 mm), and in the other 2 patients there were no changes in the coronary tree. A new angioplasty was done in the first patient. The complete absence of in-stent and stent margin restenosis was striking in these patients, which is a relatively infrequent situation with standard stents.

Regarding the 15 patients who had an initial diagnosis of silent ischemia (tests strongly positive for ischemia under treatment, but without associated symptoms), tests for ischemia were done during follow-up with negative results in most cases (13 patients). In 2 patients a far smaller degree of positivity without medication was detected which did not constitute an indication for coronary angiography. According to clinical criteria, the patients presented a certain degree of diffuse atheromatosis and this could explain the mild residual ischemia.

## DISCUSSION

Percutaneous revascularization has yielded good results due to technical and pharmacological progress in recent years, both in terms of safety and mid- and long-term clinical benefits. The basic restriction of this therapy is the appearance of restenosis and the consequent need for new revascularization in the mid-term. With the current rate of stent implantation (80%), the total percentage of angioplasty reinterventions is around 9%-10%.<sup>1</sup> This figure refers to clinical restenosis, which is always lower than the rate of angiographic restenosis, but it is this which really determines the impact of this event in clinical practice. Nevertheless, this does not include the proportion of patients who undergo surgical reinterventions, only those undergoing percutaneous ones. In our experience, 14% of patients with clinical restenosis will have to undergo surgical procedures, either after the first restenosis or the second. In some lesions, such as diffuse ones,<sup>3,4</sup> lesions in small vessels,<sup>5-9</sup> total occlusion,<sup>10-13</sup> and especially, in-stent restenosis,<sup>14</sup> clinical restenosis is significantly higher (10%-30%).

Thus, intense research has recently been geared toward developing methods for combating restenosis. Basic lines of work have focused on brachytherapy, pharmacology and coated stents. Brachytherapy has demonstrated its efficacy,<sup>15,16</sup> although aspects relating to its safety (late-stent thrombosis, edge restenosis, etc), application, and logistics have strongly limited its becoming more widespread. Some systemic drugs,

such as tranilast, although having undergone promising pilot studies have not demonstrated their efficacy in larger tests.<sup>25</sup> Finally, drug-free stents offer the greatest potential and have already yielded excellent results. Nevertheless, the large studies done to date with sirolimus- and paclitaxel-eluting stents have only evaluated lesions with a light- to moderate risk of restenosis and have excluded lesions >30 mm, total occlusion, ostial lesions, lesions requiring stents <2.5 mm or in-stent restenosis.<sup>18-20</sup> The efficacy of coated stents remains unknown in these lesions, although small studies with a short follow-up have been published that suggest good results, specifically for in-stent restenosis.<sup>21,22</sup> In view of this, from the moment the Cypher<sup>®</sup> stent (sirolimus-eluting) was made available, we began a study to evaluate clinical restenosis in those patients who had lesions which presented characteristics more prone to restenosis—i.e., diffuse lesions, those in small vessels, total occlusion and in-stent restenosis. In some of these cases, especially diffuse in-stent restenosis, it is probable that in the absence of these stents the patients would have undergone revascularization surgery. Thus, we studied a high-risk group with a high rate of multiple lesions and multivessel revascularization, and who had undergone previous procedures. Seventy-one percent of the lesions treated in these patients fulfilled at least one of the inclusion criteria that involved a greater risk of restenosis.

No incidence of acute thrombosis or subacute thrombosis was observed. The first episode of late thrombosis involved a patient with a non-optimal initial result (TIMI II flow, competition from direct collateral circulation) and in whom the occlusion occurred after stopping clopidogrel use (3 months after the procedure); however, due to excellent collateral circulation, it manifested as unstable angina and not as infarction. The other case, described as a late thrombosis that appeared as an infarction at 7 months, raises certain doubts. This case appeared to be a late thrombosis, but we believe that, given the angiographic image of the lesion distal to the stent and the elapsed time (7 months), it could also be explained by a complication involving the distal lesion and consequent thrombosis retrograde to the occlusion that would have affected the stent.

Finally, the last case involved clear clinical restenosis in a diabetic patient treated with insulin with multivessel and severe diffuse coronary disease. Initially, a 92-mm-long stent was implanted. Based on our previous experience, we believe that, given the clinical and anatomical characteristics of the patient, the restenosis would have been more diffuse and severe had we used standard stents. Nevertheless, this case shows that restenosis can in some cases continue to be a problem despite advances in new therapies, although it is a far less frequent problem and easier to

manage (focal restenosis).

Without doubt, the 3% of patients who underwent new target lesion revascularizations during follow-up (including thrombosis cases)—with 2% of patients with class II stable angina at the end of follow-up—is a spectacular result in a group of patients with lesions having the characteristics described above. Furthermore, these would be good results even for a population with non-selected lesions.

The group of 26 patients in which 31 in-stent restenoses were treated presented the most striking results. Only one patient (3.8%) presented events during follow-up (the late thrombosis case mentioned previously). Based on our previous experience, approximately one-third of patients treated with standard stents or balloons for in-stent restenotic lesions are readmitted with new clinical restenosis. In the RIBS study, in which 450 cases of non-occlusive in-stent restenosis were randomized to treatment with balloons or stents, the revascularization rate of the target vessel per year was 19.6% in the stent group and 24.3% in the balloon group.<sup>14</sup>

The antiplatelet therapy period varies from study to study: this was 2 months in the RAVEL study,<sup>18</sup> 3 months in the SIRIUS study,<sup>19</sup> 2-4 months in the Rotterdam group for in-stent restenosis study<sup>21</sup> and 3 months in the acute coronary syndrome study (6 months if there were patients treated with more than 3 stents, >36 mm stents, bifurcational or in-stent restenosis).<sup>23,24</sup> In our case, treatment was carried out for 3 months but, based on empirical evidence, a 6-month period might be advisable in cases of in-stent restenosis, long stents, multiple stents, etc. The two late thrombosis cases described above may support this position which is the one we currently adopt.

The possible drawbacks of prolonging combined acetylsalicylic acid and clopidogrel therapy for periods of 3 months or more need addressing. Regarding safety, we did not observe significant hemorrhages or allergic or hematological reactions. However, it should be mentioned that more than half of the revascularized patients previously presented anginal instability and we know that with or without revascularization these patients benefit from a prolonged period (>3 months) of combined antiplatelet treatment.<sup>26,27</sup> On the other hand, more recent studies demonstrate that combined antiplatelet treatment for a year leads to the reduction of ischemic events in patients who have undergone angioplasty with or without diagnosed unstable angina.<sup>28</sup> Thus, the benefits of combination therapy are doubled with the prevention of stent thrombosis being added to the reduction of new events in different coronary lesions.

## Limitations

This was an observational study describing the

results obtained in a selected consecutive nonrandom series of patients which, accordingly, lacks a control group. In addition, angiographic follow-up was not done. Although this detracts from the value from the study, it should be mentioned that the study was set within the context of clinical practice. As such, our interest lay in investigating the impact of the use of these stents, their safety (incidence of thrombosis), reducing the need for new reinterventions, and the clinical status of the patient at the end of a reasonable clinical follow-up period.

These striking and unprecedented results are obviously in contrast with all the previous experience reported with standard stents in similar lesions<sup>3-14</sup> and with our own experience, thus making it possible to draw very positive conclusions.

It could be argued that using the need for new revascularization as the deciding criterion introduces subjectivity into the result. However, the direct and independent evaluation of the clinical status of the patients at the end of follow-up confirms that this aim was realistic, since only two patients presented stable angina class II at the end of this period.

## CONCLUSIONS

The use of sirolimus-eluting stents in lesions with a high risk of restenosis (diffuse, vessel 2.5 mm, total occlusion and in-stent restenosis) appears to be safe and very effective. Taking the limitations of this study into account, a larger series of patients with random comparisons with standard stents is needed to consolidate these findings with greater certainty.

## REFERENCES

- Hernández JM, Goicolea J, Durán JM, Augé JM. Registro Español de Hemodinámica y Cardiología Intervencionista. XI informe oficial de la Sección de Hemodinámica y Cardiología Intervencionista de la Sociedad Española de Cardiología (años 1990-2001). *Rev Esp Cardiol* 2002;55:1173-84.
- Alonso JJ, Durán JM, Gimeno F, Ramos B, Serrador A, Fernández-Aviles F. Angioplastia coronaria en el paciente diabético. Situación actual y perspectivas futuras. *Rev Esp Cardiol* 2002;55:185-200.
- Kastrati A, Elezi S, Dirschinger J, Hadamitzky M, Neumann FJ, Schomig A. Influence of lesion length on restenosis after coronary stent placement. *Am J Cardiol* 1999;83:1617-22.
- Kobayashi Y, de Gregorio J, Kobayashi N, Akiyama T, Reimers B, Finci L, et al. Stented segment length as an independent predictor of restenosis. *J Am Coll Cardiol* 1999;34:651-9.
- Doucet S, Schalig MJ, Vrolix MCM, Hilton D, Chenu P, de Bruyne B, et al. Stent placement to prevent restenosis after angioplasty in small coronary arteries. *Circulation* 2001;104:2029-33.
- Kastrati A, Schomig A, Dirschinger J, Mehilli J, Dotzer F, von Welser N, et al. A randomized trial comparing stenting with balloon angioplasty in small vessels in patients with symptomatic coronary artery disease. *Circulation* 2000;102:2593-8.
- Koning R, Eltchaninoff H, Commeau P, Khalife K, Gilard M, Lipiecki J, et al. Stent placement compared with balloon angioplasty for small coronary arteries: in hospital and 6-month clinical and angiographic results. *Circulation* 2001;104:1604-8.
- Moer R, Myreng Y, Moldstad P, Albertsson P, Gunnes P, Lindvall B, et al. Stenting in small coronary arteries (SISCA) trial. A randomized comparison between balloon angioplasty and the heparin-coated beStent. *J Am Coll Cardiol* 2001;38:1598-603.
- García E, Gómez-Recio M, Moreno R, Pasalodos J, Bethancourt A, Zueco J, et al. Stent reduces restenosis in small vessels. Results of the RAP study [abstract]. *J Am Coll Cardiol* 2001;37(Suppl A):32-4.
- Rubartelli P, Niccoli L, Verna E, Giachero C, Zimarino M, Fontanelli A, et al. Stent implantation versus balloon angioplasty in chronic coronary occlusions: results from the GISSOC trial. *J Am Coll Cardiol* 2001;38:1598-603.
- Buller CE, Dzavik V, Carere RG, Mancini GBJ, Barbeau G, Lazzam C, et al for the TOSCA investigators. Primary stenting versus balloon angioplasty in occluded coronary arteries. The total occlusion study of Canada (TOSCA). *Circulation* 1999;100:236-42.
- Sievert H, Rohde S, Utech A, Schulze R, Scherer D, Merle H, et al. Stent or angioplasty after recanalization of chronic coronary occlusions? The SARECCO trial. *Am J Cardiol* 1999;84:386-90.
- Lotan C, Rozenman Y, Hendler A, Turgeman Y, Ayzenberg O, Beyar R, et al. Stents in total occlusion for restenosis prevention. The multicentre randomized STOP study. *Eur Heart J* 2000;21:1960-6.
- Alfonso F, Zueco J, Cequier A, Mantilla R, Bethencourt A, López-Minguez JR, et al for the RIBS study. A randomized comparison of repeat stenting with balloon angioplasty in patients with in-stent restenosis. *J Am Coll Cardiol* 2003;42:796-805.
- Leon MB, Teirstein PS, Moses JW, Tripuraneni P, Lansky AJ, Jani S, et al. Localized intracoronary gamma-radiation therapy to inhibit the recurrence of restenosis after stenting. *N Engl J Med* 2001;344:250-6.
- Popma JJ, Suntharalingam M, Lansky AJ, Heuser RR, Speiser B, Teirstein PS, et al. Randomized trial of <sup>90</sup>Sr/<sup>90</sup>Y beta-radiation versus placebo control for treatment of in stent restenosis. *Circulation* 2002;106:1090-6.
- Fuster V. La rapamicina: del laboratorio al tratamiento de las arterias en los pacientes. *Rev Esp Cardiol* 2003;56(Supl 1):2-6.
- Morice MC, Serruys PW, Sousa JE, Fajadet J, Ban Hayashi E, Perin M, et al for the RAVEL study group. A randomized comparison of a sirolimus eluting stent with a standard stent for coronary revascularization. *N Engl J Med* 2002;346:1773-80.
- Moses J, Leon MB, Popma JJ, Fitzgerald PJ, Holmes DR, O'Shaughnessy C, et al, for the SIRIUS investigators. Sirolimus-eluting stents versus standard stents in patients with stenosis in a native coronary artery. *N Engl J Med* 2003;349:1315-23.
- Grube E, Silber S, Hauptmann KE, Mueller R, Buellesfeld L, Gerckens U, et al. TAXUS I. Six and twelve month results from a randomized, double blind trial on a slow release paclitaxel eluting stent for de novo coronary lesions. *Circulation* 2003;107:38-42.
- Degertekin M, Regar E, Tanabe K, Smits PC, van der Giessen WJ, Carlier SG, et al. Sirolimus eluting stent for treatment of complex in stent restenosis: the first clinical experience. *J Am Coll Cardiol* 2003;41:184-9.
- Tanabe K, Serruys PW, Grube E, Smits PC, Selbach G, van der Giessen WJ, et al. TAXUS III. In stent restenosis treated with stent based delivery of paclitaxel incorporated in a slow release polymer formulation. *Circulation* 2003;107:559-64.
- Lemos PA, Lee C, Degertekin M, Saia F, Tanabe K, Arampatzis CA, et al. Early outcome after sirolimus-eluting stent implantation in patients with acute coronary syndromes. Insights from the Rapamycin Eluting Stent Evaluated At Rotterdam Cardiology Hospital (RESEARCH) registry. *J Am Coll Cardiol* 2003;41:2093-9.
- Saia F, Lemos PA, Lee C, Arampatzis CA, Hoyer A, Degertekin

- M, et al. Sirolimus-eluting stent implantation in ST-elevation acute myocardial infarction. A clinical and angiographic study. *Circulation* 2003;108:1927-9.
25. Holmes DR, Savage M Jr, LaBlanche JM, Grip L, Serruys PW, Fitzgerald P, et al. Results of prevention of restenosis with tranilast and its outcomes (PRESTO) trial. *Circulation* 2002;106:1243-50.
26. Yusuf S, Mehta SR, Zhao F, Gersh BJ, Commerford PJ, Budaj A, et al. Early and late effects of clopidogrel in patients with acute coronary syndromes. *Circulation* 2003;107:966-72.
27. Mehta SR, Yusuf S, Peters RJ, Bertrand ME, Lewis BS, Natarajan MK, et al. Effects of pre-treatment with clopidogrel and aspirin followed by long-term therapy in patients undergoing percutaneous coronary intervention: the PCI-CURE study. *Lancet* 2001;358:527-33.
28. Steinhubl SR, Berger PB, Mann JT, Fry ETA, DeLago A, Wilmer C, et al. Early and sustained dual oral antiplatelet therapy following percutaneous coronary intervention. A randomized controlled trial. *JAMA* 2002;288:2411-20.