

by adequate prolonged antibiotic therapy and close follow-up, proved to be an effective approach.

Radka Ivanova-Georgieva,^{a,*} Gemma Sánchez,^b Rocío Arnedo,^a Josefa Ruiz-Morales,^a María José Mataró,^b and José María Melero^b

^aUnidad de Gestión Clínica de Enfermedades Infecciosas, Hospital Clínico Virgen de la Victoria, Málaga, Spain

^bUnidad de Gestión Clínica de Cirugía Cardíaca, Hospital Clínico Virgen de la Victoria, Málaga, Spain

* Corresponding author:

E-mail address: drradabg@yahoo.com (R. Ivanova-Georgieva).

Available online 11 November 2012

REFERENCES

1. Coselli J, Koksoy C, LeMaire SA. Management of thoracic aortic graft infections. *Ann Thorac Surg.* 1999;67:1990–3.
2. Samoukovic G, Pierre-Luc B, Lachapelle K. Successful treatment of infected ascending aortic prosthesis by omental wrapping without graft removal. *Ann Thorac Surg.* 2008;86:287–9.
3. Akowuah E, Narayan P, Angelini G, Bryan AJ. Management of prosthetic graft infection after surgery of the thoracic aorta: removal of the prosthetic graft is not necessary. *J Thorac Cardiovasc Surg.* 2007;134:1051–2.
4. LeMaire S, Coselli J. Option of managing infected aortic grafts. *J Thorac Cardiovasc Surg.* 2007;134:839–43.
5. Fitzgerald SF, Kelly C, Humphreys H. Diagnosis and treatment of prosthetic aortic graft infections: confusion and inconsistency in the absence of evidence or consensus. *J Antimicrob Chemother.* 2005;56:996–9.

<http://dx.doi.org/10.1016/j.rec.2012.08.004>

Simplified Approach for Ablation of Nodal Reentrant Tachycardia in a Patient With Tricuspid Atresia and Extracardiac Fontan Palliation

Abordaje simplificado para la ablación de la taquicardia por reentrada intranodal en paciente con atresia tricuspídea y Fontan extracardiaco

To the Editor,

Fontan palliation was first described for the treatment of tricuspid atresia, but the indications have since been extended to other complex congenital defects such as univentricular hearts.¹ Since the original atriopulmonary connection procedure—which was associated with a high incidence of atrial arrhythmias, among other disadvantages—the technique has been improved and extracardiac cavopulmonary connection is currently used.¹ This approach is simple, the hemodynamic outcomes are excellent, and the percentage of arrhythmias during follow-up is low.² However, atrial arrhythmias are not completely eliminated and the venous

access routes to the heart are lacking, making percutaneous techniques much more difficult to carry out.

We report the case of a 4-year-old boy weighing 19.5 kg, who had a univentricular heart due to tricuspid atresia. The position of the great vessels was normal, and there was an obstructive bulboventricular foramen. He had undergone a bidirectional Glenn procedure and ligation of the pulmonary artery when aged 2 years. Subsequently, extracardiac Fontan palliation was performed. Three months after the last intervention, he started to experience episodes of supraventricular tachycardia, with poor hemodynamic tolerance, which required repeated admission to the emergency room. The episodes remitted with intravenous adenosine. Despite treatment with sotalol, the crises became more frequent. An electrophysiological study was therefore ordered and was performed under general anesthetic. Given that there was no venous connection with the cardiac chambers, a 5-mm ablation catheter was introduced by a retroaortic approach (Therapy[®], St. Jude Medical) into the left ventricle. Another 7-mm catheter (Celsius[®], Biosense-Webster) was introduced through the esophagus to record atrial activity (Figs. 1A and B). The conduction

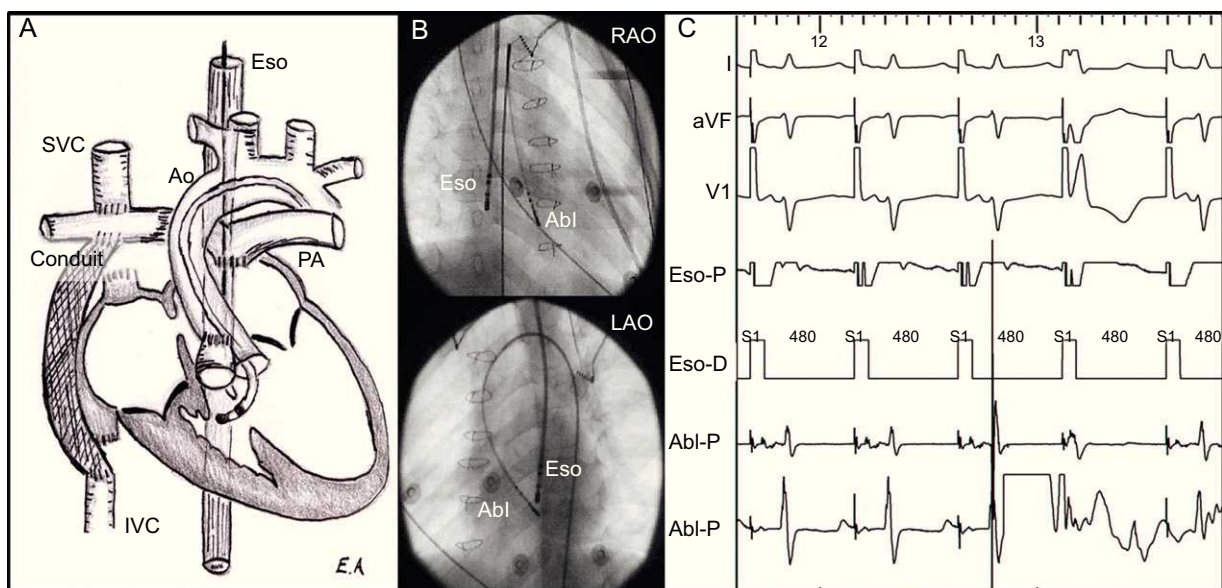


Figure 1. A: Anatomical schematic. B: Position of the ablation catheters. C: Electrogram at the application point. Abl, ablation catheter; Ao, aorta; Eso, esophagus; IVC, inferior vena cava; LAO, left anterior oblique; PA, pulmonary artery; RAO, right anterior oblique; SVC, superior vena cava.

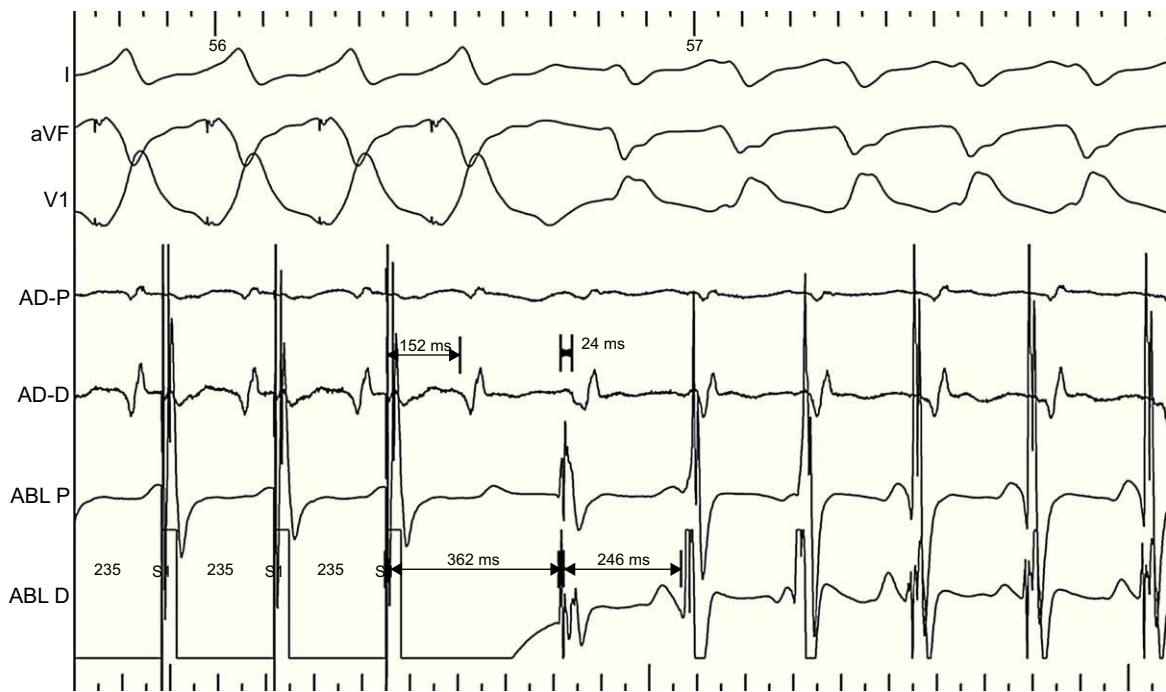


Figure 2. Entrainment of ventricular tachycardia.

intervals were normal. The anterograde and retrograde conductions were decremental. Tachycardia was easily induced with isoproterenol with both atrial and ventricular pacing, with a decrease in nodal conduction. The tachycardia was regular with a broad QRS interval and had the morphology of a complete right bundle branch block, with a cycle duration of 246 ms, an atrial ratio of 1:1 and a ventriculoatrial interval of 24 ms. The mapping catheter recorded His bundle activity 38 ms prior to the ventriculogram (as at baseline). Atrial entrainment did not alter the QRS morphology. Ventricular entrainment occurred without fusion, with prolongation of the ventriculoatrial interval and ventricle-atrium-ventricle response, with a return cycle 116 ms longer than the tachycardia cycle (Fig. 2). These data confirmed the nodal reentrant tachycardia with aberrant ventricular conduction. With the patient in sinus rhythm, the ablation catheter was guided to the region of the slow pathway, in the inferior part of the left atrial septum, as previously described.³ A less intense signal than the ventricular signal was observed (Figs. 1B and C). Junctional rhythm was produced mechanically. With left atrial pacing, a 35 W radiofrequency pulse was applied at 55°C for 30 s while atrioventricular conduction was monitored. Afterwards, tachycardia could not be induced and a nodal echo remained. No recurrences were found after 4 months of follow-up.

In patients with tricuspid atresia who undergo Fontan palliation, supraventricular arrhythmias are usually atrial (atrial tachycardia and atrial fibrillation), with an incidence of up to 30%.² Although the extracardiac cavopulmonary connection technique has reduced the incidence of these arrhythmias to less than 5%, by preventing dilatation and incisions in the right atrium, these substrates and other less common substrates (accessory pathway tachycardias and nodal tachycardias) still occur.^{2,3} The absence of venous approaches to the cardiac chambers hinders electrophysiological study and percutaneous catheter ablation. Alternative approaches have been described to treat atrial tachycardias, such as transthoracic puncture or direct puncture with the cannula used for the cavopulmonary shunt.^{4,5} Such procedures are complex and riskier than conventional approaches, particularly in children.

To our knowledge, there have been no reports of ablation of nodal tachycardia in patients who have undergone extracardiac Fontan palliation. The guided catheter introduced through the esophagus is easily manipulated and simplifies the study, as it can record activity and pace the left atrium. In addition, the retroaortic approach for the ablation catheter is easy and provides ready access to the lower part of the left atrial septum, which is the position of choice for ablation of nodal tachycardia in patients with tricuspid atresia.³ In these patients, the compact node usually lies next to the central fibrous body, underneath the atresic valve and above the ostium of the coronary sinus. A left septal approach is required to record the hisigram and locate the fast pathway, as described by electroanatomic mapping.³ The slow pathway is located under this position, and ablation at this point can be safely and effectively performed.

Eduardo Arana-Rueda,^{a,*} Alonso Pedrote,^a
Juan Manuel Durán-Guerrero,^a and José Santos de Soto^b

^aUnidad de Arritmias, Hospital Universitario Virgen del Rocío, Sevilla, Spain

^bServicio de Cardiología Pediátrica, Hospital Universitario Virgen del Rocío, Sevilla, Spain

* Corresponding author:

E-mail address: eduaru@hotmail.com (E. Arana-Rueda).

Available online 13 November 2012

REFERENCES

- Leval MR, Deanfield JE. Four decades of Fontan Palliation. *Nat Rev Cardiol.* 2010;7:520–7.
- Weipert J, Noebauer C, Schreiber C, Kostolny M, Zrenner B, Wacker A, et al. Occurrence and management of atrial arrhythmia after long-term Fontan circulation. *J Thorac Cardiovasc Surg.* 2004;127:457–64.

3. Khairy P, Seslar SP, Triedman JK, Cecchin F. Ablation of atrioventricular nodal reentrant tachycardia in tricuspid atresia. *J Cardiovasc Electrophysiol*. 2004;15:719-22.
4. Nehgme RA, Carboni MR, Care J, Murphy JD. Transthoracic percutaneous access for electroanatomic mapping and catheter ablation of atrial tachycardia in patients with a lateral tunnel Fontan. *Heart Rhythm*. 2006;3:37-43.

5. Dave AS, Aboulhosn J, Child JS, Shivkumar K. Transcatheter puncture for catheter ablation of atrial tachycardia in a patient with extracardiac Fontan palliation. *Heart Rhythm*. 2010;7:413-6.

<http://dx.doi.org/10.1016/j.rec.2012.08.005>

Utility of Multidetector Computed Tomography for Postprocedure Evaluation of Endovascular Aortic Stent-grafts

Utilidad de la tomografía computarizada multidetectores en el seguimiento de las endoprótesis aórticas

To the Editor,

Endovascular repair techniques for diseases affecting the descending thoracic aorta¹ are often used as an alternative to surgery, particularly in older patients and those with associated diseases, because of the lower morbidity and mortality of these procedures.² The reported long-term outcome of endovascular repair varies considerably among studies. The most commonly described complication is detection of endoleaks, which are defined as persistent arterial flow external to the stent-graft lumen. Although the diagnosis has been traditionally established by digital subtraction angiography, computed tomography, which tends to be the initial diagnostic technique used in these aortic diseases, is increasingly being employed for long-term follow-up of these patients.³

We carried out a study to determine the presence and types of late endoleaks in descending aorta stent-grafts by multidetector computed tomography.

This study included 36 patients (32 men) with a mean age of 63 (36-83) years, who underwent endovascular stent grafting of the descending aorta between January 2008 and January 2011, and had more than 1 year of multidetector computed tomography follow-up.

Endovascular treatment was performed for the following indications: aortic aneurysms (14 patients), type B aortic dissection (16 patients), intramural hematoma associated with a penetrating aortic ulcer (5 patients), and traumatic aortic rupture (1 patient).

A 64-detector computed tomography unit was used, and the study covered the entire thorax and abdomen in 2 acquisitions. The first was performed without contrast and the second was contrast-enhanced in the arterial phase to identify calcifications that could simulate an endoleak because of their high radiologic density. In addition to the usual axial, coronal, and oblique views, multiplanar reconstruction (MPR), maximum intensity projection (MIP) and 3-dimensional virtual reconstructions (3D-VR) were performed. In all patients, an advanced analysis of the vessel was carried out, calculating the area and diameters of the entire aorta in slices perpendicular to its longitudinal axis. When required, the vessel section was corrected manually (as in cases of thrombosed aneurysms) to include the area that had been excluded and to assess possible growth.

We analyzed the presence of 4 of the 5 types of endoleaks described:⁴ type I, deficient sealing of the stent-graft (proximal or distal neck); type II, retrograde flow through collateral vessels; type III, structural changes in the stent-graft (breakage or modular separation); and type V, endotension (expansion of a thrombosed aneurysm without evidence of endoleak formation). Type IV endoleak (porosity) was not included, being a rare, transient endoleak that is detected on invasive arteriography.

Endoleaks were detected in 9 (25%) of the 36 patients. In 8 patients, type I, II and III endoleaks were seen on the first multidetector computed tomography study following stent-graft implantation (1-6 months) and in 1 patient, a type V endoleak was demonstrated at the 1-year follow-up, with continuous expansion in successive studies.

Type I endoleaks were observed in 4 patients with aortic dissection; type II, in 1 patient with an aneurysm; type III, in 3 patients with an aneurysm; and type V, in 1 patient, also with an aneurysm (Figure).

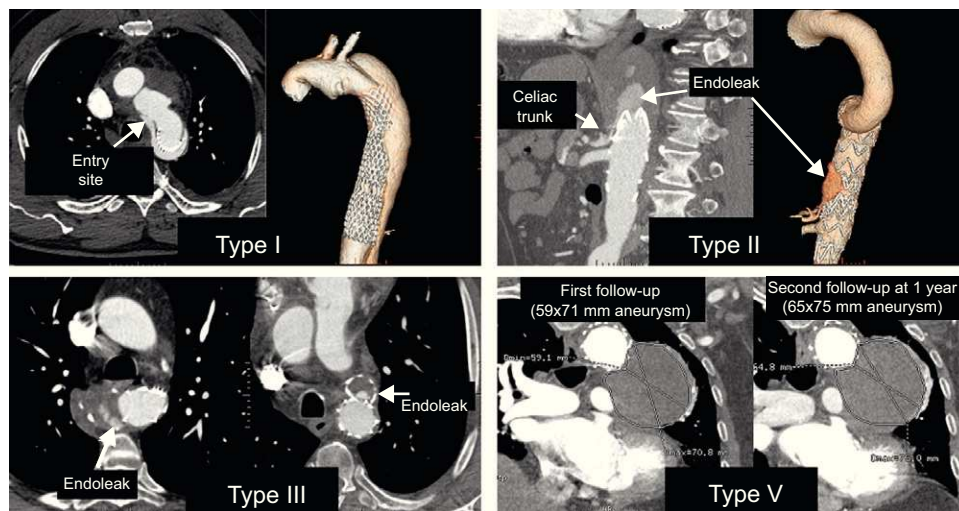


Figure. Type I endoleak: Dissection of the descending aorta with defective sealing of the proximal portion of the stent-graft. Type II endoleak: With repatency of the aneurysmal sac through the celiac trunk, which was occluded at its origin, with filling through collateral vessels from the superior mesenteric artery. Type III endoleak: 2 cases with contrast passage to the aneurysm due to a structural stent-graft alteration. Type V endoleak: Expansion of a thrombosed aneurysm at the follow-up examination, without evidence of a leak.