

Image in cardiology

SAPIEN 3 Embolization Due to a Leak in the Y Connector



SAPIEN 3 embolizada por fuga en el conector en Y

José María Cubero Gómez, Mónica Fernández Quero, and Sara Casquero Domínguez*

Unidad de Hemodinámica y Cardiología Intervencionista, Hospital Universitario Virgen del Rocío, Sevilla, Spain

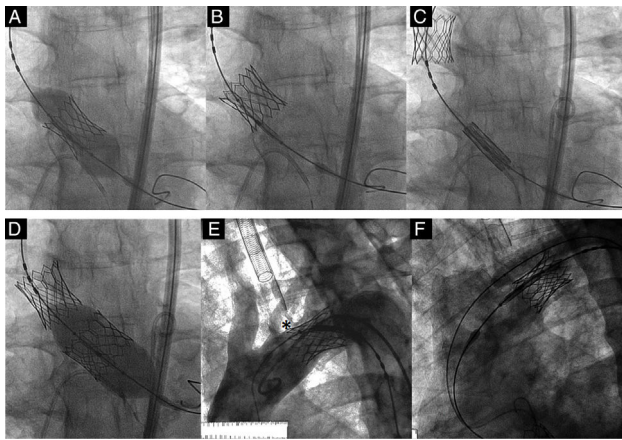


Figure 1.

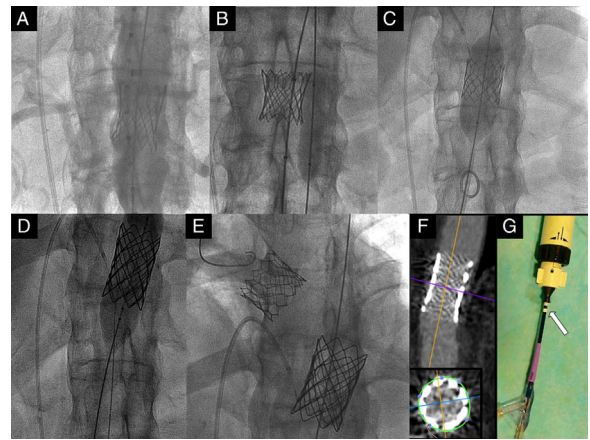


Figure 2.

An 81-year-old man with severe aortic valve stenosis (mean gradient, 45 mmHg; valve area, 0.70 cm²) was referred for percutaneous aortic valve implantation given his frailty (Society of Thoracic Surgeons Predicted Risk of Mortality score < 5%). After balloon valvuloplasty with a 23-mm catheter, an Edwards SAPIEN 3 26-mm valve was positioned on the aortic annulus. During inflation, the valve did not fully deploy (Figure 1A). Reinflation was attempted without achieving the desired deployment and the valve migrated toward the ascending aorta (Figure 1B). A second 26-mm Edwards SAPIEN 3 valve was successfully implanted through the migrated valve (Figure 1C and 1D). This second valve was also subsequently displaced, with inversion (video of the supplementary material). It was not implanted in the transverse arch due to the risk of occlusion of the left vertebral artery (Figure 1E, the asterisk marks the origin of the aorta). The Edwards SAPIEN 3 valve required traction and buddy-balloon technique (Figure 1F) to cross the horizontal thoracic aorta, before descending to the celiac axis (Figure 2A). In view of the risk of abdominal ischemia (inverted prosthesis, Figure 2B), it was displaced and implanted in the descending thoracic aorta (Figure 2C) with subsequent Cheatham Platinum (CP) 45 x 24 mm stent placement (Figure 2D and 2E). Subsequent computed tomography showed that the stent was patent (Figure 2F). The patient was asymptomatic 9 months later.

The mechanism that caused prosthesis migration in our case has not been reported previously. The leak in the Commander delivery system arose from a fissure in the inflation axis of the Y connector (Figure 2G, arrow), thus not allowing full valve deployment.

CONFLICTS OF INTEREST

J.M. Cubero Gómez has received fees as a participant in talks organized by Edwards Lifesciences.

SUPPLEMENTARY MATERIAL



Supplementary material associated with this article can be found in the online version available at <http://dx.doi.org/10.1016/j.rec.2017.06.015>.

* Corresponding author:

E-mail address: saracasquero@gmail.com (S. Casquero Domínguez).

Available online 18 July 2017

<http://dx.doi.org/10.1016/j.rec.2017.06.015>

1885-5857/© 2017 Sociedad Española de Cardiología. Published by Elsevier España, S.L.U. All rights reserved.