

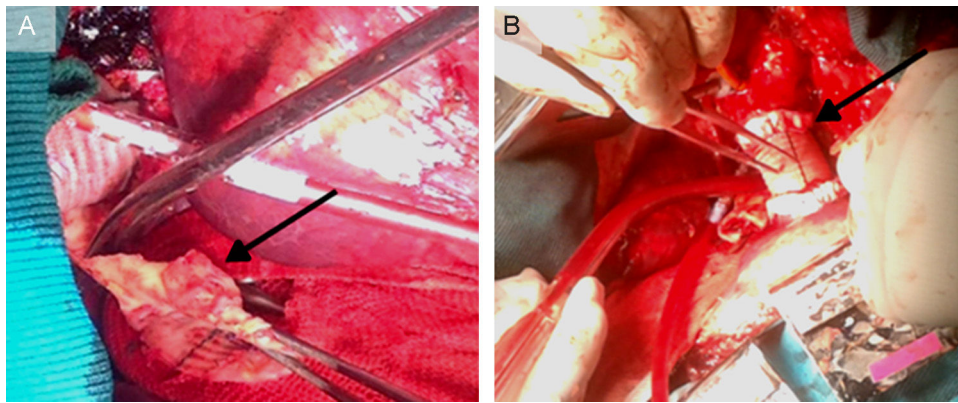Figure 2. A: operative findings: the Dacron patch, a segment of the aortic wall at the level of the suture line dehiscence and periaortic inflammatory tissue (arrow) are evident. B: the surgical repair: Dacron tube graft descending aorta reconstruction (arrow), with suture line being reinforced by Teflon strips. The site of the aortic arch cannulation is also quite evident.

techniques have been proposed. The longitudinal Dacron patch aortoplasty of the aortic constricted segment is preferred by many surgeons as it potentially allows subsequent growth of the aortic wall and reduces the number of collaterals to be tied off. Several postoperative complications have been described, such as restenosis, aneurysm, and pseudoaneurysm, frequently developing many years after the intervention.³

Aneurysm and pseudoaneurysm may occur in up to 10% of patients, at a mean interval from operation superior to 12 years.⁴

In our patient, disruption of the aortic Dacron patch suture line was evident and clearly generated the pseudoaneurysm, composed of thrombotic material surrounded by fibrous and inflammatory tissue. The progressively expanding pseudoaneurysm, mainly in older patients, may compress and erode the pulmonary parenchyma, leading—as in our patient—to the aortopulmonary fistula.

As previously observed,⁵ the present case confirms that sudden lipothymia, hemoptysis, and anemia could be clinical signs indicative of aortopulmonary fistula in patients who have undergone aortic coarctation repair even many decades earlier. Lifelong follow-up after coarctation aortoplasty is recommended.

Giovanni Alfonso Chiariello,* Piergiorgio Bruno, Andrea Mazza, Marco Luciani, Franco Glicca, and Massimo Massetti

Cardiovascular Sciences Department, Catholic University of The Sacred Heart, Agostino Gemelli Policlinic, Rome, Italy

*Corresponding author:

E-mail address: gio.chiariello88@tiscali.it (G.A. Chiariello).

Available online 19 September 2016

REFERENCES

1. Reul Jr GJ, Kabbani SS, Sandiford FM, Wukasch DC, Cooley DA. Repair of coarctation of the thoracic aorta by patch graft aortoplasty. *J Thorac Cardiovasc Surg.* 1974;68:696–704.
2. Lemaire A, Cuttone F, Desgùe J, et al. Late complication after repair of aortic coarctation. *Asian Cardiovasc Thorac Ann.* 2015;23:423–429.
3. Brown ML, Burkhardt HM, Connolly HM, Dearani JA, Hagler DJ, Schaff HV. Late outcomes of reintervention on the descending aorta after repair of aortic coarctation. *Circulation.* 2010;122:81–84.
4. von Kodolitsch Y, Aydin MA, Koschyk DH, et al. Predictors of aneurysmal formation after surgical correction of aortic coarctation. *J Am Coll Cardiol.* 2002;39:617–624.
5. Algaba Calderón A, Jara Chinarro B, Abad Fernández A, Isidoro Navarrete O, Ramos Martos A, Juretschke Moragues MA. Recurrent hemoptysis secondary to an aorto-bronchial fistula. *Arch Bronconeumol.* 2005;41:352–354.

<http://dx.doi.org/10.1016/j.rec.2016.08.005>
1885-5857/

© 2016 Sociedad Española de Cardiología. Published by Elsevier España, S.L.U. All rights reserved.

Safety and Effectiveness of Percutaneous Closure of Left Atrial Appendage in Patients With Intracranial Hemorrhage



Eficacia y seguridad del cierre percutáneo de orejuela izquierda en pacientes con hemorragia intracranial

To the Editor,

Oral anticoagulants (OAC) are the treatment of choice for preventing ischemic stroke in patients with nonvalvular atrial fibrillation (NVAF).¹ However, these drugs (including the new OACs) are associated with an increased risk of serious complications such as intracranial hemorrhage (ICH).² Restarting OACs after an ICH triples the risk of hemorrhagic events,³ therefore their use in this context is controversial and can even be contraindicated.⁴ In addition, there is little evidence on the safety of new OACs following ICH.⁴ Percutaneous closure of the left atrial appendage (LAA) is an effective therapeutic alternative to OACs.⁵ However,

there are insufficient data on the safety and effectiveness of this procedure in patients with ICH.⁶

Our objective was to evaluate the safety and effectiveness of LAA closure in patients with an indication for OACs due to NVAF with a history of ICH.

The study included all patients with an indication for OACs for NVAF and a history of ICH referred to our unit between June 2009 and June 2016 for LAA closure. We analyzed clinical, echocardiographic, and procedure-related variables. The devices used for LAA closure were the Amplatzer Cardiac Plug, the Amplatzer Amulet (both St. Jude Medical), and the Watchman Implant (Boston Scientific). After the procedure, patients were treated with antiplatelet therapy or anticoagulation (low-molecular weight heparin) for at least 45 days. The decision on antiplatelet therapy vs anticoagulation was made at the discretion of the surgeon in consensus with neurology. At follow-up (at 45 days, 6 months, 12 months, and annually thereafter) we analyzed the following variables: death, ischemic stroke, and hemorrhagic

Table 1
Baseline Characteristics

Variables	
Age, y	80 ± 6
Men	25 (53.2)
CHA₂DS₂-VASC	5 ± 1
HAS-BLED	4 ± 1
AF	
Paroxysmal	8 (17)
Permanent	39 (83)
Previous coronary disease	9 (19.2)
PVD	6 (12.8)
CKD	7 (14.9)
LVEF, %	60 ± 8
Treatment being taken when admitted for ICH	
Acenocoumarol	30 (63.9)
INR ≥ 3	18 (60)
Antiplatelet agent	8 (17)
Other	9 (19.1)
Type of ICH	
Intraparenchymal	34 (72.3)
Subdural	10 (21.3)
Subarachnoid	2 (4.3)
Microhemorrhages	1 (2.1)
Functional assessment after ICH	
Modified Rankin scale ≤ 2	30 (63.9)
Successful procedure	45 (95.7)
Time from ICH to LAA closure, mo	8 [3-20]
Early closure (< 3 mo)	11 (23.4)
Delayed closure (≥ 3 mo)	36 (76.6)
Devices used	
Amplatzer Cardiac Plug	2 (4.3)
Amplatzer Amulet	21 (44.6)
Watchman Implant	24 (51.1)
Procedure/in-hospital complications	2 (4.2)
Tamponade requiring pericardiocentesis	1 (2.1)
Device embolization requiring surgery	1 (2.1)
Stroke	0
Death	0
Treatment on discharge	
Aspirin + clopidogrel	38 (80.8)
LMWH	2 (4.3)
Aspirin	4 (8.5)
Clopidogrel	1 (2.1)

AF, atrial fibrillation; CKD, chronic kidney disease; ICH, intracranial hemorrhage; INR, international normalized ratio; LAA, left atrial appendage; LMWH, low-molecular weight heparin; LVEF, left ventricular ejection fraction; PVD, peripheral vascular disease.

Values are expressed as No. (%), mean ± standard deviation, or median [interquartile range].

events. A follow-up transesophageal echocardiogram was performed at 45 days postprocedure.

Continuous variables are presented as median [interquartile range] or mean ± standard deviation. Categorical variables are presented as frequency and percentage. A *P*-value < .05 was considered statistically significant.

Table 2
Follow-up

Follow-up time, mo	28 [15-48]
Device-related deaths	0
Ischemic stroke	1 (2.2)
No sequelae	
Cortical hemorrhage (amyloid angiopathy)	1 (2.2)
Annual rate of events	0.86

Values are expressed as No. (%) or median [interquartile range].

Until June 2016, 174 patients underwent percutaneous LAA closure in our hospital. The indication for closure was ICH in 47 patients (27%; 25 men and 22 women). Table 1 shows the patient and procedural characteristics. The mean age was 80 ± 6 years. The mean CHA₂DS₂-VASC and HAS-BLED scores were 5 ± 1 and 4 ± 1, respectively. Most patients (63.9%) were on treatment with acenocoumarol (Table 1) when the ICH occurred. Closure of LAA was successful in 95.7% of patients (45/47). Two patients developed complications during the procedure or during their hospital stay (Table 1). The most-used device was the Watchman implant (51.1%). Closure was performed at a median of 8 months [range, 3-20 months] after ICH. In 11 patients (23.4%), closure was before 3 months (early). No significant differences between the early and delayed (> 3 months) closure groups were found.

Median follow-up was 28 months [15-48 months]; 1 patient had an ischemic stroke with no sequelae and 1 patient had a cortical hemorrhage secondary to amyloid angiopathy. No patients died of procedure-related causes (Table 2). On the follow-up transesophageal echocardiogram, 1 patient had a device thrombus (which resolved after 1 month of treatment with low-molecular weight heparin). No patients died of device-related causes.

This study demonstrates the safety and efficiency of LAA closure in patients with an indication for OACs due to NVAF with a history of ICH. It contains the largest number of patients in a published series on this subject to date. Even with the influence of our learning curve, the procedure had a high success rate (> 95%) and a low complication rate. In addition, LAA closure was performed in the first 3 months after ICH (early) in almost 25% of patients, without complications, demonstrating its safety. At follow-up, 1 patient had an ischemic stroke (with no sequelae) at 3 years, and another patient had a cortical hemorrhage at 2 years postprocedure, secondary to amyloid angiopathy. Both were on treatment with aspirin 100 mg/d.

Fahmy et al.⁶ recently published a series of 24 patients with NVAF and a history of ICH who underwent LAA closure, also with a high success rate. Compared with our study, the time between ICH and LAA closure was longer (30 ± 48 months) and the follow-up time was shorter (11.9 ± 13.3 months).

Although this is an observational, single-center study with a small number of patients, it has the largest number of patients in a published series on this subject to date.

In conclusion, percutaneous LAA closure is safe and effective in patients with an indication for long-term anticoagulation for NVAF and a history of ICH, in the mid- to long-term.

FUNDING

This study was conducted as part of an intensified research activity program (Castile and León Regional Health Authority, Spain).

CONFLICTS OF INTEREST

I. Cruz-González is a proctor for St. Jude Medical and Boston Scientific.

Ignacio Cruz-González,^{a,◇} Juan C. Rama-Merchan,^{a,b,◇,*} Sandra Martínez-Peralta,^c Luis López-Mesonero,^c Javier Rodríguez-Collado,^a and Pedro L. Sánchez^a

^aDepartamento de Cardiología, Hospital Universitario de Salamanca, Instituto de Investigación Biomédica de Salamanca (IBSAL), Salamanca, Spain

^bDepartamento de Cardiología, Complejo Hospitalario de Mérida, Badajoz, Spain

^cDepartamento de Neurología, Hospital Universitario de Salamanca, Instituto de Investigación Biomédica de Salamanca (IBSAL), Salamanca, Spain

◇Ignacio Cruz-González and Juan C. Rama-Merchan have contributed equally and both should be considered the first author.

* Corresponding author:

E-mail address: ramamerchan@hotmail.com (J.C. Rama-Merchan).

Available online 5 October 2016

REFERENCES

1. January CT, Wann LS, Alpert JS, et al. 2014 AHA/ACC/HRS guideline for the management of patients with atrial fibrillation: executive summary: a report of the American College of Cardiology/American Heart Association Task Force on practice guidelines and the Heart Rhythm Society. *Circulation*. 2014;130:2071–2104.
2. Grysiewicz R, Gorelick PB. Incidence, mortality, and risk factors for oral anticoagulant-associated intracranial hemorrhage in patients with atrial fibrillation. *J Stroke Cerebrovasc Dis*. 2014;23:2479–2488.
3. Vermeer SE, Algra A, Franke CL, Koudstaal PJ, Rinkel GJ. Long-term prognosis after recovery from primary intracerebral hemorrhage. *Neurology*. 2002;59:205–209.
4. Hemphill JC, 3rd, Greenberg SM, Anderson CS, et al. Guidelines for the management of spontaneous intracerebral hemorrhage: a guideline for healthcare professionals from the American Heart Association/American Stroke Association. *Stroke*. 2015;46:2032–2060.
5. Holmes Jr DR, Doshi SK, Kar S, et al. Left atrial appendage closure as an alternative to warfarin for stroke prevention in atrial fibrillation: a patient-level meta-analysis. *J Am Coll Cardiol*. 2015;65:2614–2623.
6. Fahmy P, Spencer R, Tsang M, Gooderham P, Saw J. Left atrial appendage closure for atrial fibrillation is safe and effective after intracranial or intraocular hemorrhage. *Can J Cardiol*. 2016;32:349–354.

<http://dx.doi.org/10.1016/j.rec.2016.08.010>
1885-5857/

© 2016 Sociedad Española de Cardiología. Published by Elsevier España, S.L.U. All rights reserved.

Selection of the Best of 2016 on Aortic Valve Disease and Heart Failure in Elderly Patients



Selección de lo mejor del año 2016 en valvulopatía aórtica e insuficiencia cardíaca en el paciente anciano

To the Editor,

Severe aortic stenosis (AS) is a condition with poor prognosis that predominantly affects the elderly. There is little real-life information on its treatment and prognosis. Accordingly, the data from the IDEAS registry,¹ coordinated by the Geriatric Cardiology Section of the Spanish Society of Cardiology, are particularly timely. This multicenter registry included 726 consecutive patients with severe AS and a mean age of 77 years, with a 1-year follow-up. The most frequent treatment was conservative (65%), followed by aortic valve replacement (27%) and transcatheter aortic valve implantation (TAVI) (8%), with 1-year survival rates of 76%, 95%, and 93%, respectively (Figure 1). These data confirm the need for intervention in patients with severe symptomatic AS and highlight the relatively infrequent use of such procedures. Notably, the intervention rates in this registry were significantly lower when the patients were managed in nontertiary centers. Further important results were provided by the recently published PARTNER 2 trial.² In that study, 2032 patients with severe AS and intermediate surgical risk were randomized to TAVI (76.3% transfemoral access, 23.7% transthoracic access) or aortic valve surgery. The primary endpoint (death from any cause or disabling stroke at 2 years) was similar in the 2 groups ($P = .001$ for noninferiority). The primary endpoint occurred in 19.3% of the patients in the TAVI group and in 21.1% of the patients in the surgical group (TAVI group, hazard ratio [HR], 0.89; 95% confidence interval [95%CI], 0.73–1.09, $P = .25$). Notably, there was a significant reduction in the primary endpoint with the transfemoral approach vs surgery (HR, 0.79, 95%CI, 0.62–1.00; $P = .05$), but there was no significant difference with transthoracic access. Other benefits of TAVI were a greater aortic area and a lower frequency of acute kidney

injury, life-threatening bleeding, and atrial fibrillation. Surgery was associated with a lower rate of vascular complications and residual aortic regurgitation. This study vindicates the widespread practice in many Spanish groups characterized by TAVI in elderly patients with AS and intermediate risk.

The importance of geriatric factors such as functional status, frailty, dependency, and comorbidity in elderly patients with heart failure (HF) is well known.³ Accordingly, the work of Vidán et al.⁴ is particularly interesting. This study highlights the importance of frailty detection in elderly patients hospitalized for HF because frailty—apart from being highly prevalent, even

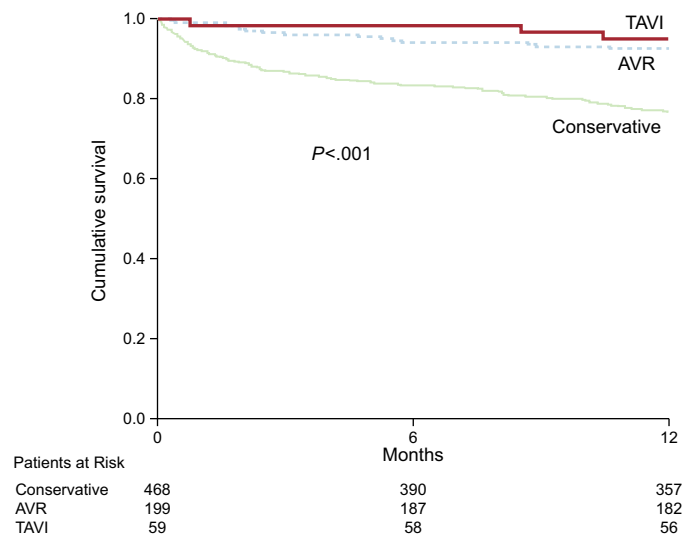


Figure. Cumulative survival in the IDEAS registry¹ according to the type of treatment performed: conservative, aortic valve replacement (AVR), or transcatheter aortic valve implantation (TAVI). Adapted with permission from González-Saldivar et al.¹