

Rupture and Intracoronary Entrapment of an Angioplasty Guidewire With the X-Sizer Thromboatherectomy Catheter During Rescue Angioplasty

José R. López-Mínguez, Eugenio Dávila, Manuel Doblado, Antonio Merchán, Reyes González, and Francisco Alonso

Unidad de Hemodinámica y Cardiología Intervencionista, Hospital Universitario Infanta Cristina, Badajoz, Spain.

The X-Sizer thromboatherectomy catheter represents an important advance for thrombectomy in thrombus-containing lesions, especially in patients who require primary and rescue angioplasty. Although it is safe, some complications have been reported as its use becomes more widespread. To our knowledge, the intracoronary breakage and retention of the angioplasty guidewire has not been reported. We describe a case of this rare complication and analyze the causes, prevention and treatment alternatives.

Key words: Angioplasty. Reperfusion. Atherectomy. Thrombus.

Full English text available at: www.revespcardiol.org

Rotura y atrapamiento intracoronario de una guía de angioplastia con el extractor de trombos X-Sizer en una angioplastia de rescate

El extractor de trombos X-Sizer supone un importante avance en el tratamiento de las lesiones coronarias con un elevado contenido trombótico y, especialmente, en el contexto de la angioplastia coronaria transluminal percutánea (ACTP) primaria y de rescate. Aunque es bastante seguro, se han comunicado algunas complicaciones asociadas a su uso; sin embargo, hasta donde conocemos, no se ha descrito ningún caso de rotura de la guía intracoronaria durante su utilización. Describimos un caso de esta rara complicación y analizamos sus causas, prevención y alternativas de tratamiento.

Palabras clave: Angioplastia. Reperusión. Aterectomía. Trombo.

INTRODUCTION

Thrombus-containing lesions continue to be a challenge in percutaneous coronary interventions, particularly in acute myocardial infarction (AMI). The use of direct stenting, which avoids application of high-pressure inflation, and administration of abciximab have proved to be beneficial in primary percutaneous transluminal coronary angioplasty (PTCA). Outcome is poorer in rescue PTCA, with TIMI III flow in 68% to 88% of patients, lower rates than those obtained in primary PTCA. Associated admi-

nistration of abciximab is also beneficial in these patients, but results in a higher incidence of major bleeding complications, ranging from 3.5% to 30%.¹ This fact, together with the approximately 36% failure rate of thrombolytic therapy makes rescue PTCA a technique that would certainly benefit from devices designed to improve the outcome of percutaneous coronary interventions in lesions with a high thrombus burden.^{2,3} One such device, the X-Sizer atherectomy and thrombectomy catheter system (Endicor Medical, San Clemente, CA, USA), has gained a high degree of acceptance. Despite its efficacy, the use of this device is not free from potential complications, which are being reported as its application becomes more widespread. To our knowledge, breakage of the coronary guidewire during use has not been previously described. We present a case of this complication and describe the treatment subsequently applied. An analysis of the possible causes of this complication and its prevention is also provided.

Correspondence: Dr. J.R. López-Mínguez.
Adelardo Covarsí, 1, 6.º D. 06005 Badajoz, España.
E-mail: jrlmiguez@telefonica.net

Received 21 August, 2003.
Accepted for publication 13 November, 2003.

ABBREVIATIONS

PTCA: percutaneous transluminal coronary angioplasty.

RCA: right coronary artery.

AMI: acute myocardial infarction.

CASE HISTORY

A 41-year-old man was admitted to the hospital with inferior AMI of 3 hours' duration. He was given thrombolytic therapy with rt-PA. Since the pain persisted and there were no signs of reperfusion one hour later, coronary angiography was performed. An occlusive thrombotic lesion was found in the distal portion of the right coronary artery (RCA) (Figure 1A). A 300-cm Balance Middle Weight (BMW) guidewire (Guidant Corp., Santa Clara, CA, USA) was inserted and a 1.5-mm X-Sizer atherectomy device was used (Figure 1B). As the device advanced, the artery opened and a critical lesion with a large thrombus bur-

den was observed in the bifurcation of the distal RCA. Diffuse displacement of the thrombus toward the middle and proximal third of the RCA was produced (Figure 1C), requiring numerous "push and pull" maneuvers with the device. In one of them the guidewire was nicked at the distal end of the device. An attempt was made to gently withdraw the guidewire, but it broke as the result of fracture and impact in the distal branch of the RCA. The proximal fragment remained 2 cm outside the ostium, in the aortic root (Figure 1D). This portion of the wire was caught with a snare catheter, but when pulled back, a 2-cm to 3-cm piece of the most proximal end broke off and the greater part of the guidewire remained, probably unraveled, along the entire length of the coronary up to 1 or 2 cm outside the coronary ostium. Attempts were made to snare the broken guidewire with a second guidewire, without success. In order to avoid later thrombosis of the vessel, we decided to seal the fragment of broken guidewire to the coronary wall with stents. Three Penta stents—4 13, 3.5 38, and 3 33 (Guidant Corp., Santa Clara, CA, USA)—and one 2.5 18 Pixel stent (Guidant Corp., Santa Clara, CA, USA) were placed from top to bottom. The outcome of this measure was TIMI II flow in the open vessel and temporary occlu-

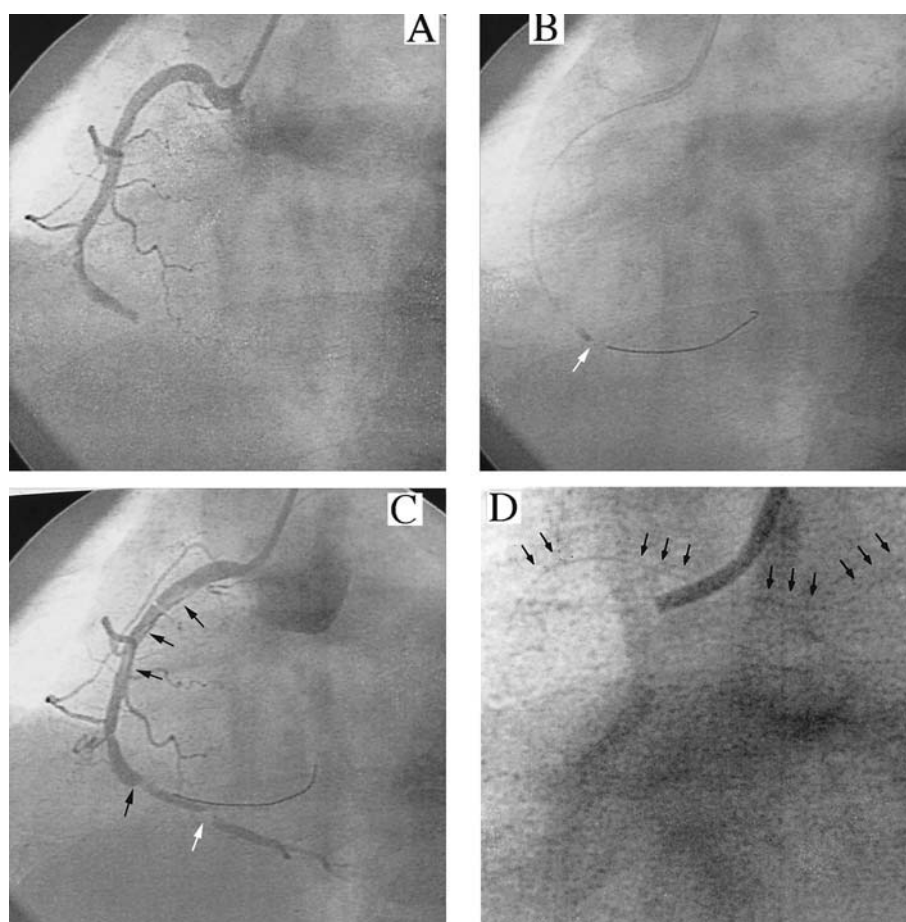


Fig. 1. A: occlusion of the distal RCA. B: X-sizer atherectomy catheter advancing in the distal third (white arrow). C: the lesion is open, but there is secondary displacement of the thrombus to the proximal and middle third (black arrows). The causative lesion is in the distal RCA (white arrow). D: detail of the proximal third of the broken guidewire extending 2-3 cm into the aortic root (arrows).

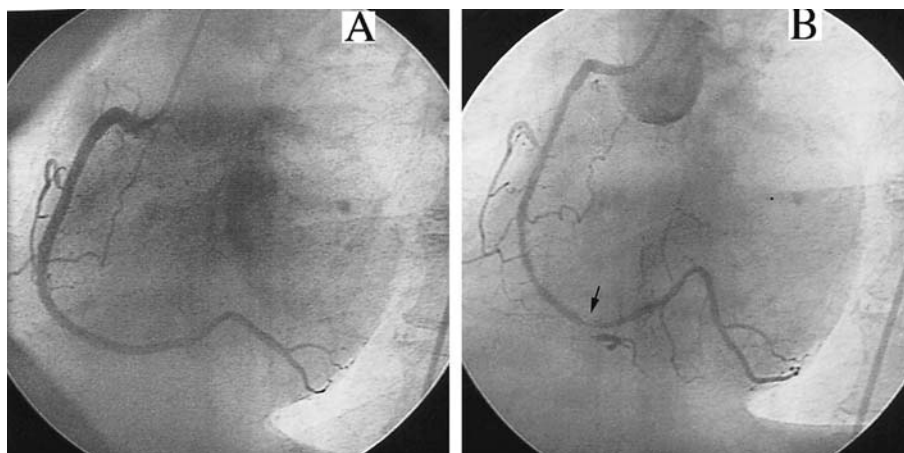


Fig. 2. A: final outcome of the RCA after stent placement from the ostium to the lesion. B: RCA is totally patent at the 4-month follow-up. Restenosis of the 2.5 18 Pixel stent is evident (arrow).

sion of the posterior descending branch, due to involvement of its ostium (Figure 2A). The patient was asymptomatic after PTCA. At four months he remained asymptomatic and follow-up coronary arteriography was performed. The vessel was patent with normal flow, although there was evidence of restenosis of the distal stent (2.5 18 Pixel; Figure 2B). Left ventricular ejection fraction was preserved at 53%, and there was slight left ventricular wall hypokinesia. The intrastent restenosis was redilated with a balloon, with favorable results.

DISCUSSION

Over the past 2 years several reports in limited series of patients have described successful use of the X-sizer to extract thrombotic lesions. Many of these series include AMI patients.⁴⁻⁶ Generally, these studies report a higher percentage of patients with rapid ST segment resolution as compared to the controls (83% vs 52%), and better grades of myocardial blush.^{6,7} The main problems encountered are the following: *a*) the lesion could not be reached in approximately 15% of cases, particularly in tortuous vessels, distal lesions or in those the device could not cross;^{2,4} *b*) the thrombus or occlusive debris could not be aspirated in approximately 11%;⁴ *c*) lesions to the vessel, including dissection or perforation, occurred in 1-5%,^{2,4,8} and *d*) the thrombus was displaced, causing an embolism in 47%.^{2,9} To our knowledge, guidewire breakage with this device has not been reported. In our case the problem began after the occlusion was opened, when the thrombus migrated to the proximal third of the vessel: although embolism usually occurs distally in these patients, proximal embolism has also been described with other devices, such as the RESCUE thrombectomy catheter.³ The need to perform several maneuvers with the device, as well as the possibility of inadvertently reaching the less durable part of the guidewire (since the lesion was distal), might have

been the mechanism causing the fracture, with later unraveling when withdrawal was attempted. The choice of the long guidewire available at that time might have been another causative factor, since it is preferable to use somewhat stiffer guidewires than the BMW wire. The rigidity of the system used at that time might also have contributed to the breakage. In this respect, improvements to make the device more flexible and easier to navigate will surely contribute to avoiding this rare complication.

Guidewire breakage is an infrequent complication, occurring in 0.2% of PTCAs, and it is more common in procedures using rotablator-type devices. Several case studies have described various solutions to solve the problem of a broken guidewire in a coronary artery,¹⁰⁻¹¹ ranging from surgery to simply leaving the segment of wire in place in cases where it could not be removed. However, this latter option carries some risk of occlusion, except in vessels that are already occluded or in very small branches. In our case, the only way to eliminate the wire fragment from the lumen and avoid the risk of right coronary thrombosis was to seal it to the vessel wall with the use of stents. Since this option also implied a risk of complications, angiographic monitoring was done at four months. The artery was found to be completely patent, indicating that the approach chosen had a favorable outcome.

We believe it is important to keep this potential complication in mind, particularly in cases that require repeated maneuvers with the device to aspirate the thrombus and in distal lesions. The current use of stiffer guidewires and more flexible devices will surely reduce the probability that this complication will occur.

REFERENCES

1. Ronner E, van Domburg RT, van den Brand MJ, de Feyter PJ, Foley DP, van der Giessen WJ, et al. Platelet GP IIb/IIIa receptor blockers for failed thrombolysis in acute myocardial infarction, alone or as adjunct to other rescue therapies; single centre retrospective analysis of 548 consecutive patients with acute myocardial infarction. *Eur Heart J* 2002;23:1529-37.
2. Ischinger T. X-Sizer Study Group. Thrombectomy with the X-Sizer catheter system in the coronary circulation: initial results from a multi-center study. *J Invasive Cardiol* 2001;13:81-8.
3. López-Palop R, Pinar E, Lozano I, Carrillo P, Saura D, Cortés R, et al. Resultados angiográficos del empleo de dos nuevos dispositivos de trombectomía en lesiones coronarias con elevado contenido trombótico. *Rev Esp Cardiol* 2003;56:271-80.
4. Constantinides S, Lo TS, Been M, Shiu MF. Early experience with a helical coronary thrombectomy device in patients with acute coronary thrombosis. *Heart* 2002;87:455-60.
5. Moreno R, García E, Acosta J, López-Sendón JL. Tratamiento del infarto agudo de miocardio mediante el dispositivo X-Sizer de trombectomía coronaria. *Rev Esp Cardiol* 2001;54:793-6.
6. Beran G, Lang I, Schreiber W, Denk S, Stefenelli T, Syeda B, et al. Intracoronary thrombectomy with the X-Sizer catheter system improves epicardial flow and accelerates ST-segment resolution in patients with acute coronary syndrome: a prospective, randomized, controlled study. *Circulation* 2002;105:2355-60.
7. von Korn H, Scheinert D, Bruck M, Bremer J, Flachskampf FA, Klinghammer L, et al. Initial experience with the Endicor X-Sizer thrombectomy device in patients with ST segment elevation myocardial infarction. *Z Kardiol* 2002;91:466-71.
8. Sanmartin M, Goicolea J, Ruiz-Salmerón R, Mantilla R, Sterling J, Meneses D, et al. Coronary perforation as a potential complication derived from coronary thrombectomy with the X-Sizer device. *Catheter Cardiovasc Interv* 2002;56:378-82.
9. Kwok OH, Prpic R, Gaspar J, Mathey DG, Escobar A, Goldar-Najafi A, et al. Angiographic outcome after intracoronary X-Sizer helical atherectomy and thrombectomy: first use in humans. *Catheter Cardiovasc Interv* 2002;55:140-1.
10. Ojeda Delgado JL, Jiménez Mena M, Barrios Alonso V, Pena Tizón J, Fernández Sánchez-Villarán E, Hernández Madrid A, et al. Guide-wire rupture as a complication of coronary angioplasty. Apropos 2 cases and a review of the literature. *Rev Esp Cardiol* 1992;45:141-4.
11. Patel T, Shah S, Pandya R, Sanghvi K, Fonseca K. Broken guide-wire fragment: a simplified retrieval technique. *Catheter Cardiovasc Interv* 2000;51:483-6.