

Image in cardiology

Role of Microvessels in Occlusive In-Stent Restenosis

Los microvasos en el tejido de la reestenosis oclusiva intra-stent

Nobuaki Suzuki, Ken Kozuma,* and Takaaki Isshiki

Department of Medicine, Teikyo University School of Medicine, Tokyo, Japan

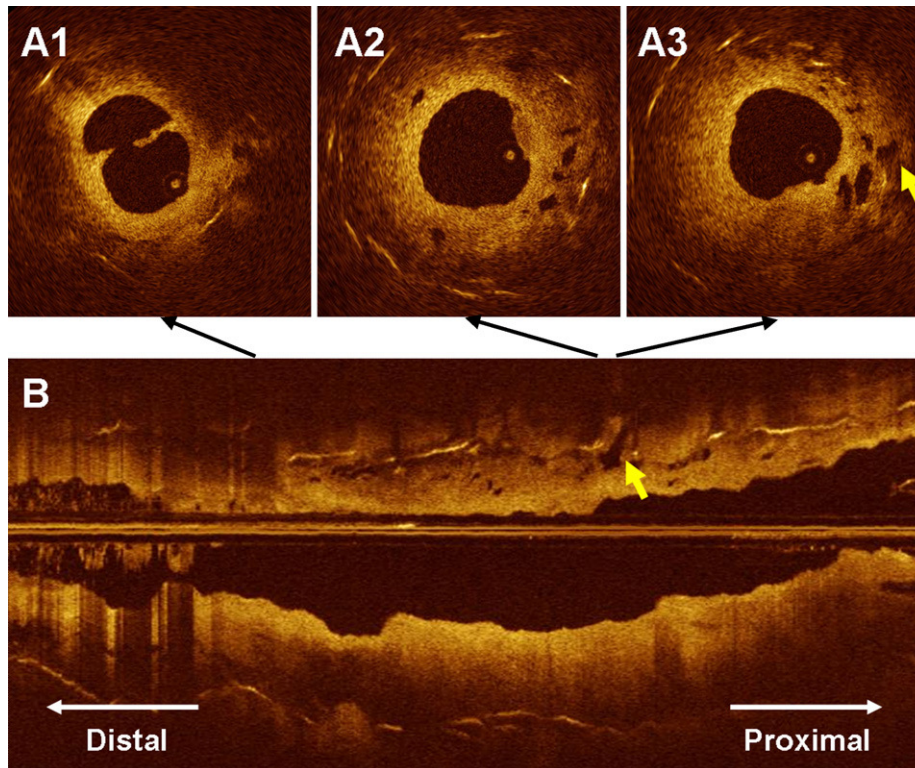


Figure 1.

A 71-year-old man underwent a percutaneous coronary intervention for an occlusive restenosis of a bare-metal stent implanted 7 years before in the left anterior descending coronary artery. The guidewire (Runthrough NSTM, Terumo, Tokyo, Japan) passed the target lesion smoothly. After a 1.5-mm balloon dilatation, optical coherence tomography (OCT) images were obtained by using M3× Cardiology Imaging SystemTM (LightLab Imaging, Inc., Westford, The US), and a 0.019-in. imaging wire (ImageWireTM, LightLab Imaging, Inc.) with automatic-pull back at 1 mm/s and 20 frames/s. An occlusion balloon catheter (HeliosTM, Avantec Vascular Corp., Sunnyvale, The US) was inflated proximally to the target segment, and the distal vessel was flushed with heparinized Ringer's Lactate. CypherTM stents (2.5 × 23 mm and 3.0 × 28 mm, Cordis, Miami, The US) were implanted after a 3.0 mm balloon dilatation. Thus, this patient was discharged without any complication.

At the restenotic tissue, OCT images revealed the dissection (Fig. A1) owing to the balloon dilatation and the microvessels (Fig. A2 and A3) which are the signal poor structures less than 200 microns in diameter that show a trajectory within the vessel. It has been observed that the microvessels are sometimes visible at OCT images of in-stent restenotic tissue. In this case, microvessels enabled the guidewire to pass the lesion smoothly. However, some of them showed the connection with the extra-stent tissue (Fig. A3 and B, arrow). This case reveals the entity of microvessels in occlusive restenotic tissue and the connection of the microvessel with the extra-stent tissue may facilitate the development of subintimal dissections.

* Corresponding author:
E-mail address: PXE00364@nifty.com (K. Kozuma).
Available online 11 March 2011