

Role of Echocardiography in the Detection and Prognosis of Ischemic Mitral Regurgitation

David Messika-Zeitoun, Siu Fung Yiu, Francesco Grigioni, and Maurice Enriquez-Sarano

Division of Cardiovascular Diseases, Mayo Clinic, Rochester, Minnesota, USA.

Ischemic mitral regurgitation (IMR) is mitral regurgitation (MR) due to complications of coronary artery disease and not fortuitously associated with it. Acute MR secondary to ruptured papillary muscle after myocardial infarction is rare and often fatal. We focus on functional MR, much more common, which occurs without any intrinsic valve disease. It was often underrated because of low murmur intensity but with the use of echocardiography this complication is observed between 15%-20% after a myocardial infarction. Recent advances in noninvasive Doppler echocardiography allow accurate assessment of regurgitant volume and effective regurgitant orifice and thus provide the tools to reliably evaluate the prognosis and mechanisms of IMR. IMR presence is associated with excess mortality. The mortality risk is directly related to the degree of regurgitation and a regurgitant volume ≥ 30 ml or an effective regurgitant orifice ≥ 20 mm² define a high-risk group. Presence and degree of the regurgitation are related to local left ventricular remodeling. The apical and posterior displacement of papillary muscles leads to excess valvular tenting which in turn, in association with loss of systolic annular contraction, determines the severity of the regurgitation. In current clinical practice, IMR is mainly corrected by ring annuloplasty. However, this technique does not correct local alterations of left ventricular remodeling and its benefits on long-term outcome remains to be demonstrated.

Key words: *Mitral valve. Regurgitation. Remodeling. Papillary muscle. Myocardial infarction. Prognosis.*

Full English text available at: www.revespcardiol.org

Based on a presentation at the X International Symposium on Ischemic Heart Disease, Bilbao, Spain 22-24 May 2002.

Dr. Messika-Zeitoun was supported by a grant from the Federation Française de Cardiologie.

Correspondence: Dr. M. Enriquez-Sarano.
Division of Cardiovascular Diseases, Mayo Clinic,
200 First St. SW, MN 55905 Rochester, MN, USA.

Papel de la ecocardiografía en la detección y el pronóstico de la regurgitación mitral isquémica

La regurgitación mitral isquémica hace referencia a una regurgitación mitral producida por una serie de complicaciones de la enfermedad coronaria debidas a causas no fortuitas. La regurgitación mitral aguda secundaria a la rotura del músculo papilar después de un infarto de miocardio es poco habitual y a menudo de consecuencias graves. En este artículo nos centraremos en la regurgitación mitral funcional, que es mucho más habitual y tiene lugar sin la presencia de enfermedad valvular intrínseca. A menudo se ha subestimado su entidad clínica debido a la dificultad para diagnosticarla por la baja intensidad del soplo, pero con el uso de la ecocardiografía esta complicación se ha observado en un 15-20% de los pacientes después del infarto de miocardio.

Los recientes avances en la ecocardiografía Doppler permiten valorar con precisión el volumen regurgitante y el orificio regurgitante efectivo, proporcionando así las herramientas necesarias para evaluar de manera fiable el pronóstico y los mecanismos de la regurgitación mitral isquémica.

La presencia de regurgitación mitral isquémica se asocia con un índice elevado de mortalidad. El riesgo de mortalidad está directamente relacionado con el grado de regurgitación y un volumen regurgitante ≥ 30 ml o un orificio regurgitante efectivo ≥ 20 mm² definen a un grupo de alto riesgo. La presencia y el grado de regurgitación se relacionan con el remodelado ventricular izquierdo de tipo local. El desplazamiento apical y posterior de los músculos papilares lleva a un exceso de angulación valvular lo cual, asociado con la pérdida de contracción anular sistólica, determina la gravedad de la regurgitación. En la práctica clínica actual, la regurgitación mitral isquémica se corrige principalmente por medio de la anuloplastia. Sin embargo, esta técnica no corrige las alteraciones de tipo local del remodelado ventricular izquierdo, y sus efectos beneficiosos a largo plazo están todavía por demostrar.

Palabras clave: *Válvula mitral. Regurgitación. Remodelado. Músculo papilar. Infarto de miocardio. Pronóstico.*

INTRODUCTION

Ischemic mitral regurgitation (IMR) is mitral regurgitation (MR) due to complication of coronary disease and not fortuitously associated with it. Two types can be individualized. Acute MR secondary to ruptured papillary muscle is a rare but often fatal complication of myocardial infarction (MI) and will not be discussed here. We focus on functional MR, much more common, caused by ischemic myocardial alterations which occurs without any intrinsic valve disease.

QUANTITATIVE EVALUATION OF THE SEVERITY OF MITRAL REGURGITATION

IMR was often underrated because of poor sensibility of auscultation. Indeed, in contrast to organic mitral regurgitation in which there is a good correlation between the intensity of the systolic murmur and the degree of regurgitation, IMR is often silent. Echocardiography is now the method of choice for MR evaluation. Color flow imaging allows an easy visualization of the regurgitation and frequency of IMR is estimated between 15 and 20% after MI. However, if color imaging is very sensitive, it has major limitations for the assessment of severity of MR.^{1,2} We have previously demonstrated that color imaging overestimates the severity of the regurgitation. In 170 patients (58 with functional MR and 112 with organic MR) we prospectively evaluated the severity of MR by the regurgitant jet area obtained by color imaging and the regurgitant volume (RVol)/regurgitant fraction measured by quantitative Doppler and quantitative two-dimensional echocardiography. Quantitative Doppler is

based on measurement of mitral and aortic stroke volumes and quantitative two-dimensional echocardiography on left ventricular end-diastolic and end-systolic volumes (calculated by the biplane method of disks). Patients with functional MR had larger jet area (10.6 ± 5.3 vs 8.2 ± 5.3 cm²; $P=.0006$) but smaller RVol (28 ± 14 vs 55 ± 46 ml; $P=.004$). Thus, same jet areas correspond to smaller RVol in functional MR than in organic MR. In addition to the 2 above mentioned methods, the Proximal Isovelocity Surface Area (PISA) provides a third quantitative method to evaluate the severity of the regurgitation. The PISA method is based on analysis of the flow convergence proximal to the regurgitant orifice.³ This method is simple, fast reproducible and has been proven reliable by multiple investigators.^{3,4} The three methods allow evaluating the RVol, which indicates the volume overload induced by MR, and the effective regurgitant orifice (ERO), which measures the severity of anatomic lesions. An example of calculations of RVol and ERO using the PISA method is presented in Figure 1. ERO is the ratio of regurgitant flow ($2 \times \pi \times$ radius of the flow convergence² \times aliasing velocity) and peak regurgitant velocity. The RVol is calculated as follow: $RVol=ERO \times MR$ TVI. These quantitative methods provide the tools to reliably evaluate the prognosis and mechanisms of IMR.

PROGNOSIS OF ISCHEMIC MITRAL REGURGITATION

Pioneering series have underscored the prognosis significance of IMR.⁵⁻⁷ In the acute phase of MI, IMR was frequent and carried an adverse prognosis but the acute MI by itself could have influenced the results.

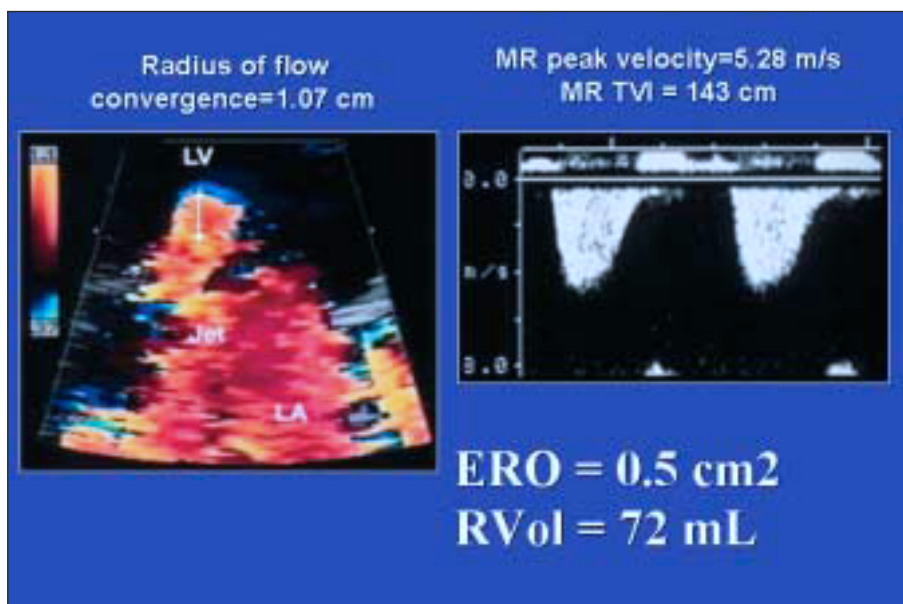


Fig. 1. Quantification of MR by the PISA method. ERO is the ratio of the regurgitant flow ($2 \times \pi \times$ radius of the flow convergence² \times aliasing velocity) and the peak regurgitant velocity. RVol is calculated as follow: $RVol=ERO \times MR$ TVI. LV indicates left ventricle; LA, left atrium.

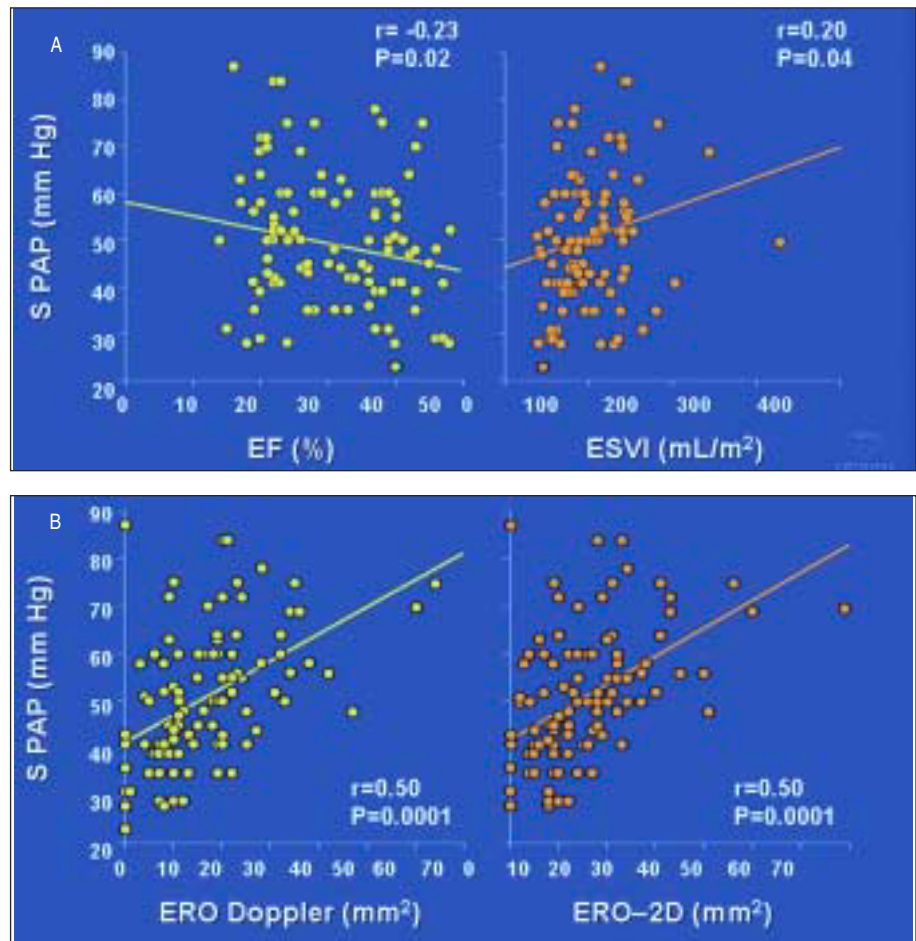


Fig. 2. Determinants of systolic pulmonary artery pressure (PAP) (measured by Doppler echocardiography) in functional mitral regurgitation. Correlation between systolic PAP and ejection fraction (EF) (A, left graph), end-systolic volume index (ESVI) (A, right graph), and ERO (B) measured by quantitative Doppler and quantitative two-dimensional echocardiography. (Taken from Enriquez-Sarano M⁸.)

The SAVE study (Survival And Ventricular Enlargement) showed that mild MR was associated with high mortality. However, severity of MR was graded by angiography, the study excluded grade 3 or 4 MR and inclusion was limited to the 16 days after MI. Therefore the prognosis implication of large range of chronic IMR remained uncertain.

In a previous study, we have evaluated the consequences of IMR on hemodynamic (assessed by systolic pulmonary artery pressure (PAP) measured by Doppler).⁸ Although ejection fraction and end-systolic volume were significantly correlated to systolic PAP, correlations were extremely weak (Figure 2A). This result corroborates to the well-known poor correlation between ejection fraction and functional status. In contrast, systolic PAP was more strongly correlated to ERO (Figure 2B) and diastolic function (evaluated by the deceleration time). By multivariate analysis, these 2 variables were the strongest predictors of systolic PAP in association with age.

Recently, we have demonstrated that, in the chronic phase after MI, IMR presence was associated with excess mortality independently of all baseline

characteristics (age, gender, NYHA functional class, severity of the coronary disease...) and degree of ventricular dysfunction. At 5 years, survival of patients without mitral regurgitation was 61% but was only 38% in patients with MR ($P < .0001$) (Figure 3A). Even when the potential artificial ejection fraction increase due to MR was taken into account, IMR presence remained an independent predictor of mortality. Moreover, the mortality risk was directly related to the severity of the regurgitation. Patients with $RVol \geq 30$ mL/beat demonstrated higher mortality than those with $RVol < 30$ mL/beat (Figure 3B). Similarly, patients with $ERO \geq 20$ mm² displayed a higher mortality than those with $ERO < 20$ mm². Of note, ERO was a stronger prognostic indicator than RVol. Therefore, IMR presence and severity are significant predictors of mortality and these results suggest that patients with $RVol \geq 30$ mL/beat or $ERO \geq 20$ mm² should be more actively managed. This study also underlined that criteria for severe MR should be different for organic and ischemic MR. Thus, severe organic MR is defined by $RVol \geq 60$ mL/beat and $ERO \geq 40$ mm²,⁹ whereas values of 30 mL/beat and 20 mm² should be considered for ischemic MR.

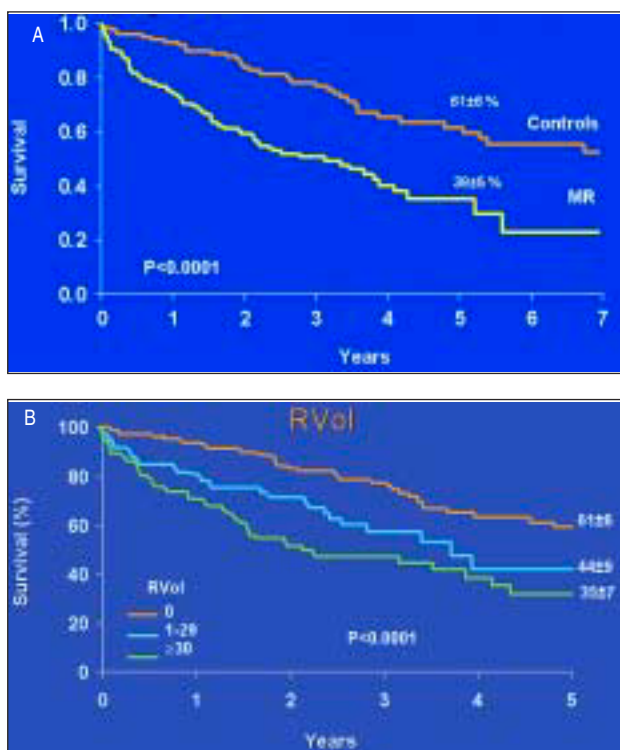


Fig. 3. Long term survival after diagnosis according to the presence of IMR (A) and the degree of MR graded by the RVol (B).

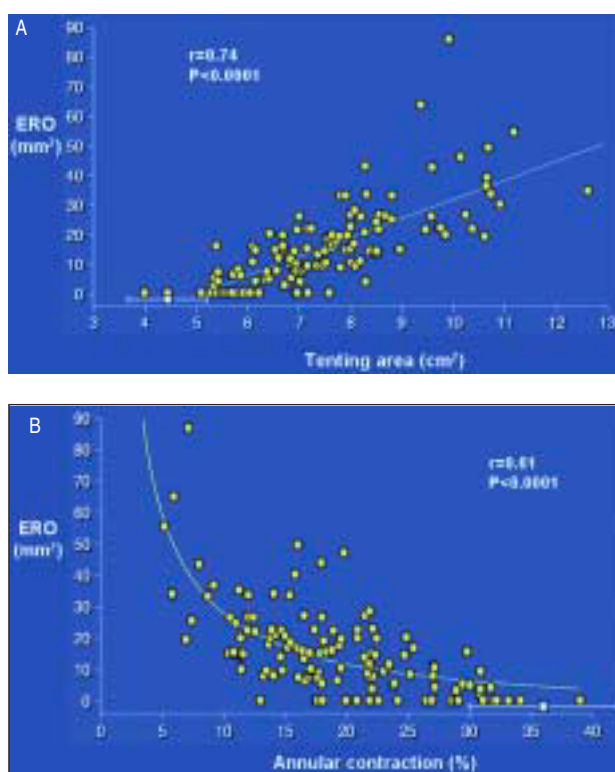


Fig. 4. Determinants of ERO in IMR. Correlation between ERO and valvular tenting area (A) and annular contraction (B).

MECHANISMS OF ISCHEMIC MITRAL REGURGITATION

IMR is not the result of organic mitral lesions but of incomplete closure of normal leaflets. Several mechanisms have been proposed to explain the occurrence of IMR. It is now clear that isolated ischemia of papillary muscle is insufficient to produce MR.^{10,11} Kaul and al demonstrated, in dogs, that selective ischemia of papillary muscle was ineffective to produce MR in contrast to global left ventricular ischemia. Conversely, left ventricular remodeling is of major importance. Several experimental studies or short series have suggested that more than left ventricular volume or ejection fraction, left ventricular shape was associated to IMR.¹²⁻¹⁵ Our group has recently demonstrated influence of local left ventricular remodeling on IMR. In 138 patients we prospectively evaluated: *a*) global left ventricular remodeling (volumes, stress and sphericity) and function; *b*) mitral valve deformation, and *c*) severity of the regurgitation. By multivariate analysis, main determinants of ERO were loss of annular contraction and mitral valve deformation or tenting (both $P<.0001$) (Figure 4A and 4B). This deformation is characterized by insufficient systolic leaflet body displacement toward the annulus, with coaptation limited to leaflet tips resulting in MR (Figure

5A to 5C). In turn, mitral tenting was directly determined by apical and posterior papillary muscle displacement. Global left ventricular size, sphericity, stress and systolic function had no or minimal additional independent association with the degree of IMR and tenting. Thus, in contrast to inferior MI, despite significant left ventricular enlargement, no MR is often observed in anterior MI because the relations between papillary muscles and mitral valve are not affected. This study also underlined the lack of influence of annular dilation on IMR. Ratio of leaflets to annular surface area is >2 ,¹⁶ and a considerable annular dilatation would be required to result in inadequate mitral coaptation. This was also nicely confirmed in a recent study.¹⁷ The authors compared annular size and degree of MR in 25 patients with lone atrial fibrillation and 24 patients with cardiomyopathy (ischemic or idiopathic). Although patients with atrial fibrillation and cardiomyopathy had similar annular size, significant MR only occurred in patients with cardiomyopathy. Therefore isolated annular dilatation does not cause significant MR. Animal experiments using three-dimensional echocardiography have also confirmed that IMR is related to changes of the geometry of the mitral valve apparatus and not to global left ventricular remodeling.^{18,19}

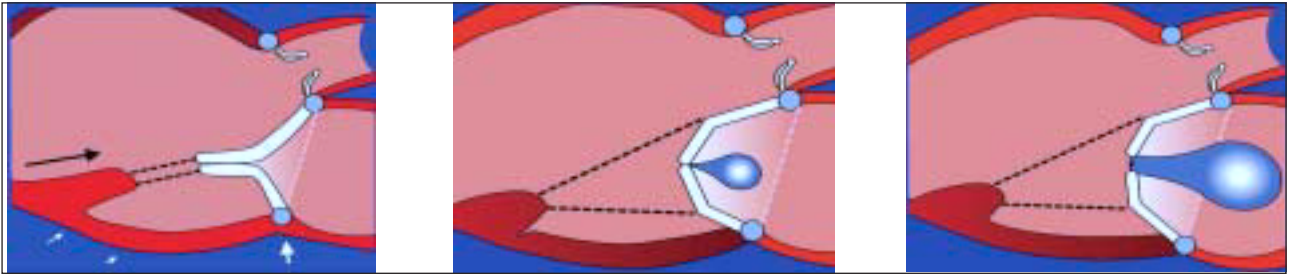


Fig. 5. Schematic representation of IMR mechanisms. Left: myocardial infarction without local left ventricular remodeling: no MR. Middle: local left ventricular remodeling (apical and posterior displacement of papillary muscle) leading to mitral valve tenting and MR. Right: increase of MR by additional loss of annular contraction.

CONCLUSION

IMR is a frequent complication of coronary disease. Its presence and degree have major prognostic implications and underscore the importance of its detection and quantification. A regurgitant volume ≥ 30 mL/beat and an effective regurgitant orifice ≥ 20 mm² defined a subgroup at high risk of mortality, which should be actively managed. Degree of IMR is associated to the loss of annular contraction and the mitral valve deformation or tenting, which is determined by the degree of local remodeling (apical and posterior displacement of papillary muscle) independently of global left ventricular remodeling and function. To date mitral ring annuloplasty is applied to correct IMR, most of the time in association with coronary artery bypass. However, this technique is only directed at reducing the annular size alone and may be ineffective to prevent long term recurrence of MR and to improve survival. Surgical corrections aiming at specifically correcting local alterations of left ventricular remodeling to minimize tenting have been proposed²⁰⁻²³ and should be further investigated.

REFERENCES

- Enrriquez-Sarano M, Tajik A, Bailey K, Seward J. Color flow imaging compared with quantitative Doppler assessment of severity of mitral regurgitation: Influence of eccentricity of jet and mechanism of regurgitation. *J Am Coll Cardiol* 1993;21:1211-9.
- McCully R, Enrriquez-Sarano M, Tajik A, Seward J. Overestimation of severity of ischemic/functional mitral regurgitation by color Doppler jet area. *Am J Cardiol* 1994;74:790-3.
- Enrriquez-Sarano M, Miller FJ, Hayes S, Bailey K, Tajik A, Seward J. Effective mitral regurgitant orifice area: clinical use and pitfalls of the proximal isovelocity surface area method. *J Am Coll Cardiol* 1995;25:703-9.
- Vandervoort P, Rivera J, Mele D, Palacios I, Dinsmore R, Weyman A, et al. Application of color Doppler flow mapping to calculate effective regurgitant orifice area. An in vitro study and initial clinical observations. *Circulation* 1993;88:1150-6.
- Hickey M, Smith L, Muhlbaier L, Harrell FJ, Reves J, Hinohara T, et al. Current prognosis of ischemic mitral regurgitation. Implications for future management. *Circulation* 1988;78-I:51-9.
- Lehman K, Francis C, Dodge H. Mitral regurgitation in early myocardial infarction. Incidence, clinical detection, and prognostic implications. *Ann Intern Med* 1992;117:10-7.
- Tcheng J, Jackman J, Nelson C, Gardner L, Smith L, Rankin J, et al. Outcome of patients sustaining acute ischemic mitral regurgitation during myocardial infarction. *Ann Intern Med* 1992;117:18-24.
- Enrriquez-Sarano M, Rossi A, Seward J, Bailey K, Tajik A. Determinants of pulmonary hypertension in left ventricular dysfunction. *J Am Coll Cardiol* 1997;29:153-9.
- Dujardin K, Enrriquez-Sarano M, Bailey K, Nishimura R, Seward J, Tajik A. Grading of mitral regurgitation by quantitative Doppler echocardiography—calibration by left ventricular angiography in routine clinical practice. *Circulation* 1997;96:3409-15.
- Godley R, Wann L, Rogers E, Feigenbaum H, Weyman A. Incomplete mitral leaflet closure in patients with papillary muscle dysfunction. *Circulation* 1981;63:565-71.
- Kaul S, Spotnitz W, Glasheen W, Touchstone D. Mechanism of ischemic mitral regurgitation: an experimental evaluation. *Circulation* 1991;84:2167-80.
- Kono T, Sabbah HN, Rosman H, Alam M, Jafri S, Stein PD, et al. Mechanism of functional mitral regurgitation during acute myocardial ischemia. *J Am Coll Cardiol* 1992;19:1101-5.
- Sabbah HN, Kono T, Rosman H, Jafri S, Stein PD, Goldstein S. Left ventricular shape: a factor in the etiology of functional mitral regurgitation in heart failure. *Am Heart J* 1992;123(4 Pt 1):961-6.
- Kono T, Sabbah H, Rosman H. Left ventricular shape is the primary determinant of functional mitral regurgitation in heart failure. *J Am Coll Cardiol* 1992;20:1594-8.
- Kono T, Sabbah HN, Stein PD, Brymer JF, Khaja F. Left ventricular shape as a determinant of functional mitral regurgitation in patients with severe heart failure secondary to either coronary artery disease or idiopathic dilated cardiomyopathy. *Am J Cardiol* 1991;68:355-9.
- Brock R. The surgical and pathologic anatomy of the mitral valve. *Br Heart* 1952;14:489-513.
- Otsuji Y, Kumanoohoso T, Yoshifuku S, Matsukida K, Koriyama C, Kisanuki A, et al. Isolated annular dilation does not usually cause important functional mitral regurgitation: comparison between patients with lone atrial fibrillation and those with idiopathic or ischemic cardiomyopathy. *J Am Coll Cardiol* 2002;39:1651-6.
- Otsuji Y, Handschumacher M, Schwammenthal E, Jiang L, Song J, Guerrero J, et al. Insights from three dimensional echocardiography into the mechanism of functional mitral regurgitation. *Circulation* 1997;96:1999-2008.
- Otsuji Y, Handschumacher MD, Liel-Cohen N, Tanabe H, Jiang L, Schwammenthal E, et al. Mechanism of ischemic mitral regur-

- gitation with segmental left ventricular dysfunction: three-dimensional echocardiographic studies in models of acute and chronic progressive regurgitation. *J Am Coll Cardiol* 2001;37:641-8.
20. Messas E, Guerrero JL, Handschumacher MD, Conrad C, Chow CM, Sullivan S, et al. Chordal cutting: a new therapeutic approach for ischemic mitral regurgitation. *Circulation* 2001;104:1958-63.
 21. Liel-Cohen N, Guerrero JL, Otsuji Y, Handschumacher MD, Rudski LG, Hunziker PR, et al. Design of a new surgical approach for ventricular remodeling to relieve ischemic mitral regurgitation: insights from 3-dimensional echocardiography. *Circulation* 2000;101:2756-63.
 22. Hung J, Guerrero JL, Handschumacher MD, Supple G, Sullivan S, Levine RA. Reverse ventricular remodeling reduces ischemic mitral regurgitation: echo-guided device application in the beating heart. *Circulation* 2002;106:2594-600.
 23. Timek TA, Lai DT, Tibayan F, Liang D, Rodríguez F, Daughters GT, et al. Annular versus subvalvular approaches to acute ischemic mitral regurgitation. *Circulation* 2002;106(12 Suppl 1):I27-I32.