

Reversal of Protein-Losing Enteropathy After Heart Transplantation in Young Patients

Joaquín Rueda Soriano,^{a,b} Esther Zorio Grima,^{a,b} Miguel A. Arnau Vives,^{a,b} Ana Osa Sáez,^a Luis Martínez Dolz,^a Luis Almenar Bonet,^a Miguel A. Palencia Pérez,^a and Antonio Salvador Sanz^a

^aServicio de Cardiología, Hospital Universitario La Fe, Valencia, Spain.

^bRed RECAVA (Fondo de Investigación Sanitaria Carlos III), Madrid, Spain.

Protein-losing enteropathy is a rare but life-threatening complication that occurs in some patients who develop intestinal lymphangiectasia secondary to increased systemic venous pressure. Although different forms of treatment have been tried, with varying results, the majority were reported to be unsuccessful. The aim of this study was to demonstrate that heart transplantation may be an appropriate therapeutic option for patients who do not respond to medical treatment. At our center, we performed heart transplantations in 3 patients with this condition. The mean follow-up period was 11(2) months. No patient died and the enteropathy regressed in all 3.

Key words: Protein-losing enteropathy. Heart transplantation. Adult congenital heart disease.

Resolución de enteropatía pierdeproteínas tras el trasplante cardiaco en pacientes jóvenes

La enteropatía pierdeproteínas es una infrecuente pero muy grave complicación que aparece en determinados pacientes que desarrollan linfangiectasia intestinal secundaria a un incremento de la presión venosa sistémica. Se han descrito diferentes tratamientos, con resultados dispares y en la mayoría de las ocasiones sin respuesta favorable. El objetivo del estudio es mostrar el trasplante cardiaco como una opción terapéutica adecuada para pacientes sin respuesta positiva al tratamiento médico. En nuestro centro se ha trasplantado a 3 pacientes con estas características, con un seguimiento medio de 11 ± 2 meses. Ningún paciente falleció y en todos ellos se documentó una reversibilidad de la enteropatía.

Palabras clave: Enteropatía pierdeproteínas. Trasplante cardiaco. Cardiopatías congénitas del adulto.

INTRODUCCIÓN

Protein-losing enteropathy (PLE) is a severe intestinal loss of proteins that leads to a clinical picture characterized by abdominal pain, diarrhea, hypoproteinemia, and hypoalbuminemia, hypogammaglobulinemia, lymphocytopenia, and hypocalcemia.¹ High concentrations of α_1 -antitrypsin in fecal clearance confirm diagnosis.

This loss of proteins occurs in diseases with ulceration of the intestinal mucosa, inflammatory-immune diseases, and diseases that lead to lymphatic vessel abnormalities. Lymphatic vessel abnormalities include intestinal lymphangiectasia caused by predominantly right congestive heart failure (as

occurs in patients undergoing a Fontan procedure and in arrhythmogenic right ventricular dysplasia).

Treatment is difficult and several strategies have been described,²⁻⁵ with conflicting results and, in most cases, without favorable medium-term outcomes. The prognosis is poor, with mortality at 5 years greater than 40%.^{6,7}

The objective of the study was to demonstrate that heart transplantation is an appropriate therapeutic option in patients with severe PLE who are refractory to medical treatment.

METHODS

We present a series of 3 young patients with severe PLE who underwent heart transplantation for this indication. Diagnosis of PLE was confirmed with high concentrations of α_1 -antitrypsin in fecal clearance. All patients were exhaustively prepared prior to heart transplantation with γ -globulin transfusion, albumin, and adjustment of coagulation parameters.

Table 1 summarizes the baseline characteristics of the patients.

This study was funded in part with grants from the Instituto de Salud Carlos III (PI070831 and CP08/00326).

Correspondence: Dr. J. Rueda Soriano.
Convento, 3. 46111 Rocafort. Valencia. España.
E-mail: ximo@ipeuropa.com

Received September 15, 2008.

Accepted for publication November 24, 2008.

TABLE 1. Baseline Characteristics of the Patients

Case	Heart Disease	PLE Diagnosis, y	Clinical Picture Associated With PLE	Concentration of α_1 -AT	Pressures, mm Hg		
					RA	RV	PWP
1	AV canal: mitral prosthesis	10	Ascites, pleural effusion, melena, and abdominal pain	47.8 mg/g	20	39-18	18
2	ARVD	16	Ascites, pleural effusion, and peripheral edema	36.8 mg/g	13	20-12	12
3	Single ventricle. Fontan	13	Ascites, abdominal pain, and diarrhea	52.7 mg/g	18		

α_1 -AT indicates α_1 -antitrypsin in feces; ARVD, arrhythmogenic right ventricular dysplasia; AV, atrioventricular; PLE, protein-losing enteropathy; pressures, catheterization prior to heart transplantation; PWP, pulmonary wedge pressure; RA, right atrial; RV, right ventricular.

Case 1

The first patient was a 17-year-old girl diagnosed with atrioventricular canal defect. She had undergone surgery after 4 months of life, with closure of the septal defects. She underwent an additional intervention aged 6 years for mitral repair, which was complicated by a large tear in the right ventricle requiring repair with a Teflon patch. When she was 8-years-old, a mechanical mitral prosthesis (ATS 21) was implanted. The patient had right ventricular failure as conformed by echocardiography and cardiac magnetic resonance imaging. The mitral prosthesis showed good disc mobility but an obstructive behavior due to its small size. In July 2001, she was admitted for symptoms of anasarca, abdominal pain, and melena, and PLE was diagnosed. Since then, she has required repeated admissions for edema and pleural effusion, and was administered albumin and γ -globulins. She received treatment with corticosteroids and heparin, without favorable outcomes. Heart transplantation was done in August 2007.

Case 2

An 18-year-old man was diagnosed with arrhythmogenic right ventricular dysplasia, with severely depressed ventricular function. He had been a carrier of an implantable cardioverter-defibrillator since 2005 because of sustained ventricular tachycardia. The patient experienced progressive clinical deterioration, with resting dyspnea, ascites, ankle edema, and pleural and pericardial effusion. Diagnosis of PLE was confirmed at the age of 16 years. He was admitted on several occasions for administration of serum albumin. In July 2007, he underwent heart transplantation.

Case 3

The third patient was a 17-year-old boy with complex congenital heart defects comprising a single left ventricle and severe pulmonary stenosis. He underwent a Fontan procedure aged 5 years. He was

diagnosed with PLE aged 13 years, with recurrent episodes of abdominal pain and diarrhea. He was admitted on several occasions for administration of albumin, γ -globulins, and corticosteroids. The pressure in the Fontan system was 18 mm Hg, and no obstructions in the cavopulmonary connections were observed. During a meeting of surgeons and treating physicians, an atrioseptostomy was considered but, in view of the poor outcomes published⁵ and the poor clinical condition of the patient, it was decided to do a heart transplantation including the pulmonary trunk of the donor.

RESULTS

Clinical Outcomes

The 3 patients underwent heart transplantation without any serious complications in the first 48 hours. Patient 2 presented mediastinitis caused by *Staphylococcus aureus* in the second week after transplantation, with good response to antibiotics and surgery.

The mean period of follow-up was 11.2 (2) months. The immunosuppressant regimen and the clinical outcomes are indicated in Table 2. Patients 1 and 2 were diagnosed with an episode of grade IIIa rejection (first and third month post-transplant, respectively) which was asymptomatic.

Laboratory Outcomes

At the time of transplantation, the patients had very severe hypoalbuminemia, with a mean concentration of 2.2 g/dL (range, 2-2.6 g/dL) and lymphocytopenia with mean lymphocyte count of 320/ μ L (range, 200-400/ μ L). After transplantation, a progressive increase in both parameters was observed (Figure 1 and 2). Albumin concentrations were greater than 3 g/dL in the 3 patients from the third month onwards and, at the end of follow-up, the mean value was 3.9 mg/dL (3.7-4.1 mg/dL). Only patient 3 required albumin transfusion

TABLE 2. Clinical Outcome of the Patients

Case	Treatment Prior to HT	Age at HT	Immunosuppressants	Clinical Picture Associated With PLE after HT
1	Corticosteroids and heparin	16	Tacrolimus, deflazacort, and mycophenolate	Asymptomatic
2	Heparin	17	Tacrolimus, deflazacort, and mycophenolate	Asymptomatic
3	Corticosteroids	16	Cyclosporine, deflazacort, and mycophenolate	Asymptomatic

HT indicates heart transplantation; PLE, protein-losing enteropathy.

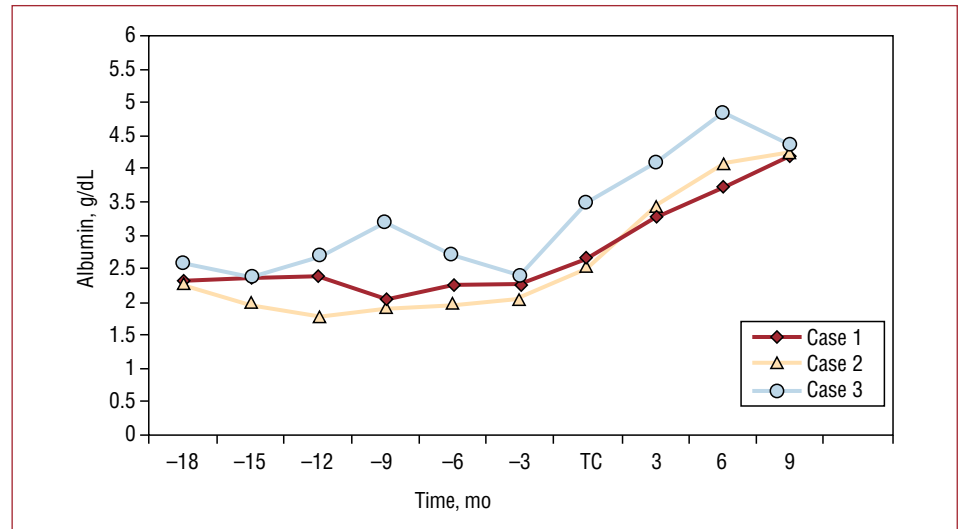


Figure 1. Serum albumin concentration before and after heart transplantation

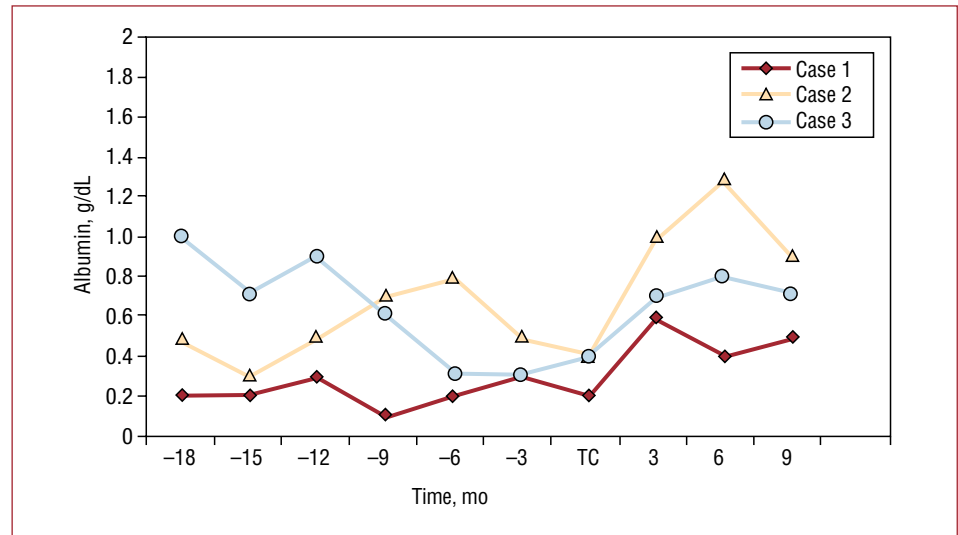


Figure 2. Serum lymphocyte count before and after heart transplantation.

during the first week after transplantation. The lymphocyte counts showed a significant increase during the first weeks, with a maximum between the fourth and fifth month. Subsequently, a small decrease was observed and at the end of follow-up, the mean count was 750/ μ L (550-1100/ μ L).

DISCUSSION

PLE is a disease characterized by excessive loss of proteins by the gastrointestinal tract,

leading to hypoproteinemia (hypoalbuminemia), hypogammaglobulinemia, and hypocalcemia.

This diagnosis should be considered in patients with congestive signs, abdominal pain, diarrhea, and the aforementioned laboratory abnormalities. Diagnosis is confirmed by high concentrations of α_1 -antitrypsin in fecal clearance.

The pathophysiology of PLE is still cause of debate.⁸ The underlying cause is chronic digestive loss of proteins due to an excessive and persistent pressure increase in the central venous system and portal system, with an increase in resistance to lymphatic

flow from the thoracic duct to general circulation. This leads to secondary intestinal lymphangiectasia. Nevertheless, cases of PLE with central venous pressure within normal limits, as well as persistence of the disease after performing atrioseptostomy⁵ or surgically normalizing the hemodynamic abnormalities have been reported.⁶ This persistence of PLE could be explained by a chronic inflammatory response in the digestive system.

The development of PLE is an uncommon but very serious complication.⁷ The 5-year mortality is reported to be greater than 40%.^{6,7} In the most advanced forms, medical treatment can only provide temporary improvement in symptoms, and so surgical correction of the hemodynamic abnormalities or heart transplantation are the only therapeutic options. In addition, these interventions should be done as soon as possible. In the Bernstein registry,⁹ which describes the outcome of patients who underwent prior Fontan surgery and were indicated for heart transplantation, 21% of those with PLE died while on the waiting list compared to 12% of those who were free of the disease.

Heart transplantation in these situations has been shown to be an appropriate therapy, although certain questions remain open to debate.^{6,9} First, there is a very high risk of severe complications in the immediate postoperative period given the very poor initial condition of the patients. In addition, most of these patients have undergone prior heart surgery, which implies a greater potential incidence of complications, especially bleeding, as well as greater technical difficulties during the procedure. There is also an increased risk of infections. In fact, protein loss is accompanied by hypogammaglobulinemia and lymphocytopenia with selective loss of CD3 and CD4.¹⁰ Secondly, it has been postulated that some changes in the digestive system may be irreversible and therefore will not respond after normalization of the hemodynamic parameters.

The first significant data on the outcomes of patients with PLE undergoing heart transplantation were published by Mertens et al.⁶ They found that heart transplantation was associated with high mortality (40%) and was not always accompanied by resolution of PLE. Subsequently, Jayakumar et al¹¹ presented similar results, with early mortality after heart transplantation of 40%, caused essentially by bleeding complications and infections. In contrast, in the studies by Bernstein et al,⁹ and Gamba et al,¹² the presence of PLE did not influence survival after transplantation, with reported survival at 1 month greater than 75%. These results are in agreement with that observed in our hospital. Probably, the

exhaustive preparation prior to heart transplantation has contributed to these good outcomes.

With regard to the laboratory outcomes, in all patients, albumin levels returned to normal, as reported in the recent studies.^{9,11,12} Lymphocytes also increased, but with a slight decrease from the fifth month and levels remained acceptable. This behavior is probably due to interaction with immunosuppressants.

In conclusion, we believe that heart transplantation is an appropriate therapy that resolves PLE in patients who do not respond to medical treatment and who are not susceptible to conventional surgery. In addition, despite the high risk of early complications after heart transplantation, these can be significantly reduced through an exhaustive preoperative preparation.

REFERENCES

- Escobar Castro H. Enteropatía pierde-proteínas. *An Esp Pediatr.* 2001;54:30-2.
- Facchini M, Guldenschuh I, Turina J, Jenni R, Schalcher C, Attenhofer Jost CH. Resolution of protein-losing enteropathy with standard high molecular heparin and urokinase after Fontan repair in a patient with tricuspid atresia. *J Cardiovasc Surg.* 2000;41:567-70.
- Bhagirath KM, Tam JW. Resolution of protein-losing enteropathy with low-molecular weight heparin in an adult patient with Fontan palliation. *Ann Thorac Surg.* 2007;84:2110-2.
- Therrien J, Webb GD, Gatzoulis MA. Reversal of protein losing enteropathy with prednisone in adults with modified fontan operations: long term palliation or bridge to cardiac transplantation? *Heart.* 1999;82:241-3.
- Vyas H, Driscoll D, Cabalka A, Cetta F, Hagler D. Results of transcatheter fontan fenestration to treat protein losing enteropathy. *Catheter Cardiovasc Interv.* 2007;69:584-9.
- Mertens L, Hagler DJ, Sauer U, Somerville J, Gewillig M. Protein-losing enteropathy after the Fontan operation: an international multicenter study. PLE study group. *J Thorac Cardiovasc Surg.* 1998;115:1063-73.
- Cazzaniga M, Fernández L, Vilagrà F, Pérez J, Gómez R, Sánchez P, et al. Operación modificada de Fontan o variantes efectuadas en un solo tiempo quirúrgico. Determinantes de la mortalidad. *Rev Esp Cardiol.* 2002;55:391-412.
- Ostrow AM, Freeze H, Rychik J. Protein-losing enteropathy after fontan operation: investigations into possible pathophysiologic mechanisms. *Ann Thorac Surg.* 2006;82:695-700.
- Bernstein D, Naftel D, Chin C, Addonizio LJ, Gamberg P, Blume ED, et al. Pediatric Heart Transplant Study. Outcome of listing for cardiac transplantation for failed Fontan: a multi-institutional study. *Circulation.* 2006;114:273-80.
- Chakrabarti S, Keeton BR, Salmon AP, Vettukattil JJ. Acquired combined immunodeficiency associated with protein losing enteropathy complicating Fontan operation. *Heart.* 2003;89:1130-1.
- Jayakumar KA, Addonizio LJ, Kichuk-Christant MR, Galantowicz ME, Lamour JM, Quaegebeur JM, et al. Cardiac transplantation after the Fontan or Glenn procedure. *J Am Coll Cardiol.* 2004;44:2065-72.
- Gamba A, Merlo M, Fiocchi R, Terzi A, Mammana C, Sebastiani R, et al. Heart transplantation in patients with previous Fontan operations. *J Thorac Cardiovasc Surg.* 2004;127:555-62.