

ECG Contest

Response to ECG, September 2017



Respuesta al ECG de septiembre de 2017

Pablo Robles Velasco,* Isabel Monedero Sánchez, and Roberto del Castillo Medina

Unidad de Cardiología, Hospital Universitario Fundación Alcorcón, Alcorcón, Madrid, Spain

Coronary angiography showed occlusion of the right coronary artery (RCA) that implicated the origin of a right ventricular branch (Figure A, arrow). The artery was opened and the electrocardiogram (ECG) showed correction of the ST abnormalities in the precordial leads (Figure B). Occlusion of the left coronary artery leads to an extensive subendocardial lesion with ST elevation in $aVR > V_1$. Simultaneous occlusion of the proximal left anterior descending artery would lead to generalized ST elevation in left precordial leads (answers 1 and 3, incorrect). The ECG is characteristic of acute inferior myocardial infarction with RCA and right ventricular involvement.¹ Simultaneous ST elevation in leads V_1 - V_3 suggests a differential diagnosis with occlusion of the distal left anterior descending artery where it passes over the cardiac apex. ST elevation in $V_1 > V_2 > V_3$ along with ECG showing RCA involvement differentiates the lesion from simultaneous occlusion of a right ventricular branch² (answer 2 incorrect; the correct answer is answer 4).

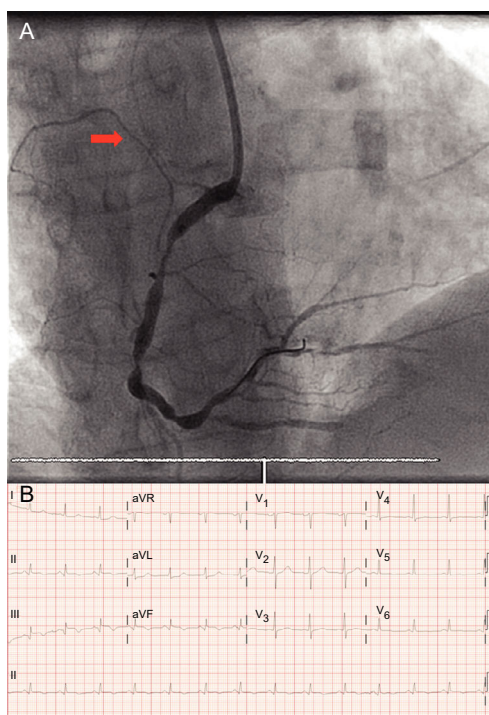


Figure.

REFERENCES

1. Robles P, Jimenez JJ. Working in reverse. *Am J Med.* 2006;119:1043-1044.
2. Alzand BSN, Gorgels APM. Combined anterior and inferior ST-segment elevation Electrocardiographic differentiation between right coronary artery occlusion with predominant right ventricular infarction and distal left anterior descending branch occlusion. *J Electrocardiol.* 2011;44:383-388.

SEE RELATED CONTENT:

<http://dx.doi.org/10.1016/j.rec.2017.02.016>

* Corresponding author:

E-mail address: problesve.pr@gmail.com (P. Robles Velasco).

<http://dx.doi.org/10.1016/j.rec.2017.02.015>

1885-5857/© 2016 Sociedad Española de Cardiología. Published by Elsevier España, S.L.U. All rights reserved.