

ECG Contest

Response to ECG, October 2016



Respuesta al ECG de octubre de 2016

Francisco Buendía Fuentes* and M. Asunción Hervás Botella

Servicio de Cardiología, Hospital Arnau de Vilanova, Valencia, Spain

The clinical characteristics of pain, absence of ultrasensitive troponin I elevation, and absence of dynamic changes in the serial ECG make it unlikely that the patient has acute coronary syndrome (answers 1 and 2). This conclusion was supported by coronary angiography, which showed a disease-free coronary tree. The diagnosis was confirmed using cardiac magnetic resonance imaging (Figure), which revealed asymmetric apical ventricular hypertrophy (answer 3), as shown in the Figure. Edema, ischemia, and myocardial necrosis were ruled out, as well as pericardial disease (answer 4).

Some cases of apical hypertrophic cardiomyopathy can be overlooked in echocardiography,¹ and ECG can show altered repolarization patterns,² sometimes distinct from the typical T wave inversion in precordial leads.

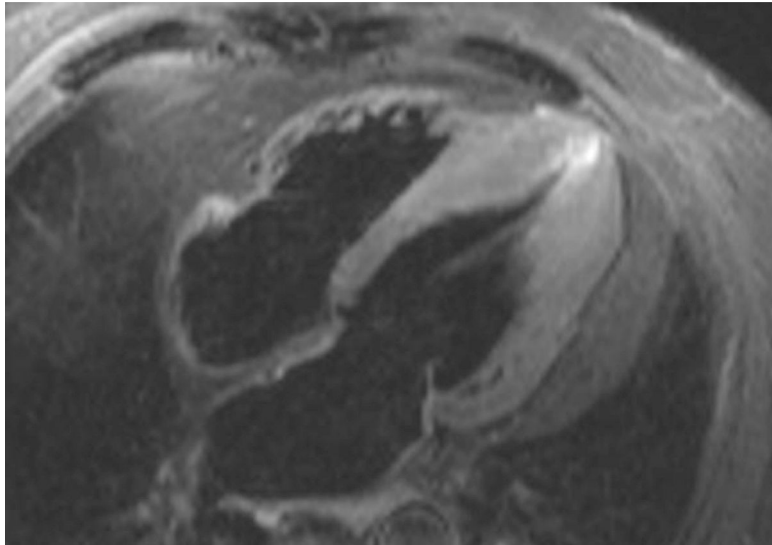


Figure.

REFERENCES

1. Parisi R, Mirabella F, Secco GG, Fattori R. Multimodality imaging in apical hypertrophic cardiomyopathy. *World J Cardiol.* 2014;26:916–23.
2. Flett AS, Maestrini V, Milliken D, Fontana M, Treibel TA, Harb R, et al. Diagnosis of apical hypertrophic cardiomyopathy: T-wave inversion and relative but not absolute apical left ventricular hypertrophy. *Int J Cardiol.* 2015;183:143–8.

SEE RELATED ARTICLE:

<http://dx.doi.org/10.1016/j.rec.2016.04.051>

* Corresponding author:

E-mail address: franciscobuendiafuentes@hotmail.com (F. Buendía Fuentes).

<http://dx.doi.org/10.1016/j.rec.2016.04.052>

1885-5857/© 2016 Sociedad Española de Cardiología. Published by Elsevier España, S.L.U. All rights reserved.