

ECG Contest

Response to ECG, January 2016

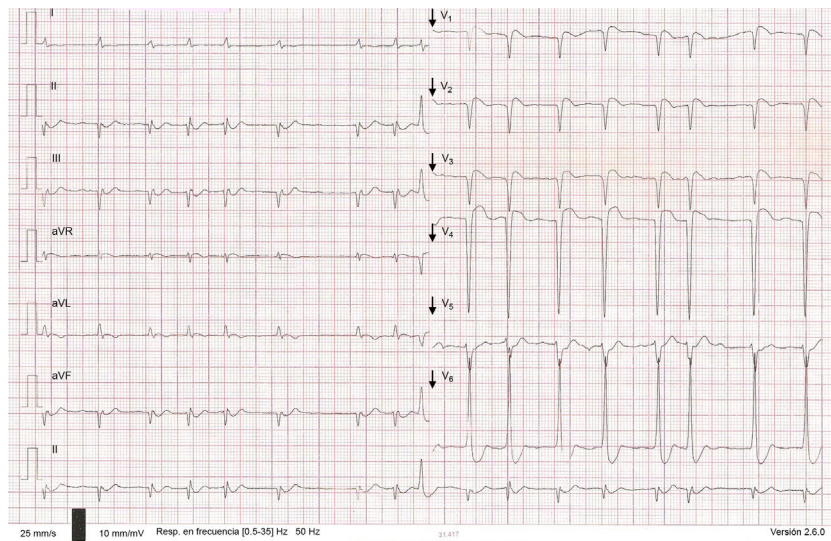
Respuesta al ECG de enero de 2016

Pablo Merás Colunga

Servicio de Cardiología, Hospital Universitario La Paz, Madrid, Spain



This was a bidirectional ventricular tachycardia in the context of digoxin toxicity, which subsequently changed to a monomorphic ventricular tachycardia. Investigations revealed normal renal function and a blood digoxin level of 2.66 ng/mL. Treatment with phenytoin and anti-digoxin antibodies was started, with resolution of the tachycardia (Figure).

**Figure.**

SEE RELATED ARTICLE:

<http://dx.doi.org/10.1016/j.rec.2015.05.021>E-mail address: merascalunga@gmail.com<http://dx.doi.org/10.1016/j.rec.2015.05.022>

1885-5857/© 2015 Sociedad Española de Cardiología. Published by Elsevier España, S.L.U. All rights reserved.