

## ECG Contest

## Response to ECG, April 2019

## Respuesta al ECG de abril de 2019

Zaira Gómez-Álvarez,\* Juan Carlos Gómez-Polo, and Miguel Ángel Cobos-Gil

Instituto Cardiovascular, Hospital Clínico San Carlos, Madrid, Spain

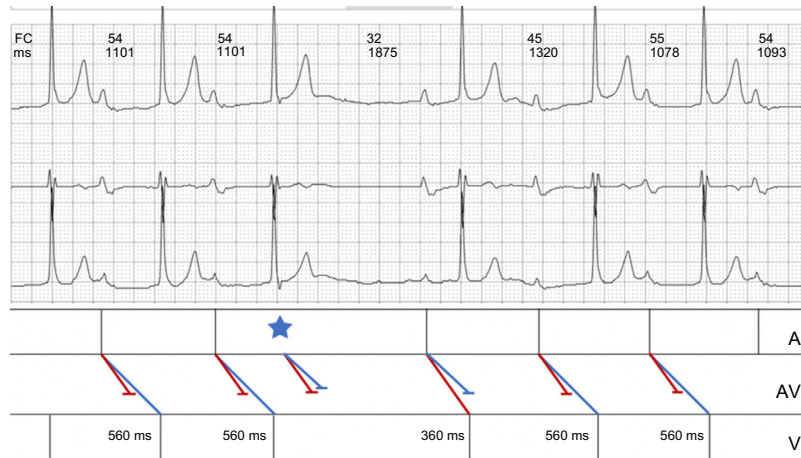


Figure 1.

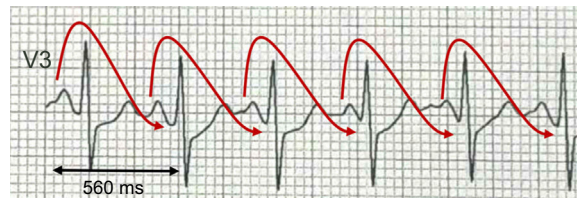


Figure 2.

The patient has a dual atrioventricular node physiology, with conduction jump from the fast to slow pathway. Therefore, the correct answer is response 3.

The sinus morphology of the P wave excludes the presence of nodal rhythm (response 2, incorrect). Given the P wave and QRS complex are almost superimposed in stage 2 of the exercise test, it is almost impossible that pre-excitation and enhanced atrioventricular node conduction are present (response 1, incorrect).

The prevalence of dual node physiology in electrophysiological studies ranges from 10% to 35%, although the electrocardiographic manifestations (eg, nodal reentry, 2 types of PR interval, dual ventricular response to atrial depolarization) are less frequent.<sup>1</sup>

Figure 1, taken from the Holter study, shows 2 families of PR interval of differing duration, 1 group of 560 ms (slow pathway) and another of 360 ms (fast pathway). The conduction jump from one pathway to another can be triggered by extrasystoles (Figure 1, asterisk) or occur with exercise-induced tachycardia, as documented in the present case: initially, conduction occurs via the fast pathway and, at higher heart rates, the slow pathway conducts and the over-the-top phenomenon is observed,<sup>2</sup> in which each P wave gives rise to the second QRS that follows (Figure 2).

## REFERENCES

1. Fisch C, Mandrolia JM, Rardon DP. Electrocardiographic manifestations of dual atrioventricular node conduction during sinus rhythm. *J Am Coll Cardiol.* 1997;29:1015-1022.
2. Marriott HJL. *Pearls and pitfalls in electrocardiography: pithy practical pointers.* 2.<sup>nd</sup> ed. Lea & Febiger: Philadelphia; 1990:78.

## SEE RELATED CONTENT:

<https://doi.org/10.1016/j.rec.2018.05.034>

\* Corresponding author:

E-mail address: zairagomez91@gmail.com (Z. Gómez-Álvarez).

<https://doi.org/10.1016/j.rec.2018.05.035>

1885-5857/© 2018 Sociedad Española de Cardiología. Published by Elsevier España, S.L.U. All rights reserved.