

(LA) by means of 3-dimensional echocardiography (3D-echo). The study subjects are selected from a noncardiology patient population and volumes and maximum and minimum diameters were tabulated, as were segmental volume changes, thus providing a database that could be of value for comparisons involving populations of cardiology patients. The authors acknowledge in the "Limitations" section that "the 3D-echo analysis of the LA was performed using a computer application designed for the LV [left ventricle]," but, in addition, it should be stressed that the anatomic molds generated by 3D-echo are by no means representative of the structure and anatomic configuration of the LA; thus, the parameters measured are probably very far from representing the real volume and function of this chamber.

The shape of the LA generated by 3D-echo is ovoid and quite regular; however, the real anatomy is very different (Figure). The LA has a maximum cross-sectional diameter (side-to-side) that goes completely undetected in 3D-echo examinations and other ultrasound techniques. The shape of the LA appears more like 2 truncal-conical volumes of differing "height," with the vertices in the vestibules of the pulmonary veins and the bases merged toward the mitral valve. The limit of these vestibules with respect to the veins is imprecise. The ovoid appearance of the chamber is in no way representative of reality.

Magnetic resonance studies show that the side-to-side diameter can increase in size, together with the diameter of the superior pulmonary veins, while other atrial dimensions do not change.<sup>2</sup> On the other hand, as would be expected, a good correlation has not been found between the LA diameters measured by echocardiography and the volume of the chamber measured by computed tomography.<sup>3</sup>

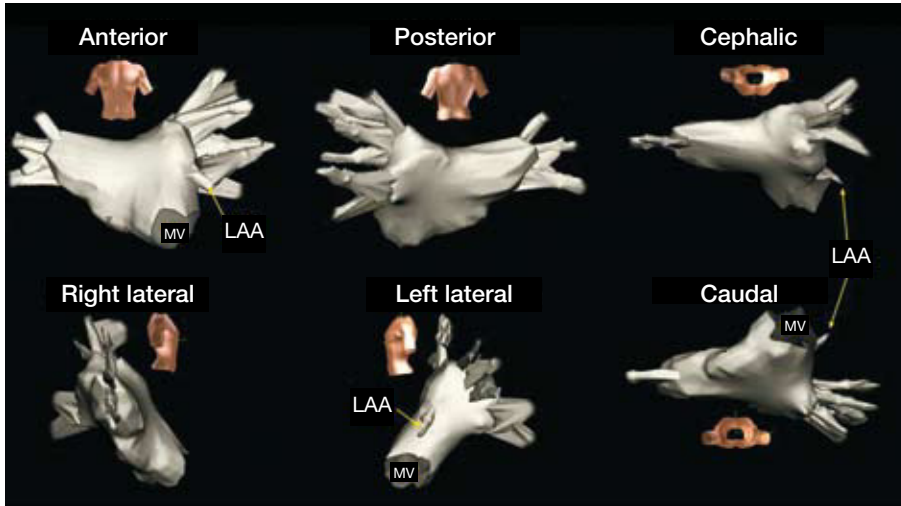
The significance of these data concerning the volumes and function of LA obtained by means of 3D-echo should be interpreted with caution and not without comparing them first with those obtained with imaging techniques capable of defining the complete anatomy of the LA throughout all the phases of its cycle. Meanwhile, magnetic resonance and computed tomography appear to be the only imaging techniques that can enable us to advance with a steady gait at the present time in the understanding of the mechanisms of atrial disease in patients defined until now as "free of heart disease" and "free of atrial dilation," especially in the definition of the anatomic and pathophysiological bases of problems with a marked clinical impact, such as atrial fibrillation.

Dr Francisco García-Cosío has received remunerations for training activities from St. Jude Medical.

## 3-D Echocardiography Does Not Reveal Left Atrial Anatomy

To the Editor,

In a recent article in *Revista Española de Cardiología*, Azar et al<sup>1</sup> report the results of a study of the volume and function of left atrium



**Figure 1.** Electroanatomic mapping (Navx©) of left atrium (LA) and the pulmonary veins in a patient with paroxysmal atrial fibrillation with no structural heart disease. Note the highly irregular shape of LA, with a large side-to-side diameter (left-to-right) that is not visualized in any of the echocardiographic projections. LAA indicates left atrial appendage; MV, mitral valve.

Francisco García Cosío, María Teresa Alberca Vela,  
and Carlos Kallmeyer Martín  
Servicio de Cardiología, Hospital Universitario de Getafe,  
Getafe, Madrid, Spain

#### REFERENCES

1. Azar F, Pérez de Isla L, Moreno M, Landfaeta A, Refoyo E, López Fernández T, et al. Evaluación de tamaño, función y rangos de normalidad de la asincronía de la aurícula izquierda en sujetos sanos mediante ecocardiografía tridimensional. *Rev Esp Cardiol.* 2009;62:816-9.
2. Tsao H-M, Yu W-C, Cheng H-C, Wu M-H, Tai C-T, Lin W-S, et al. Pulmonary vein dilation in patients with atrial fibrillation: detection by magnetic resonance imaging. *J Cardiovasc Electrophysiol.* 2001;12:809-13.
3. Hof I, Arbab-Zadeh A, Scherr D, Chilukuri K, Dalal D, Abraham T, et al. Correlation of left atrial diameter by echocardiography and left atrial volume by computed tomography. *J Cardiovasc Electrophysiol.* 2009;20:159-63.

## Response

### To the Editor,

First of all, we would like to thank Dr García Cosío and coworkers for the highly constructive critique that they have made of our article. Undoubtedly, their comments are correct with regard to the diagnostic accuracy of the technique: other imaging techniques such as magnetic resonance and computed tomography are much more suitable when it comes

to defining the anatomy of left atrium and it is true that the software employed in the study is designed, as mentioned in the article, for the evaluation of the volume of left ventricle.<sup>1</sup>

However, we would like to clarify a series of points. First, one of the objectives of this study is to define the values using this specific technique. Undoubtedly, they are not the most accurate ones,<sup>2,3</sup> but *a)* the echocardiogram is a technique that is infinitely more accessible to the patient than cardiac magnetic resonance or computed tomography; *b)* the echocardiogram is a portable technique and, thus, the evaluation can be carried out in different clinical settings, not only, like the other techniques, in a radiology unit; and *c)* in contrast to computed tomography, the echocardiogram does not emit ionizing radiation. On the other hand, based on our own experience, with the changes introduced when it comes to applying the software for left ventricle for measuring the volumes of left atrium, the follow-up of the left atrial wall carried out by the system throughout the cardiac cycle is correct.

In conclusion, we can say that the objective of our paper was not to compare the echocardiogram with other imaging techniques, which, indisputably, are more suitable for the evaluation of left atrium, but to demonstrate the normal values for left atrium when evaluated with 3D-echocardiography using software designed for left ventricle but applied to the left atrium. There can be no doubt that 3D-echocardiography provides a new, accessible possibility for the study of the atrium, with its advantages and its limitations.

Francisco Azar,<sup>a</sup> Leopoldo Pérez de Isla,<sup>a</sup> Mar Moreno,<sup>b</sup>  
and José Zamorano<sup>a</sup>

<sup>a</sup>Unidad de Imagen Cardiovascular,  
Hospital Clínico San Carlos, Madrid, Spain

<sup>b</sup>Unidad de Imagen Cardiovascular,  
Hospital La Paz, Madrid, Spain

**REFERENCES**

1. Azar F, Pérez de Isla L, Moreno M, Landaeta A, Refoyo E, López Fernández T, et al. Evaluación de tamaño, función y rangos de normalidad de la asincronía de la aurícula izquierda en sujetos sanos mediante ecocardiografía tridimensional. *Rev Esp Cardiol.* 2009;62:816-9.
2. Aune E, Baekkevar M, Roislien J, Rodevand O, Otterstad JE. Normal reference ranges for left and right atrial volume indexes and ejection fractions obtained with real-time three-dimensional echocardiography. *Eur J Echocardiogr.* 2009;10:738-44.
3. Badano LP, Pezzutto N, Marinigh R, Cinello M, Nucifora G, Pavoni D, et al. How many patients would be misclassified using M-mode and two-dimensional estimates of left atrial size instead of left atrial volume? A three-dimensional echocardiographic study. *J Cardiovasc Med (Hagerstown).* 2008;9:476-84.