

Transient Midventricular Dyskinesia: Tako-Tsubo Cardiomyopathy. The Story Continues

To the Editor:

We have read with great interest the article of Núñez Gil et al¹ recently published in this Journal. The authors report on a retrospective series of patients with transient midventricular dyskinesias (TMVD).

As they point out, the incidence of this new variant seems to be lower than that of the apical forms (TAD),¹ although some authors report that they might be underestimated and that they constitute 30% to 40% of all such cases.²

We find it interesting to compare the series published by those authors with ours involving 14 patients, reviewed retrospectively, who were diagnosed over a period between October 2004 and December 2007³; 13 patients had TAD and 1 had TMVD. The TMVD patients studied by Núñez Gil et al were younger than the TAD group in our center (59 [11] years vs 71 [8] years) and the most frequent finding at presentation was the presence of negative T waves (60%), in contrast to our group, in which ST segment elevation was the most common electrocardiographic abnormality (78%). In an exhaustive review of the literature, we have found 7 series of patients with TMVD. The majority also coincides in associating younger ages with the forms of TMVD, and there are no significant differences in terms of the remaining clinical and analytical variables. However, the authors of one of these reports conclude that TMVD, as compared to TAD, occurs in patients: of younger age (58 years vs 70 years; $P=.02$); with fewer cardiovascular risk factors (38% vs 77%; $P=.01$), especially a lower incidence of hypertension; with less frequent presence of negative T waves (69% vs 97%; $P=.01$) and a tendency to develop fewer complications during the acute phase (cardiogenic shock, arrhythmias, and left ventricular failure).⁴ These findings agree with those of Núñez Gil et al, who recorded no episodes of ventricular failure or shock.

It proves difficult to understand the localization of the changes in contractility, and it is curious that the new

variants, like TMVD and the more recent basal forms,⁵ are being documented more than 10 years after the first reports of TAD. The widespread use of imaging techniques during the acute phase probably explains this fact. We coincide with Núñez Gil et al in that TMVD could be an incomplete or attenuated form in younger patients, triggered by less stressful events that, together with a particular distribution of adrenoceptors and sympathetic terminals, would provoke a peculiar form of ventricular dysynergy. Myocardial stunning is the most widely accepted pathophysiological basis. Along this line and based on previous studies,^{6,7} we demonstrated, using thrombolysis in myocardial infarction (TIMI) frame counts (TFC), in cases of TAD and of TMVD, the existence of microvascular dysfunction in the left coronary territory as compared to a control group of patients with normal coronary arteries³: TFC in anterior descending artery, 26 (4) versus 19 (1) ($P=.0004$) and TFC in circumflex artery, 23 (4) versus 18.5 (2.6) ($P=.008$). We found no significant differences in the TFC in the right coronary territory. We do not know whether or not these findings are in some way related to the high prevalence of recurrent anterior descending artery in our series (57%, similar to that observed by Núñez Gil et al in their TMVD group), which has not been reported for other series. This raises the question as to whether the microvascular dysfunction could be a cause or a consequence of myocardial toxicity induced by catecholamines.

Future studies will surely resolve this enigma, which persists 18 years after the initial report of the syndrome. Until then, we should keep an open mind to the close relationship between brain and heart and consider TMVD to be a particular form within the spectrum of stress cardiomyopathy.

Manuel Almendro-Delia
and Rafael Hidalgo-Urbano

Unidad Coronaria, Servicio de Cardiología,
Hospital Virgen Macarena, Sevilla, Spain

REFERENCES

1. Núñez Gil II, García-Rubira JC, Luaces Méndez M, Fernández-Ortiz A, Vivas Balcones D, González Ferrer JJ, et al. Discinesia medioventricular izquierda transitoria: aspectos clínicos de una nueva variante. *Rev Esp Cardiol*. 2008;61:322-6.
2. Schneider B, Athanariadis A, Pister W, Schamberger R, Schoeller R, Toepel W, et al. Clinical spectrum of tako-tsubo cardiomyopathy in western population: first results of the tako-tsubo registry. *Eur Heart J*. 2007;28 Suppl:607.
3. Almendro Delia M, Méndez Santos I, Alba M, Hidalgo RJ, González-Valdayo M, Valenzuela LF, et al. Miocardiopatía de estrés: Una nueva entidad cardiológica. *Rev Esp Cardiol*. 2007;60 Supl 2:179.
4. Hahn JY, Gwon HC, Park SW, Choi SH, Choi JH, Choi JO, et al. The clinical features of transient left ventricular nonapical ballooning syndrome: comparison with apical ballooning syndrome. *Am J Cardiol*. 2007;154:1166-73.

5. Reuss CS, Lester SJ, Hurst RT, Askew JW, Nager P, Lusk J, et al. Isolated left ventricular basal ballooning cardiomyopathy in young women. *Am J Cardiol.* 2007;99:1451-3.
6. Bybee KA, Prasad A, Barsness GW, Lerman A, Jaffe AS, Murphy JG, et al. Clinical characteristics and thrombolysis in myocardial infarction frame counts in women with transient left ventricular apical ballooning syndrome. *Am J Cardiol.* 2004;94:343-6.
7. Kurowski V, Kaiser A, von Hof K, Killermann DP, Mayer B, Hartman F, et al. Apical and midventricular transient left ventricular dysfunction syndrome (tako-tsubo cardiomyopathy): frequency, mechanisms, and prognosis. *Chest.* 2007;132:809-16.

Response

To the Editor:

We wish to thank you very much for publishing the excellent letter from Dr Almendro-Delia and Dr Hidalgo-Urbano, reporting their experience with Tako-tsubo syndrome and its midventricular variant. The first cases of this disease were discovered in 1990¹ and, although at first it was considered to be highly infrequent, it is now thought to account for more than 1% of acute infarctions (5% in women).² Years later, there are increasing reports of cases and of variants characterized by the fact that they do not involve the left ventricular apex at the time of diagnosis. As the authors point out in their letter, this tendency could be due to the widespread use of imaging techniques (echocardiography, catheterization) during the acute phase, but also to the wider spread recognition by physicians of a previously

unknown condition, as reflected by the increase in the number of publications on the subject in recent years (Figure). In our series, studied between 2003 and 2007, 37% of the cases (23 of 62 patients) corresponded to atypical forms.³ Given that the prognosis appears to be benign, despite occasional serious complications,³ the greatest enigma lies in elucidating the pathophysiological mechanism. Both the neurohormonal imbalance associated with catecholaminergic influence and microvascular dysfunction measured by the thrombolysis in myocardial infarction (TIMI) frame counts (TFC) analyzed by Almendro-Delia and Hidalgo-Urbano, among other factors, have been pointed to by a number of authors as being implicated.^{2,3} However, the influence of an elongated, or recurrent, anterior descending artery⁴ should be clarified.

Iván J. Núñez-Gil and Juan C. García Rubira

Instituto Cardiovascular, Hospital Clínico San Carlos, Madrid, Spain

REFERENCES

1. Sato H, Tateishi H, Uchida T. Takotsubo-type cardiomyopathy due to multivessel spasm. In: Kodama K, Haze K, Hon M, editors. [Clinical aspect of myocardial injury: from ischemia to heart failure] [japonés]. Tokyo: Kagakuhyouronsya; 1990. p. 56-64.
2. Previtali M, Repetto A, Panigada S, Camporotondo R, Tavazzi L. Left ventricular apical ballooning syndrome: Prevalence, clinical characteristics and pathogenetic mechanisms in a European population. *Int J Cardiol.* 2008 May 26 [in press].

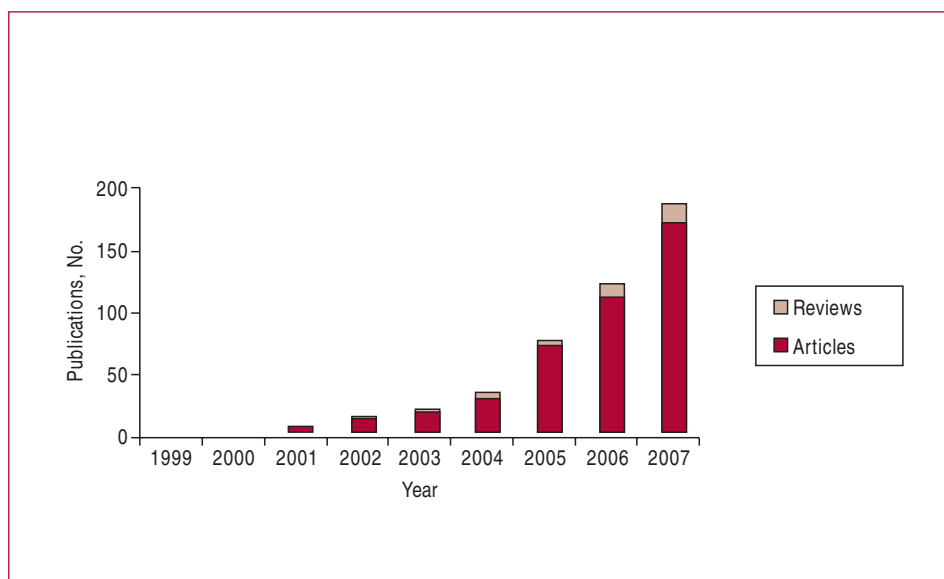


Figure. Publications included in PubMed, according to years, in which the terms "tako-tsubo" or "apical ballooning" appear.

3. Núñez-Gil IJ, Fernández-Ortiz A, Pérez-Isla L, Luaces M, García-Rubira JC, Vivas D, et al. Clinical and prognostic comparison between left ventricular transient dyskinesia and a first non-ST segment elevation acute coronary syndrome. *Coron Artery Dis.* 2008 [in press].
4. Ibáñez B, Navarro F, Farré J, Marcos-Alberca P, Orejas M, Rábago R, et al. Asociación del síndrome *tako-tsubo* con la arteria coronaria descendente anterior con extensa distribución por el segmento diafragmático. *Rev Esp Cardiol.* 2004;57:209-16.