

2. Bertomeu-González V, Anguita M, Moreno-Arribas J, Cequier A, Muñoz J, Castillo-Castillo J, et al.; FANTASIA Study Investigators. Quality of anticoagulation with vitamin K antagonists. *Clin Cardiol*. 2015;38:357–64.
3. Kim E, Ozonoff A, Hylek EM, Berlowitz DR, Ash AS, Miller DR, et al. Predicting outcomes among patients with atrial fibrillation and heart failure receiving anticoagulation with warfarin. *Thromb Haemost*. 2015;114:70–7.
4. del Campo M, Roberts G. Changes in warfarin sensitivity during decompensated heart failure and chronic obstructive pulmonary disease. *Ann Pharmacother*. 2015. <http://dx.doi.org/10.1177/1060028015590438>.

5. Bridgen M, Kay C, Lee A, Adamson PB. Audit of the frequency and clinical response to excessive oral anticoagulation in an outpatient population. *Am J Hematol*. 1998;59:22–7.
6. Ripley TL, Harrison D, Germany RE. Effect of heart failure exacerbations on anticoagulation: a prospective, observational, pilot cohort study. *Clin Ther*. 2010;32:506–14.

<http://dx.doi.org/10.1016/j.rec.2015.08.017>

Refractory Electrical Storm: A Role for Transient Sympathetic Blockade



Tormenta arrítmica refractaria: papel del bloqueo simpático transitorio

To the Editor,

Electrical storm (ES) is defined as the appearance of 3 or more episodes of ventricular tachycardia or fibrillation within 24 hours requiring antitachycardia therapy or cardioversion/defibrillation.¹ In practice, the number of episodes is usually much higher, producing an extremely serious situation. The role of the sympathetic nervous system in ES is well established,² and sympathetic blockade has been shown to effectively control these situations.³ The first studies with sympathetic blockade centered on its use to treat congenital long-QT syndrome in patients unresponsive to beta-blocker therapy, and it has recently been applied in the treatment of ES.⁴

The goal of this study was to present our accumulated experience with transient sympathetic blockade (TSB) in the treatment of a series of patients with refractory ES, defined as ES persisting after conventional therapy for the control of ES and its immediate causes.

Refractory ES was diagnosed according to the judgment of the responsible physician, without prior specification of criteria for episode duration, number, or toleration. In all patients, TSB was first attempted by left stellate ganglion block (LSGB); patients with recurrent ES or poor initial control after LSGB were scheduled for

bilateral block by thoracic epidural anesthesia. LSGB was performed by ultrasound-guided bolus injection of local anesthetic via the paratracheal route. The procedure was carried out at the patient's bedside in the coronary care unit by anesthesia unit staff. Ultrasound guidance was also used to place a soft catheter for continuous infusion of 0.2% ropivacaine. The mean infusion rate was 7 mL/h, with an initial rate of 6 mL/h and a maximum of 12 mL/h. The efficacy of TSB was evaluated by clinical observation: the efficacy indicators were clinical signs of Horner syndrome for LSGB and relief of anterior chest pain in patients given thoracic epidural anesthesia. In all patients, TSB was used as an addition to conventional antiarrhythmic therapy and in no instances replaced or required withdrawal of baseline pharmacologic treatment. In 2 patients, LSGB did not achieve sufficient electrical control, and these patients were given thoracic epidural anesthesia with 0.2% ropivacaine. Sympathetic blockade was withdrawn according to the medical team's criteria after the patient had been free of arrhythmias for 48 hours.

The effectiveness of the technique was estimated by comparing the number of episodes of sustained ventricular arrhythmia before and after TSB. The statistical significance of the reduction in the number of episodes after LSGB was assessed by the Wilcoxon test for paired data.

Between March 2012 and December 2014, our team performed TSB on 8 patients diagnosed with refractory ES. The mean patient age was 58 years, and 75% had severe left-ventricular systolic dysfunction. Baseline patient characteristics, the trigger for ES, and the initial treatment are summarized in the [Table](#).

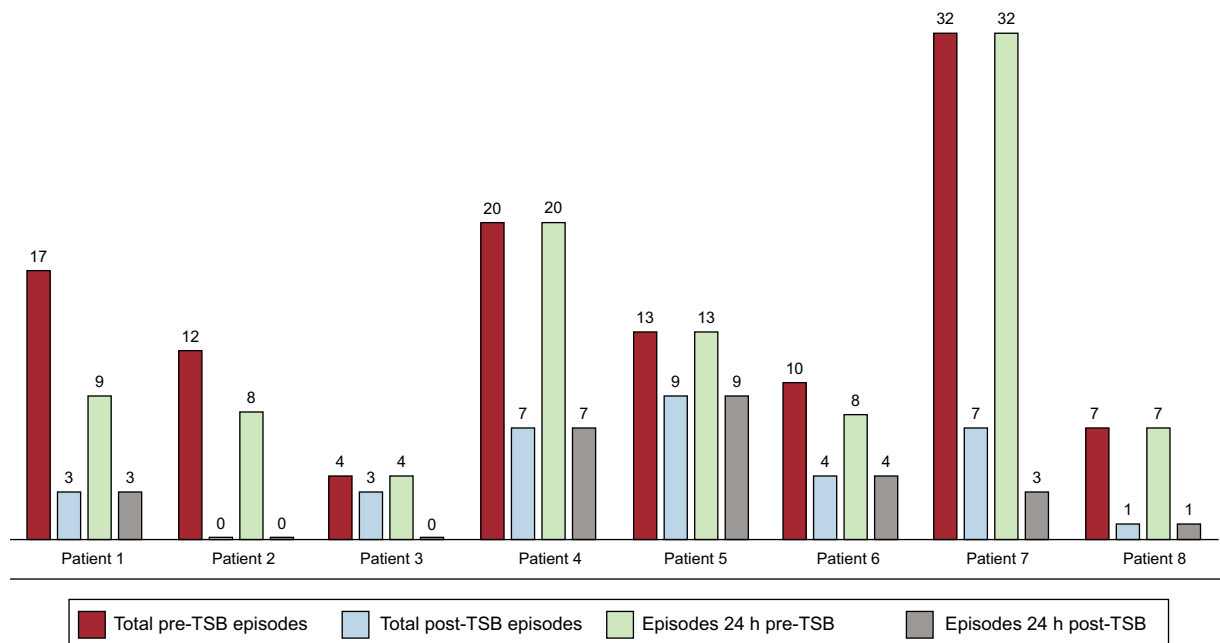


Figure. Number of electrical storm episodes, defined as the presence of sustained ventricular arrhythmias. The graph shows total episodes and episodes in the 24 hours before and after transient sympathetic blockade TSB: Transient sympathetic blockade.

Table
Baseline Patient Characteristics, Electrical Storm Trigger, Initial Treatment, and Follow-up

	Age, y	Sex	Underlying disease	Trigger	Type of arrhythmia	ICD	LVEF, %	TI	IABP	Drugs	Technique for transient SB	Duration of SB, d	Coronary angiography	Revascularization	In-hospital death	Cause of death	Recurrence of ES	Follow-up, time
1	57	Male	Ischemic heart disease	Heart failure	Polymorphic VT	No	12	Yes	Yes	BB, amiodarone, lidocaine	LSGB	5	No	No	No		No	Alive, no readmissions (33 months)
2	81	Male	Valvular heart disease	Acquired long QT syndrome	Polymorphic VT	No	60	Yes	No	Magnesium	LSGB	4	No	No	Yes	Sepsis - VAP	No	Deceased
3	58	Male	Dilated cardiomyopathy	Sepsis/heart failure	Polymorphic VT	Yes	26	No	No	BB, amiodarone	LSGB	6	No	No	Yes	Heart failure	No	Deceased
4	58	Male	Dilated cardiomyopathy	Ventilator withdrawal	Polymorphic VT	No	31	Yes	No	BB, amiodarone, procainamide	LSGB	10	Yes	No	No		Yes (7 days)	Alive, no readmissions (13 months)
5	58	Male	Dilated cardiomyopathy	Heart failure	Polymorphic VT	Yes	25	Yes	No	BB, procainamide	LSGB/TEA	9/6	No	No	No		No	Alive, heart transplant (12 months)
6	71	Male	Ischemic heart disease	Heart failure	Polymorphic VT	Yes	15	Yes	No	Amiodarone	LSGB	6	Yes	No	Yes	Ventricular arrhythmia	Yes (3 days)	Deceased
7	49	Female	No structural heart disease	Unknown	Polymorphic VT	No	61	No	No	BB, amiodarone	LSGB/TEA	2/2	Yes	No	No		No	Alive, no readmissions (2 months)
8	58	Male	Ischemic heart disease	Heart failure	Polymorphic VT	No	25	Yes	Yes	BB, amiodarone	LSGB	9	Yes	No	Yes	Arterial ischemia	Yes (11 days)	Deceased

BB: beta-blockers; IABP: intra-aortic balloon pump; ICD: implantable cardioverter-defibrillator; LSGB: left stellate ganglion block; LVEF: left-ventricular ejection fraction; SB: sympathetic blockade; TEA: thoracic epidural anesthesia; TI: tracheal intubation; VAP: ventilator-associated pneumonia; VT: ventricular tachycardia.

In 6 patients, the number of arrhythmia episodes declined during the first 24 hours after the initiation of sympathetic blockade (Figure). In all 6 patients, LSGB significantly reduced the total number of episodes and the number of episodes in the first 24 hours after the intervention ($P < .05$). Electrical storm recurred in 3 patients (37%) during the first 24 hours after the cessation of sympathetic blockade. Of these patients, 2 responded to repeat LSGB. The third patient responded to conventional therapy and thus there was no further requirement for sympathetic blockade.

Mortality was 50% (patients 2, 3, 6, and 8), but only 1 death (patient 6) was due to arrhythmia. Catheter ablation of ventricular tachycardia was performed in patient 4, and patient 5 underwent heart transplantation. The follow-up of each patient is presented in the Table. In all patients, sympathetic blockade was transitory and its use did not interfere with conventional treatments, including definitive treatments such as catheter ablation and heart transplantation. There were no complications related to the procedure.

The results of our study suggest that TSB is a useful technique for the control of refractory ES. In our study, we used standard techniques for transient sympathetic blockade without having to resort to definitive methods. This contrasts with other studies reporting the use of interventions such as surgical sympathectomy⁵ or videothoracoscopy ablation of the sympathetic chain ganglia in the pleural cavity.

The main limitations of our study are the small sample size and its observational and retrospective nature. In addition, due to patient care and organizational issues, it was not possible to retrospectively determine the exact number of patients presenting

with refractory ES during the study period (March 2012 to December 2014).

Emilio García-Morán, Frank Sliwinski-Herrera,*
Carlos Cortes-Villar, María Sandín-Fuentes, Gemma Pastor Báez,
and Alberto San Román

*Instituto de Ciencias del Corazón (ICICOR), Hospital Clínico
Universitario, Valladolid, Spain*

*Corresponding author:

E-mail address: fsliwinski@gmail.com (F. Sliwinski-Herrera).

Available online 11 December 2015

REFERENCES

1. Pedersen CT, Kay GN, Kalman J, Borggreffe M, Della-Bella P, Dickfeld T, et al. EHRA/HRS/APHRS expert consensus on ventricular arrhythmias. *Europace*. 2014;16:1257–83.
2. Vaseghi M, Shivkumar K. The role of the autonomic nervous system in sudden cardiac death. *Prog Cardiovasc Dis*. 2008;50:404–19.
3. Nademanee K, Taylor R, Bailey WE, Rieders DE, Kosar EM. Treating electrical storm: sympathetic blockade versus advanced cardiac life support-guided therapy. *Circulation*. 2000;102:742–7.
4. Mahajan A, Moore J, Cesario DA, Shivkumar K. Use of thoracic epidural anesthesia for management of electrical storm: a case report. *Heart Rhythm*. 2005;2:1359–62.
5. Bourke T, Vaseghi M, Michowitz Y, Sankhla V, Shah M, Swapna N, et al. Neuraxial modulation for refractory ventricular arrhythmias: value of thoracic epidural anesthesia and surgical left cardiac sympathetic denervation. *Circulation*. 2010;121:2255–62.

<http://dx.doi.org/10.1016/j.rec.2015.08.024>

Use of Atrial Septostomy to Treat Severe Pulmonary Arterial Hypertension in Adults



Septostomía auricular en el tratamiento de la hipertensión arterial pulmonar grave del adulto

To the Editor,

Elective atrial septostomy (AS) can provide additional clinical benefits to adults receiving targeted triple therapy (endothelin receptor antagonists, phosphodiesterase-5 inhibitors, and prostanoids) for severe pulmonary arterial hypertension (PAH). Elective AS can be used as a bridge to lung transplantation when medical treatment is ineffective or as a definitive treatment when transplantation is contraindicated. Clinical guidelines recommend AS for PAH patients in functional class III or IV with refractory right heart failure or severe exercise-induced syncopal symptoms, either as a pretransplant treatment or as a palliative measure when no other treatment options are available.¹ However, this intervention has been little used in our setting.

We present experience with elective AS in PAH patients under targeted triple therapy at a referral center. To our knowledge, this is the largest series in Spain describing results obtained with this technique in the context of current PAH treatment.

Since 2005 we have performed 11 balloon AS procedures and 1 stent fenestration of the atrial septum in a total of 10 patients (8 women, mean age 43.5 years). Patient data and procedures are summarized in the Table. All patients were in PAH functional class III or IV and all were taking epoprostenol, either in targeted triple

therapy with endothelin receptor antagonists and phosphodiesterase-5 inhibitors (7 patients), or in double therapy with phosphodiesterase-5 inhibitors (3 patients). Patients were prepared for AS by blood transfusion and treatment with inotropes and intravenous diuretics. Elective AS was not used as a rescue procedure in end-stage disease. A transeptal puncture was made with a Brockenbrough needle followed by gradual balloon dilatation, according to the protocol described by Sandoval et al.² The procedure was carried out without sedation in order to properly monitor changes in peripheral artery oxygen saturation. As stipulated in the protocol,² the transeptal opening was expanded gradually, initially with a balloon diameter of 4 mm and then sequentially with balloons dilated to 8, 12, and 16 mm. Each dilatation was followed by a 3 minute pause, at the end of which readings were taken of left ventricular end-diastolic pressure and arterial oxygen saturation. Final aperture size was determined individually for each patient, with dilatation stopped when any of the following conditions were met: elevation of left ventricular end-diastolic pressure > 18 mmHg, reduction in peripheral artery oxygen saturation to < 80% or by > 10% relative to the basal level, or dilatation of the interatrial septum to the maximum aperture (16 mm). The procedure was guided by intracardiac echocardiography in 2 patients and by fluoroscopy alone in the others. For the patient who underwent stent fenestration of the interatrial septum, we used the diabolo-shaped stent configuration described by Stümper et al,³ without sedation and with monitoring by fluoroscopy and intracardiac echocardiography. After making the transeptal puncture with a Brockenbrough needle, an Inoue guide wire was advanced into the left atrium and the interatrial opening