

# Reconstruction of the Right Ventricular Outflow Tract Using a Medtronic Freestyle Aortic Root Bioprosthesis

Víctor X. Mosquera,<sup>a</sup> Francisco Portela,<sup>a</sup> Claudio Zavanella,<sup>a</sup> Alberto Juffé,<sup>a</sup> Inés Raposo,<sup>b</sup> and Beatriz Bouzas<sup>c</sup>

<sup>a</sup>Servicio de Cirugía Cardíaca, Servicio de Cardiología, Hospital Juan Canalejo, A Coruña, Spain

<sup>b</sup>Unidad de Cardiología Infantil, Servicio de Cardiología, Hospital Juan Canalejo, A Coruña, Spain

<sup>c</sup>Laboratorio de Imagen, Servicio de Cardiología, Hospital Juan Canalejo, A Coruña, Spain

Uncorrected, long-term pulmonary regurgitation leads to right ventricular dilatation and dysfunction in a significant percentage of patients. We used magnetic resonance imaging (MRI) before and after surgery to assess the effect of pulmonary valve replacement with the Medtronic Freestyle bioprosthesis on right ventricular function and volume in nine patients with pulmonary regurgitation or stenosis. Mean follow-up time was 26 (10) months. We observed a decrease in mean end-diastolic volume from 143.6 (85.1) mL/m<sup>2</sup> to 74.1 (12.6) mL/m<sup>2</sup> ( $P=0.018$ ) and, in end-systolic volume from 88.0 (50.3) mL/m<sup>2</sup> to 35.8 (19.3) mL/m<sup>2</sup> ( $P=0.016$ ).

In pulmonary valve disease, extensive follow-up by MRI is essential for timely evaluation of the degree of right ventricular dilation or dysfunction and for selecting a suitable time for valve replacement. The Medtronic Freestyle bioprosthesis is a good surgical choice for pulmonary valve replacement as its use is associated with low morbidity and mortality and the successful normalization of ventricular volumes.

**Key words:** *Magnetic resonance imaging. Pulmonary regurgitation. Pulmonary valve. Right ventricle. Stentless prosthesis.*

## Reconstrucción del tracto de salida del ventrículo derecho con raíz aórtica protésica Medtronic Freestyle

La insuficiencia pulmonar no corregida conduce a la dilatación y disfunción del ventrículo derecho a largo plazo en un porcentaje importante de pacientes. Hemos analizado mediante resonancia magnética cardíaca (RMC) preoperatoria y postoperatoria el efecto del recambio valvular pulmonar con prótesis Medtronic Freestyle en la función y los volúmenes del ventrículo derecho en 9 pacientes con insuficiencia y/o estenosis pulmonar con seguimiento de 26 ± 10 meses. Observamos una disminución del volumen telediastólico medio desde 143,6 ± 85,1 hasta 74,1 ± 12,6 ml/m<sup>2</sup> ( $p = 0,018$ ), y del volumen telesistólico medio desde 88 ± 50,3 hasta 35,8 ± 19,3 ml/m<sup>2</sup> ( $p = 0,016$ ).

La valvulopatía pulmonar requiere un seguimiento exhaustivo mediante RMC para determinar precozmente el grado de dilatación y disfunción del ventrículo derecho, y así decidir el momento idóneo para la sustitución valvular. La bioprótesis Freestyle en posición pulmonar es una opción quirúrgica adecuada, con una baja morbimortalidad y excelentes resultados en cuanto a restauración volumétrica ventricular.

**Palabras clave:** *Resonancia magnética nuclear. Insuficiencia pulmonar. Válvula pulmonar. Ventrículo derecho. Prótesis no soportadas.*

## INTRODUCTION

Adult pulmonary insufficiency was classically considered to be well-tolerated and, thus, there was a certain tendency to delay the moment of intervention. However, we now know that, over the long term, uncorrected pulmonary insufficiency can lead to right

ventricular dilatation and dysfunction, which are associated with low exercise tolerance and an increase in the incidence of arrhythmias and sudden death.

The objective of this study is to analyze the effect of pulmonary valve replacement with the Medtronic Freestyle<sup>®</sup> stentless bioprosthesis (Medtronic, Minneapolis, MN, US) on right ventricular function and volume in patients treated surgically for dysfunction of the right ventricular outflow tract.

## METHODS

A descriptive, observational study was carried out involving the 9 patients, assessed consecutively, who underwent surgery for pulmonary valve insufficiency,

Correspondence: Dr. V.X. Mosquera Rodríguez.  
Complejo Hospitalario Juan Canalejo.  
Xubias de Arriba, 86. 15006 A Coruña. España.  
E-mail: vxmr@canalejo.org

Received July 28, 2006.

Accepted for publication February 22, 2007.

**Demographic, Clinical, Surgical, and Cardiac Magnetic Resonance Data of the Patients\***

Patient no.	Age at Surgery	NYHA Functional Class	Previous Surgery	Pre-PVR RVDV, mL/m <sup>2</sup>	Post-PVR RVDV, mL/m <sup>2</sup>	Pre-PVR RVSU, mL/m <sup>2</sup>	Post-PVR RVSU, mL/m <sup>2</sup>	Pre-PVR RVEF, %	Post-PVR RVEF, %
1	19	2	Tetralogy of Fallot	109.5	88	76.4	22.7	30	74
2	37	3	Ross procedure	93.7	51.5	72.4	24.3	22	53
3	23	3	Tetralogy of Fallot	108	73.1	76.3	44.6	29	39
4	16	1	Tetralogy of Fallot	101.2	79.4	41.7	22.7	58	71
5	13	2	Tetralogy of Fallot	308.9	65.5	197.2	24.1	36	63
6	29	3	Correction VSD+AVR	84.4	75.1	48.8	37.1	42	35
7	34	3	Pulmonary commissurotomy	247.7	86.4	122.8	75.1	50	13
8	16	3	Tetralogy of Fallot	150.7	79.4	63.9	22.8	31	71
9	51	3	Tetralogy of Fallot	95.7	Not available	Not available	Not available	28	Not available

\*AVR indicates aortic valve replacement; NYHA, New York Heart Association; PVR, pulmonary valve replacement; RVDV, right ventricular diastolic volume; RVEF, right ventricular ejection fraction; RVSU, right ventricular systolic volume; VSD, ventricular septal defect.

and/or stenosis in the Cardiac Surgery Service of Hospital Juan Canalejo, A Coruña, in northwestern Spain, between 2003 and 2005.

The demographic data were obtained from the Apollo 32 database and the review of the clinical records.

The preoperative and postoperative color Doppler and two-dimensional ultrasound images and M-mode echocardiography of all the patients were reviewed.

Right ventricular volumes and function were calculated using cardiac magnetic resonance (CMR). The maximums for right ventricular function were based on the measurements reported previously by other authors<sup>1</sup>: right ventricular end-diastolic volume of  $\geq 207$  mL/m<sup>2</sup> and end-systolic volume of  $\geq 47$  mL/m<sup>2</sup>, respectively, while a function  $\leq 35\%$  was considered to be abnormal.

Pulmonary valve replacement involved implantation of a stentless Freestyle<sup>®</sup> using a double running suture, following creation of a scallop in the noncoronary sinus to adapt it to the right ventricular outflow tract. The incision was prolonged toward the pulmonary bifurcation, minimizing the opening of the primitive pulmonary annulus and, when necessary, a bovine pericardial patch was employed to complete the proximal anastomosis between the valve and right ventricle. The implantation was performed without aortic clamping and hypothermia of 32°C in 5 patients. We only employed aortic clamping when some other procedure that required it was to be performed in the same surgical session (4 patients) (Table).

The data were analyzed using the Statistical Package for the Social Sciences (SPSS) for Windows XP (version 13.0). The descriptive statistics for the continuous variables were expressed as the mean plus or minus the standard deviation or as the mean and the range, as appropriate. The discrete, quantitative, dependent variables were analyzed using the Wilcoxon sign rank test, while Spearman's rank correlation coefficient ( $\rho$ ) was employed for the independent quantitative variables and the McNemar test for the qualitative variables, and a *P* value less than .05 was considered significant.

**RESULTS**

The demographic and clinical data and the results of magnetic resonance studies are shown in the Table.

The main indications for pulmonary valve replacement were the presence of moderate-to-severe or severe pulmonary insufficiency in 8 patients, whereas 3 presented at least moderate-to-severe pulmonary stenosis. Five patients had an end-diastolic volume greater than 107 mL/m<sup>2</sup> and 8, an end-systolic volume greater than 47 mL/m<sup>2</sup> prior to surgery. The preoperative right ventricular ejection fraction was less than 35% in 5 patients.

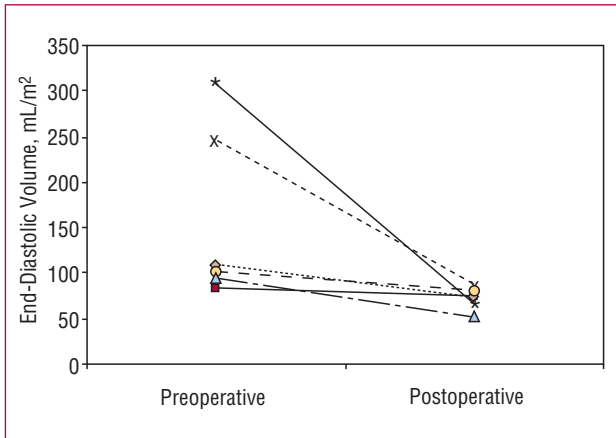
Freestyle bioprostheses measuring between 23 mm and 29 mm were implanted. The mean cardiopulmonary bypass time was 82 (22) minutes.

The mean follow-up period was 26 (10) months. During this period only 1 patient (no. 9) died. This patient presented tetralogy of Fallot with right ventricular dysfunction (preoperative right ventricular ejection fraction of 28%), and had been offered the possibility of heart transplantation as a first option, but refused it.

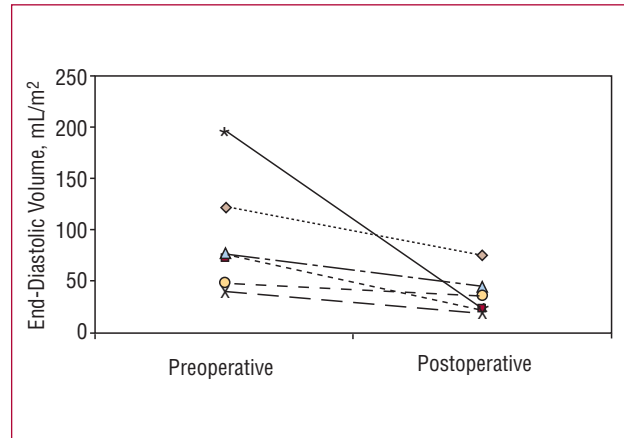
The New York Heart Association (NYHA) functional class of the patients improved from a preoperative mean of 2.5 (0.7) to 1.3 (0.7) (*P*=.015). Follow-up transthoracic echocardiography was performed 10.9 (3) months after the intervention and revealed a reduction in pulmonary valve disease in all the patients treated surgically for pulmonary insufficiency and/or stenosis (*P*=.011 and *P*=.016, respectively). The gradient across the prosthesis in postoperative ultrasound was 29.2 (8.6) mm Hg (interval 19-48 mm Hg).

The preoperative CMR had been carried out 9.5 (7) months prior to the intervention and was repeated 16.9 (9.4) months after surgery. The changes in right ventricular volumes are shown in Figures 1 and 2.

The mean end-diastolic volumes were reduced from 144.4 (79.6) mL/m<sup>2</sup> to 74.8 (11.8) mL/m<sup>2</sup>, resulting in a mean decrease of 40% (23) (*P*=.012). The end-systolic volumes were reduced from a mean of 85.3 (47.7) mL/m<sup>2</sup>



**Figure 1.** Reduction of right ventricular end-diastolic volume following pulmonary valve replacement.



**Figure 2.** Reduction of right ventricular end-systolic volume following pulmonary valve replacement.

to 34.2 (18.4) mL/m<sup>2</sup>, that is, a mean decrease of 54% (20) ( $P=.012$ ). The overall mean right ventricular ejection fraction increased following valve replacement, although the increase was not statistically significant (from 36% [11] to 54% [20];  $P=.09$ ).

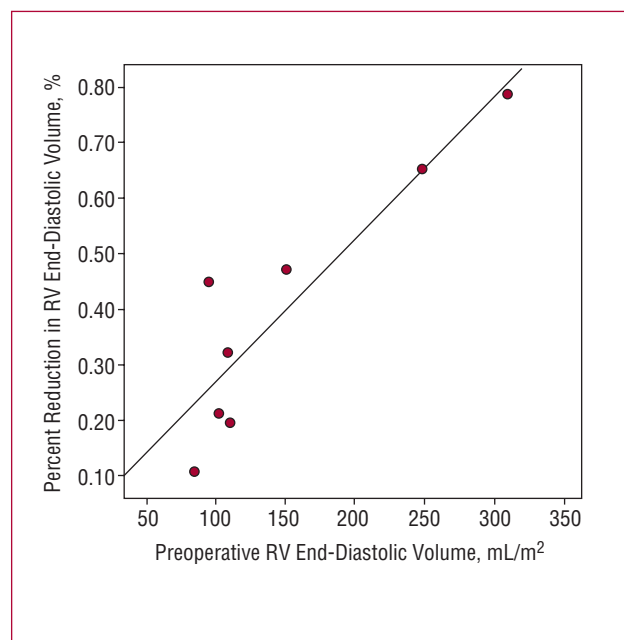
After valve replacement, the normalization of the end-diastolic volume was observed in all 9 patients (<107 mL/m<sup>2</sup>, whereas the end-systolic volume was restored to normal in 8 (<47 mL/m<sup>2</sup>).

Correlation analysis of the preoperative right ventricular end-diastolic volume and the percent reduction in this volume showed that the latter was greater in patients with greater preoperative volumes ( $r=0.78$ ;  $P=.021$ ) (Figure 3).

## DISCUSSION

Vliegen et al<sup>2</sup> demonstrated that pulmonary valve replacement produced substantial improvements in hemodynamic and ventricular function in patients with pulmonary insufficiency and right ventricular dilation. However, the improvement in ventricular function following pulmonary valve replacement clearly depends on the timing of the intervention. When valve replacement is carried out at the proper time, echocardiography reveals a reduction of the diameters of the right chambers and an improvement in right ventricular contractility.<sup>3-5</sup> Other studies report different results with regard to the changes in right ventricle after pulmonary valve replacement when measured by means of echocardiography.<sup>4-6</sup> The irregular shape of right ventricle and unpredictable way in which it dilates complicate its quantitative analysis, either using echocardiography or catheterization.

Cardiac magnetic resonance offers clear advantages over echocardiography and ventriculography since it does not rely on geometric approximations for the calculation of right ventricular mass, volumes, and function, while it enables a better assessment of possible akinetic zones and/or aneurysmal disease in the right ventricular outflow tract.



**Figure 3.** Spearman's rank correlation coefficient ( $\rho$ ) shows a positive correlation between the presurgical end-diastolic volume and the percent reduction observed ( $r=0.78$ ;  $P=.021$ ). RV indicates right ventricular.

Pulmonary valve replacement carries little risk in patients with pulmonary insufficiency, with a perioperative mortality of 1% to 4%<sup>7</sup> and a mean 10-year survival of 95%,<sup>8</sup> when it is not associated with some other surgical procedure. In all of our patients, the postoperative morbidity and mortality were 0, and remained so after a maximum follow-up of 26 (10) months.

At the present time, there is a wide and varied range of prosthetic options for pulmonary valve replacement. However, to date, there is no "ideal" replacement for the native pulmonary valve.

We have observed that the greater the right ventricular end-diastolic volume at the time of surgery, the greater

the percent reduction in this parameter following valve replacement. This finding differs with respect to the results reported by other authors, who affirm that beyond a certain right ventricular volume, the decrease is minimal.<sup>1</sup> We consider that these positive results may be due to the use of a stentless prosthesis since, in the first place, these prostheses are associated with excellent hemodynamic results when implanted in the pulmonary position, better than those observed with stented prostheses, and, according to some studies, better than those achieved with homografts. However, it should be pointed out that, to date, no prosthesis has been found to be the ideal replacement for the pulmonary valve and that both the stentless porcine prostheses and homografts are excellent options for the treatment diseases of the right ventricular outflow tract.

The importance of pulmonary valve disease should not be underestimated. It requires exhaustive follow-up with CMR to determine the degree of right ventricular dilation and dysfunction as early as possible. This enables us to decide on the best moment for pulmonary valve replacement and, later, to evaluate the outcome of the surgery.

The results obtained in our study with respect to the restoration of right ventricular geometry and the clinical improvement of the patients are very encouraging, and are similar to those reported recently by other authors.<sup>1,2</sup>

## REFERENCES

1. Therrien J, Provost Y, Merchant N, Williams W, Colman J, Webb G. Optimal timing for pulmonary valve replacement in adults after tetralogy of Fallot repair. *Am J Cardiol.* 2005;95:779-82.
2. Vliegen HW, van Straten A, de Roos A, Roest AA, Schoof PH, Zwinderman AH, et al. Magnetic resonance imaging to assess the hemodynamic effects of pulmonary valve replacement in adults late after repair of tetralogy of fallot. *Circulation.* 2002;106:1703-7.
3. Warner KG, Anderson JE, Fulton DR, Payne DD, Geggel RL, Marx GR. Restoration of the pulmonary valve reduces right ventricular volume overload after previous repair of tetralogy of Fallot. *Circulation.* 1993;88:III189-97.
4. Bove EL, Kavey RE, Byrum CJ, Sondheimer HM, Blackman MS, Thomas FD. Improved right ventricular function following late pulmonary valve replacement for residual pulmonary insufficiency or stenosis. *J Thorac Cardiovasc Surg.* 1985;90:50-5.
5. D'Udekem Y, Rubay J, Shango-Lody P, Ovaert C, Vliers A, Caliteaux M, et al. Late homograft valve insertion after transannular patch repair of tetralogy of Fallot. *J Heart Valve Dis.* 1998;7:450-4.
6. Discigil B, Dearani JA, Puga FJ, Schaff HV, Hagler DJ, Warnes CA, et al. Late pulmonary valve replacement after repair of tetralogy of Fallot. *J Thorac Cardiovasc Surg.* 2001;121:344-51.
7. Oechslin EN, Harrison DA, Harris L, Downar E, Webb GD, Siu SS, et al. Reoperation in adults with repair of tetralogy of fallot: indications and outcomes. *J Thorac Cardiovasc Surg.* 1999;118:245-51.
8. Yemets IM, Williams WG, Webb GD, Harrison DA, McLaughlin PR, Trusler GA, et al. Pulmonary valve replacement late after repair of tetralogy of Fallot. *Ann Thorac Surg.* 1997;64:526-30.
9. Hartz RS, Deleon SY, Lane J, Dorotan J, Joyce J, Urbina E, et al. Medtronic freestyle valves in right ventricular outflow tract reconstruction. *Ann Thorac Surg.* 2003;76:1896-900.