

Radiofrequency Ablation in the Treatment of Focal Atrial Fibrillation Using Circumferential Mapping and Segmentary Disconnection of Pulmonary Veins

Rose MFL. Silva,^a Lluís Mont,^b Antonio Berruezo,^b Xavier Fosch,^b Luis Wayar,^b Nelson Alvarenga,^b Enrique Chueca,^b and Josep Brugada^b

^aBecaria del CNPq, Brasil. ^bSección de Arritmias. Instituto de Enfermedades Cardiovasculares, Hospital Clínico Universitario, Universidad de Barcelona, Institut d'Investigacions Biomèdiques August Pi i Sunyer (IDIBAPS), Barcelona, Spain.

Introduction. The treatment of paroxysmal atrial fibrillation in patients without structural heart disease using radiofrequency ablation of pulmonary veins is a recently developed procedure with a good clinical success rate, although there have only been a few published series. We analyzed our results with this technique.

Method. The procedure was performed in 33 highly symptomatic patients with focal atrial fibrillation that had probably originated in the pulmonary veins. The electrophysiological study was carried out with a decapolar catheter inserted by transeptal catheterization. Ablation was performed using a 4-mm catheter and directed to the segments of the ostium of pulmonary veins where venous potentials with greatest precocity were recorded. Subsequent radiofrequency applications were performed until pulmonary vein disconnection was achieved.

Results. Venous electrical activity was recorded in 59 of 115 pulmonary veins that were mapped (58 were disconnected). During a median follow-up of 180 days, 8 patients recurred and only 2 of these continue with repeat episodes. The success rate at short term was 74.2% and at mid-term was 93.5%. Nineteen patients continue to receive antiarrhythmic treatment ineffective before the procedure. Two patients showed complications related to catheter manipulation during transeptal catheterization, probably due to air embolism, that was resolved spontaneously without consequences. No patient showed pulmonary stenosis.

Conclusions. Treatment of focal atrial fibrillation using circumferential mapping and radiofrequency application in segments of the ostium of pulmonary veins is a highly effective procedure in selected patients and has potentially severe although infrequent complications.

Key words: Atrial fibrillation. Pulmonary veins. Ablation.

Full English text available at: www.revespcardiol.org

Correspondence: Dr. J. Brugada.
Unidad de Arritmias. Instituto de Enfermedades Cardiovasculares.
Hospital Clínic. Villarroel, 170. 08036 Barcelona. España.
E-mail: jbbrugada@clinic.ub.es

Received 8 August 2002.
Accepted for publication 11 November 2002.

Ablación por radiofrecuencia para el tratamiento de la fibrilación auricular focal a través de cartografía circunferencial y aislamiento segmentario de las venas pulmonares

Introducción. El tratamiento de la fibrilación auricular paroxística en pacientes sin cardiopatía estructural a través de la ablación con radiofrecuencia de las venas pulmonares es un procedimiento reciente y con una tasa de éxito clínico importante, aunque las series publicadas son escasas. Analizamos nuestros resultados.

Método. Fueron sometidos al procedimiento 33 pacientes muy sintomáticos y en fibrilación auricular de probable origen focal en venas pulmonares. Se realizó cartografía con un catéter decapolar por punción transeptal. Se utilizó un catéter de 4 mm para ablación de los segmentos del ostium de las venas donde se registraba el potencial eléctrico venoso con mayor precocidad, y se aplicó radiofrecuencia hasta obtener la desconexión de la vena pulmonar.

Resultados. Se registró actividad eléctrica en 59 de 115 venas pulmonares cartografiadas (58 fueron desconectadas). Durante un seguimiento medio de 180 días, 8 pacientes presentaron recurrencia de la arritmia y de éstos sólo dos siguen con episodios repetitivos. La tasa de éxito a corto plazo fue del 74,2% y a medio plazo, del 93,5%. Diecinueve pacientes reciben tratamiento antiarrítmico antes inefectivo. Dos pacientes presentaron complicaciones en relación con el manejo de catéteres durante la punción transeptal, probablemente por embolia gaseosa, que se resolvieron espontáneamente sin secuelas. Ningún paciente presentó signos o síntomas de estenosis pulmonar.

Conclusiones. El tratamiento de la fibrilación auricular focal a través de cartografía circunferencial y aplicación de radiofrecuencia en segmentos del ostium de las venas pulmonares es un procedimiento de gran eficacia en pacientes seleccionados y con complicaciones potencialmente graves pero infrecuentes.

Palabras clave: Fibrilación auricular. Venas pulmonares. Ablación.

SEE EDITORIAL ON PAGES 331-2

ABBREVIATIONS

AF: atrial fibrillation.
PV: pulmonary veins.
RF: radiofrequency.

INTRODUCTION

Recent studies have shown that the majority of episodes of paroxysmal atrial fibrillation (AF) in patients without structural heart disease are triggered by extrasystoles with venous pulmonary foci.¹⁻⁹ Circumferential mapping of the ostium of the pulmonary veins (PV) with multi-electrode catheters allows identification of segments of the perimeter of the venoatrial junction occupied by muscle bands that extend from the left atrium to the PV. The application of radiofrequency (RF) to said areas allows disconnection of the distal muscle fibers of the PV with a significant rate of clinical success.^{7,8}

In prior studies using this technique ablation has been performed of PV in which ectopy had been documented, and a significant percentage of these patients required repeat procedures.⁸ Oral et al recently described the results of an empirical approach directing the ablation to at least three PVs.¹⁰

In our study, using the technique described, mapping of the 4 PVs was carried out when possible as was disconnection of all those that presented with PV potentials in the ostium.

In our country, ablation of PVs has been described in an isolated manner for clinical cases.^{11,12} In this article we present our series of 33 patients in focal-origin AF who underwent PV ablation, and describe the technique employed, the immediate results, and results during clinical follow-up.

PATIENTS AND METHODS

The procedure was carried out on 31 patients with paroxysmal AF and 2 patients with persistent AF. Twenty-five of the patients were male, with a mean age of 51 years \pm 10 years. Twenty-six patients did not present with structural heart disease; 5 had hypertensive heart disease, 1 had ischemic heart disease, and the last patient had valve ischemia. One patient without structural heart disease wore a defibrillator, implanted 26 months prior to the procedure in the setting of recovered sudden death syndrome, and another had an electrocardiogram suggestive of Brugada syndrome discovered by treatment with flecainide. The mean development time for AF was 71 months (interval, 6 months to 372 months). In 72% of patients the episodes of arrhythmia occurred daily. In the 6 months prior

to the procedure 45% of patients had been seen in the emergency room. All patients were undergoing treatment with anti-arrhythmia agents and were taking an average of 2.6 \pm 0.9 drugs; the majority of them (28 patients) were taking amiodarone. The mean diameter of the left atrium was 37 mm \pm 4 mm and the ejection fraction was 0.61 \pm 0.08. An intracardiac thrombus was not detected in any patient. Nine patients were taking acenocoumarol as an oral anticoagulant. Four of the total number of patients had previously undergone ablation of the cavotricuspid isthmus in the setting of typical atrial flutter, with efficacy criteria.

Electrophysiological study and ablation

Use of all anti-arrhythmia drugs was suspended a minimum of 5 half-lives prior to the procedure, as were anticoagulants. Following signature of an informed consent form, the patients underwent the study under sedation with 5 mg of oral diazepam, with conventional 12-lead cardiac monitoring and intracardiac bipolar electrogram utilizing the Electrophysiologic Measurement System, Version 4.0 (Maastricht, The Netherlands) polygraph.

Two electrocatheters were advanced via fluoroscopic control toward the left atrium through the patent foramen ovale or via transeptal puncture, using a Brockenbrough needle. A decapolar catheter with a circular flexible tip (Lasso, Biosense Webster) was introduced via guide catheter for mapping of the pulmonary veins and a 7F 4 mm steerable curve catheter was introduced for ablation. A 6F catheter was also inserted to record and stimulate the right atrium or coronary sinus, or both, via the right femoral vein. After transeptal puncture 2500 to 5000 units of sodium heparin bolus was introduced, according to the patient's weight, and 1000 units were added every 60 minutes as per our protocol.

Six patients were in AF rhythm and 5 underwent transthoracic electrical cardioversion prior to the mapping procedure. Two patients underwent mapping and the application of RF while in AF rhythm.

A Lasso catheter was positioned in the ostium of each pulmonary vein, beginning with the left superior PV, the location of which was determined according to the level of the cardiac silhouette in posteroanterior projection, recording of the intracavity electrograms, and catheter stability. The inferior PV required greater manipulation. The angiographic diameter of the ostium of the pulmonary veins varied from 13 mm to 16 mm in size, from the right inferior to the left superior, respectively;⁷ taking this data into account, we decided to begin the procedure with the 15 mm diameter catheter. A catheter of a larger diameter was not needed in any of the cases.

In the atrial margin of the ostium, the PV potentials were present around the entire circumference, but not

in the interior of the PV, where potentials were only present in some segments of the perimeter.⁸ The Lasso catheter was positioned as closely as possible in the interior of the mapped vein. In the segments (identified by the Lasso catheter bipoles) of the ostium where the greatest PV potential precocity was shown to exist, RF energy was applied with a temperature limit of 50°C and power limit of 50 W. The applications were repeated with the purpose of obtaining disassociation of electrical activity from the PV and the left atrium or the elimination of the venous potential.^{13,14} In the cases where disconnection was not achieved or there was no change in the activation sequence, we proceeded to increase the temperature to a maximum of 60°C. The procedure was performed during sinus rhythm, or during stimulation from the distal coronary sinus to better record the PV potentials separately from the atrial recording.⁷ All pulmonary veins with electrical activity were treated, whether or not there were extrasystoles originating from their interiors. Provocation maneuvers were not used.

In the majority of patients, following the ablation procedure we proceeded to carry out angiography of the PV subjected to ablation to look for possible acute stenosis.

Clinical followup

Following the procedure, either acenocoumarol was administered to those patients who met the criteria described in the literature¹⁵ or acetylsalicylic acid (150 to 300 mg) was administered for one month and flecainide was administered for 3 months following the procedure. For those patients who needed therapeutic anti-arrhythmia agents, treatment was maintained in order to control their symptoms. The patients were seen in the outpatient clinic and underwent Holter monitoring and transthoracic echocardiogram (basically to evaluate the increase in flow velocity in the PV) 15 days following the procedure. A recurrence of episodes was considered to be present if reported by the patients or identified on Holter monitoring as sustained episodes.

Statistical analysis

The results are expressed as mean±standard deviation. Continuous variables were compared via the Student t and the non-continuous variables via the χ^2 test or the exact Fisher test. A value of $P<.05$ was considered significant.

RESULTS

During the introduction of the catheters into the left atrium 2 patients experienced thoracic pain with a recording of a subepicardial lesion on the inferior face,

and we did not proceed to PV mapping. Emergency coronary angiography did not reveal lesions in the coronary arteries and the pain resolved spontaneously and without sequelae. Both events were interpreted as being air emboli. Thus, all the results were from the 31 remaining patients; 1 of them did not undergo transeptal puncture due to the presence of a permeable foramen ovale. A total of 32 procedures were performed, as 2 procedures were required in 1 patient. In 3 patients ablation of the cavotricuspid isthmus was performed during the mapping procedure due to concomitant known AF and typical atrial flutter.

One hundred and fifteen PVs were mapped; electrical activity was found in 59 of these and disconnection was achieved in 58; 30 were left superior PVs, 19 were right superior PVs, 7 were left inferior PVs, and 3 were right inferior PVs. Disconnection was not achieved in 1 left superior PV. A new procedure was performed on this patient and the persistence of activity in the left superior PV was shown to exist. In 8 patients (26%) disconnection of some of the inferior pulmonary veins was achieved. We were unable to place the Lasso catheter in the interior of 3 right inferior PVs and 2 left inferior PVs, and in 2 patients we found a common ostium for the left PVs (Figure 1). During mapping, the recording was composed of double low-frequency potentials from the left atrium, and double high-frequency potentials from the PV. During the extrasystoles the sequence of these components changed, confirming activation originating in the pulmonary vein (Figure 2).

For the 2 patients in whom mapping was performed during AF rhythm, after placing the decapolar catheter in the part nearest the PV, high frequency potentials were recorded that originated from the PV, with RF being applied effectively. Then, after conversion to sinus rhythm (in 1 case after electrical cardioversion and in the other probably due to the effect of the disconnection) we proceeded to map the rest of the PVs.

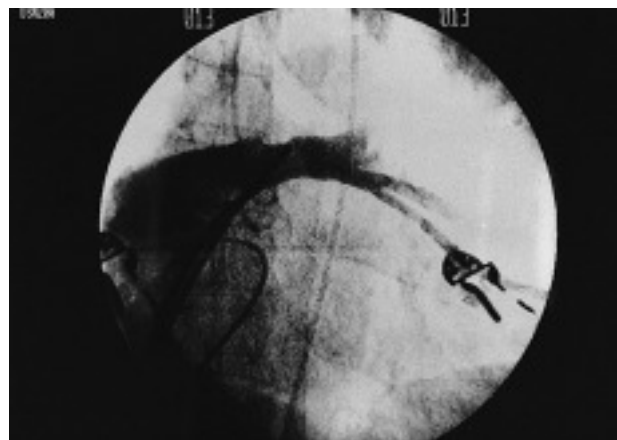


Fig. 1. Angiography of the left pulmonary veins with a common ostium.

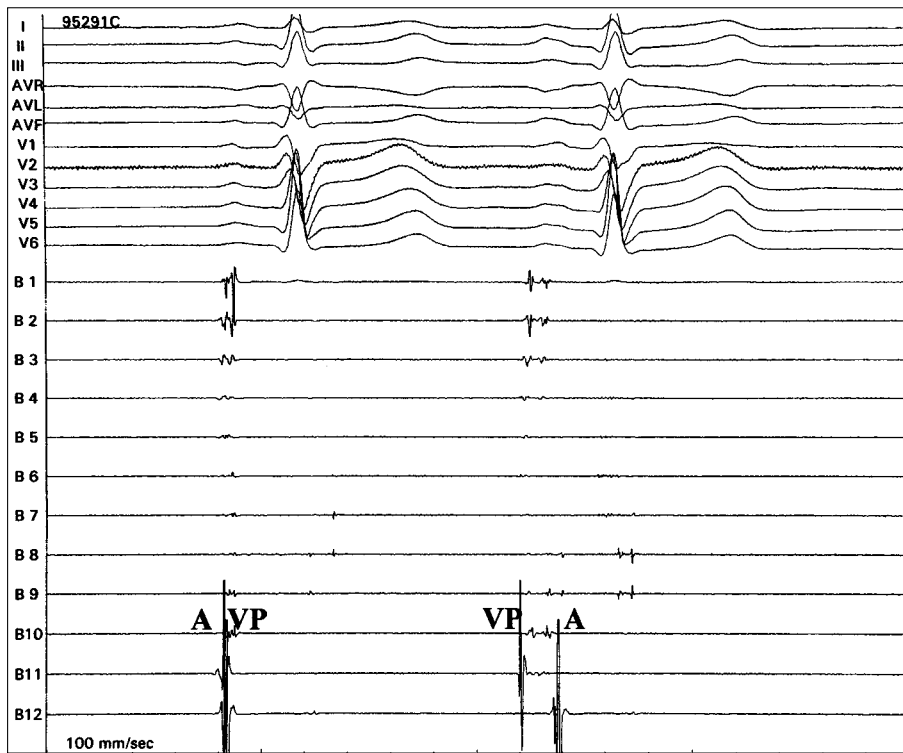


Fig. 2. Mapping via a circular curve catheter of the left superior pulmonary vein during extrasystole, with change of the double potential component sequence: the pulmonary vein potential preceding that of the left atrium and fractionation among the 2 components.

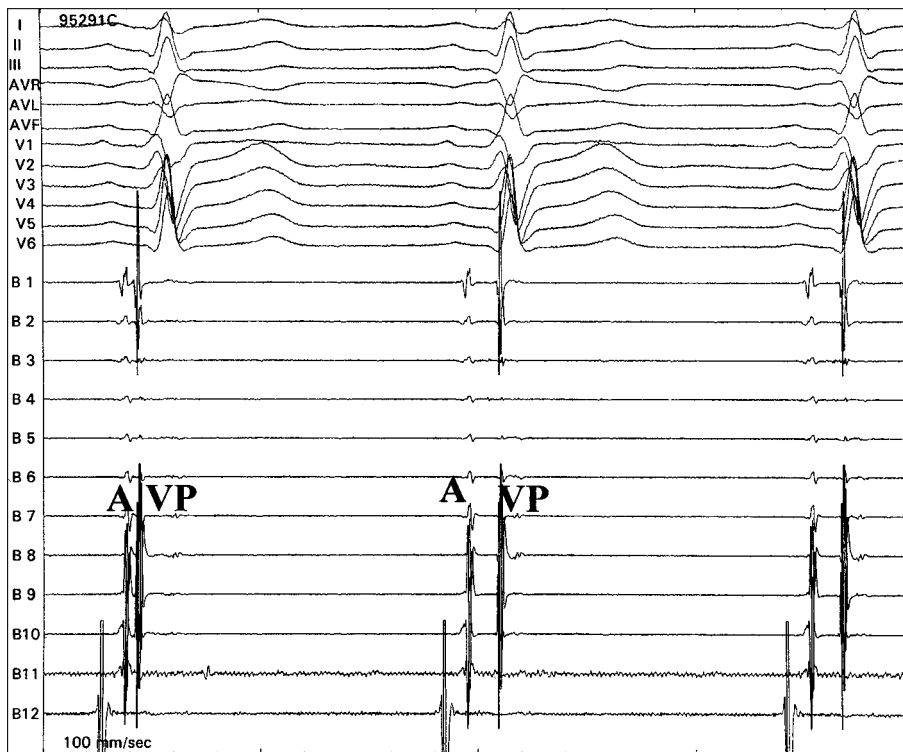


Fig. 3. Tracing from electrograms obtained via circumferential mapping of the left superior pulmonary vein during application of radiofrequency, which resulted in the separation of the pulmonary vein potential from the electrogram of the left atrium due to delay of anterograde conduction.

It was determined which segments of the PVs required RF application, and they were classified anatomically and fluoroscopically into superior, inferior, anterior, and posterior segments, with the aim of verifying the prevalence of electrical activity in each of the seg-

ments of each PV. In the left superior PV applications were made to the inferior segment in 49% of cases; to the posterior segment in 20.6% of cases; to the superior segment in 16.7% of cases; and to the anterior segment in 16.7% of cases. In the right superior PV ap-

plications were made to the inferior segment in 46.2% of cases, to the posterior segment in 21.5% of cases, to the anterior segment in 18.5% of cases, and to the superior segment in 13.8% of cases. RF was only applied to 7 left inferior PVs and 3 right inferior PVs, so it is difficult to come to any conclusions regarding the distribution of segments subjected to ablation in these cases.

We applied 18.8±9.9 RF pulses (interval, 5 to 48) per patient for 628 seconds±326 seconds (interval, 117 to 1,483 seconds) with the aim of obtaining disassociation or elimination of the PV potential (Figures 3 and 4). The mean temperature was 54.9±5.2 C°, with an average power of 46±7 W and a mean impedance of 131.7±12.7 . Total fluoroscopy time, including transeptal puncture, was 50.3±19.6 minutes and the mean time for the mapping and disconnection of the pulmonary vein potentials was 108.1±35.0 minutes.

In addition to the complication already mentioned related to transeptal puncture, 1 patient had a femoral arteriovenous fistula that required surgical correction. During the application of RF 1 patient developed transitory asystole and required ventricular stimulation. Angiography of the PV showed pulmonary stenosis in 30% of the diameter of 1 left superior PV. No patient developed a clinical picture of pulmonary stenosis during the follow-up period.

Analysis of the variables of sex, age, development time of the arrhythmia, diameter of the left atrium, duration of RF application, number of applications, and total study time with regard to the number of PV to which RF was applied showed that the number of applications was greater in patients with 2 or more PVs with electrical activity, in spite of the fact that study times and duration of RF application were the same (Table 1). The number of veins treated had no influence on recurrence rates.

During mean clinical followup of 180 days±178 days, 8 patients had a recurrence of arrhythmia between 1 and 540 days (average of 8 days) following the procedure. Of these, only 2 continued to have repetitive paroxysmal episodes and required 2 anti-arrhythmia drugs without achieving total control. The remaining 6 patients had a single episode of arrhythmia during the followup period. One patient presented with typical counterclockwise atrial flutter and underwent ablation of the cavotricuspid isthmus with efficacy criteria. Another patient developed presyncope and sinus pauses of up to 5.6 seconds documented by Holter monitoring, and a DDD-R mode pacemaker was implanted in the patient. Of the 2 patients who presented with persistent arrhythmia, 1 had a recurrence of the arrhythmia (a single episode on the day after the ablation procedure) and the other did not; the two showed clinical improvement. Nineteen patients were receiving anti-arrhythmia treatment with drugs that were

TABLE 1. Analysis of the variables and the number of pulmonary veins with electrical activity

Variables	Males	Age	AFT	LA	RFT	RF	ST
1 VP	7	53.0	66.0	39.8	514.5	13.0*	106.1
2 VP	17	51.3	73.2	36.5	679.0	21.4*	109.0

The values of the variables are expressed as mean. AFT indicates AF time in months; LA, diameter of the left atrium (mm); RFT, radiofrequency time in seconds; RF, number of radiofrequency applications; ST, study time in minutes. * P<.05.

formerly ineffective, either due to a recurrence of the arrhythmia or according to their physicians. Thus, the initial success rate was 74.2% (no arrhythmia episodes), although 93.5% of patients were found to be free of crisis during the followup period.

DISCUSSION

Circumferential mapping of the PVs allowed identification of electrical activity in 59 of the 115 veins mapped, with activity being present in 2 PVs in 48.4% of patients. These data are similar to those described in the literature, where the presence of more than 1 arrhythmogenic vein was found in 52% of the 110 patients studied by Jais¹⁶ and in 46% of the 42 patients who underwent simultaneous catheterization of the veins in a study by Hsieh.¹⁷

Anatomical studies have shown that striated muscle fibers are more abundant in the superior PVs¹⁸⁻²⁰ and that these have a length that varies from 2 cm to 4 cm and converge in the venoatrial junction.³ Nevertheless, in patients with atrial fibrillation this proximal segment is often wider.²¹ In addition to these findings, a recent study²² showed that the electrical connections are predominantly located in the inferior segments of the superior PVs and in the superior segments of the inferior PVs. In our series the sites for RF application with the earliest electrical activity were located in the inferior segment of the right superior PVs 46.2% of the time and in the left superior PVs 49% of the time.

In order to achieve greater efficacy and safety in these procedures, techniques have been developed for the disconnection of PVs via circumferential, longitudinal, and electroanatomic mapping.^{14,23,24} In our study we used the circumferential method, as we believe it permits better analysis of the activation sequence of the entire length of the ostium of the veins and also allows three-dimensional orientation. With this technique it was possible to disconnect all but 1 of the PVs that had electrical activity, permitting selection of the entrance sites of the muscle fibers and limiting the number of RF applications needed. This strategy also may have contributed to the fact that none of our patients presented with pulmonary stenosis, as was reported in other series that used the same technique.^{8,10} The brad-

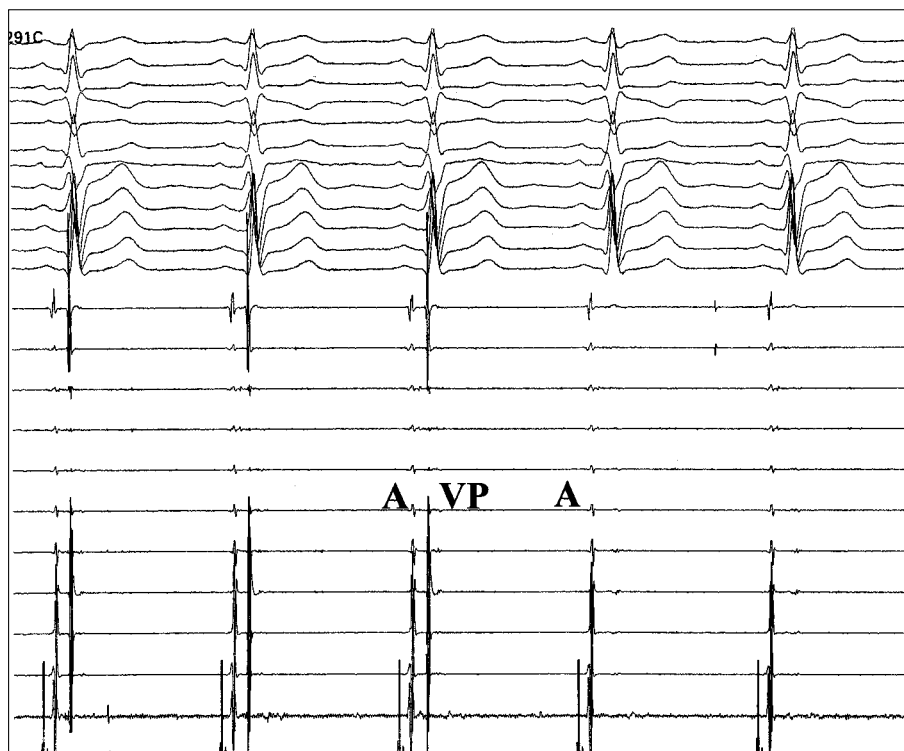


Fig. 4. During another application of radiofrequency, elimination of pulmonary vein potentials can be seen recorded by the mapping catheter in various bipolar electrograms.

arrhythmia presented by 1 of our patients was related to the application of RF in the PVs, as previously described by another group.²⁵ The 2 cases of air embolism related to the change of catheters during transeptal puncture occurred in the first patients and probably had much to do with the learning curve for this technique. This same complication also occurred in 5 of the 90 patients who underwent this same procedure in the study performed by Haïssaguerre.⁸ The concomitant findings of AF and atrial flutter suggest that in some patients this can trigger or perpetuate fibrillation.²⁶ In our series 4 patients had previously undergone ablation of the cavotricuspid isthmus, 3 during the procedure itself and another following ablation of the PVs.

As only 2 patients presented with persistent arrhythmia, our results are basically from patients with paroxysmal AF and, if we look at previous experience,^{10,24} we can say that it is likely the percentage of relapses would have been higher if a greater number of patients with persistent AF had been included in the study.

Our series achieved the success rate achieved by other groups (approximately 70%).⁷⁻¹⁰ During a mean followup period of 180 days±178 days, 74.2% of our patients were free of recurrences. Nevertheless, in our series only 1 patient underwent a repeat procedure, while in previous studies more than 40% of patients underwent repeat ablation procedures, and it was proven that in 38% of these patients there were ectopy foci initiating AF in PVs that were not treated.⁸ This suggests that the efficacy of the procedure is more re-

lated to total elimination of the potentials of the various PVs than to the acute suppression of extrasystolic foci. Similar results to those we describe have recently been reported by Oral et al¹⁰ with a similar approach.

It is possible that the temperature and power limits we used (50 to 60°C and 50 W) also had a positive influence on the low rate of relapses, if we compare then to the 50°C and 25 to 30 W limits used in the series by Haïssaguerre, in which 62% of the ectopic foci found during the second procedure (performed due to recurrence of arrhythmia) originated in the veins already subjected to ablation that had recovered their conduction.

In spite of our series being limited in scope, an interesting aspect is that during followup none of our patients developed complications due to embolism. The application of RF limited to the segments of the ostium of the PVs, the absence of acute stenosis, the suppression of episodes of arrhythmia, the age of the patients, the absence of risk factors, and the absence of structural heart disease or significant dilatation of the atrium mean that most likely no more than antiaggregant treatment for a limited amount of time following the procedure will be necessary for these patients, as our results underscore.

In spite of the significant number of patients undergoing anti-arrhythmia treatment following the procedure, our study included patients who were highly symptomatic and resistant to treatment with an average of 2.6 drugs. Following the procedure more than

90% of our patients showed great clinical improvement, confirming the success of this hybrid therapy.

CONCLUSIONS

Radiofrequency ablation for the treatment of paroxysmal atrial fibrillation by circumferential mapping with dissociation or elimination of PV potentials is a procedure that has acceptable levels of efficacy in certain patients and involves a low risk of complications, although the technique is still in the development phase.

REFERENCES

1. Haissaguerre M, Jais P, Shah DC, Lavergne T, Takahashi A, Barold S, et al. Predominant origin of atrial paroxysmal triggers in the pulmonary veins: a distinct electrophysiologic entity. *PACE* 1997;20:1065.
2. Jais P, Haissaguerre M, Shah DC, Chouairi S, Gencel L, Hocini M, et al. A focal source of atrial fibrillation treated by discrete radiofrequency ablation. *Circulation* 1997;95:572-6.
3. Haissaguerre M, Jais P, Shah DC, Takahashi A, Hocini M, Quiniou G, et al. Spontaneous initiation of atrial fibrillation by ectopic beats originating in the pulmonary veins. *N Engl J Med* 1998;339:659-66.
4. Haissaguerre M, Jais P, Shah DC, Takahashi A, Hocini M, Garrigue S, et al. Plurifocal sources of atrial fibrillation initiation from the pulmonary veins. *PACE* 1999;22:707.
5. Haissaguerre M, Jais P, Shah DC, Takahashi A, Lavergne T, Hocini M, et al. End point of successful ablation of atrial fibrillation initiated from the pulmonary veins. *PACE* 1999;22:711.
6. Shah DC, Haissaguerre M, Jais P. Catheter ablation of pulmonary vein foci for atrial fibrillation. *Thorasc Cardiovasc Surg* 1999; (Suppl):352-6.
7. Haissaguerre M, Jais P, Shah DC, Garrigue S, Takahashi A, Lavergne T, et al. Electrophysiological end point for catheter ablation of atrial fibrillation initiated from multiple pulmonary venous foci. *Circulation* 2000;101:1409-17.
8. Haissaguerre M, Sahah DC, Jais P, Hocini M, Yamane T, Deisenhofer I, et al. Electrophysiological breakthroughs from the left atrium to the pulmonary veins. *Circulation* 2000;102:2463-5.
9. Haissaguerre M, Shah DC, Jais P, Hocini M, Yamane T, Deisenhofer II, et al. Mapping-guided ablation of pulmonary veins to cure atrial fibrillation. *Am J Cardiol* 2000;86:9K-19K.
10. Oral H, Knight BP, Tada H, Özyaydin M, Chugh A, Hassan S, et al. Pulmonary vein isolation for paroxysmal and persistent atrial fibrillation. *Circulation* 2002;105:1077-81.
11. Peinado RP, Llorens JLM, Guindal JAG, Daza JAS. Fibrilación auricular focal: ablación con catéter mediante radiofrecuencia. *Rev Esp Cardiol* 1998;51:494-7.
12. Velarde JL, Martellotto R, Scanavacca M, Arévalo A, Colque R, Jiménez M. Ablación de las venas pulmonares en la fibrilación auricular. Experiencia inicial. *Rev Esp Cardiol* 2002;55:541-5.
13. Chen SA, Hsieh MH, Tai CT, Tsai CF, Prakash VS, Yu WC, et al. Initiation of atrial fibrillation by ectopic beats originating from the pulmonary veins: electrophysiological characteristics, pharmacological responses, and effects of radiofrequency ablation. *Circulation* 1999;100:1879-86.
14. Haissaguerre M, Jais P, Shah DC, Arentz T, Kalusche D, Takahashi A. Catheter ablation of chronic atrial fibrillation targeting the reinitiating triggers. *J Cardiovasc Electrophysiol* 2000;11:2-10.
15. Fuster V, Rydén LE, Asinger RW, Cannom DS, Crijns HJ, Frye RL, et al. ACC/AHA/ESC guidelines for the management of patients with atrial fibrillation: executive summary: a report of the American College of Cardiology/American Heart Association Task Force on Practice Guidelines and the European Society of Cardiology Committee for Practice Guidelines and Policy Conferences. *J Am Coll Cardiol* 2001;38:1231-65.
16. Jais P, Shah DC, Haissaguerre M, Hocini M, Tiang Peng J, Clementy J, et al. Efficacy and safety of pulmonary vein ablation for paroxysmal atrial fibrillation. *Circulation* 1999;100:779.
17. Hsieh MH, Chen SA, Tai CT, Tsai CF, Prakash VS, Yu WC, et al. Double multielectrode mapping catheters facilitate radiofrequency catheter ablation of focal atrial fibrillation originating from pulmonary veins. *J Cardiovasc Electrophysiol* 1999;10:136-44.
18. Nathan H, Eliakim M. The junction between the left atrium and the pulmonary veins. *Circulation* 1966;34:412-22.
19. Ho SY, Sanchez-Quintana D, Cabrera JA, Anderson RH. Anatomy of the left atrium: implications for radiofrequency ablation of atrial fibrillation. *J Cardiovasc Electrophysiol* 1999;10:1525-33.
20. Saito T, Waki K, Becker AE. Left atrial myocardial extension onto pulmonary veins in humans: Anatomic observations relevant for atrial arrhythmias. *J Cardiovasc Electrophysiol* 2000;11: 888-94.
21. Lin WS, Prakash VS, Tai CT, Hsieh MH, Tsai CF, Yu WC. Pulmonary vein morphology in patients with paroxysmal atrial fibrillation initiated by ectopic beats origination from the pulmonary veins. Implications for catheter ablation. *Circulation* 2000;101: 1274-81.
22. Yamane T, Shah D, Jais P, Hocini M, Deisenhofer I, Choi KJ. Electrogram polarity reversal as an additional indicator of breakthroughs from the left atrium to the pulmonary veins. *J Am Coll Cardiol* 2002;39:1337-44.
23. Natale A, Pisano E, Shewchik J, Bash D, Fanelli R, Potenza D, et al. First human experience with pulmonary vein isolation using a through-the-balloon circumferential ultrasound ablation system for recurrent atrial fibrillation. *Circulation* 2000;102:1879-82.
24. Pappone C, Oreto G, Rosanio S, Vicedomini G, Tocchi M, Gugliotta F. Atrial electroanatomic remodeling after circumferential radiofrequency pulmonary vein ablation. Efficacy of an anatomic approach in a large cohort of patients with atrial fibrillation. *Circulation* 2001;104:2539-44.
25. Tsai CF, Chen AS, Tai CT, Chiou CW, Prakash VS, Yu WC. Bezold-Jarich-like reflex during radiofrequency ablation of the pulmonary veins tissues in patients with paroxysmal focal atrial fibrillation. *J Cardiovasc Electrophysiol* 1999;10:27-35.
26. Josephson ME. Catheter and surgical ablation in the therapy of arrhythmias. En: Josephson ME. *Clinical cardiac electrophysiology: Techniques and interpretations*. 3rd ed. Philadelphia: Lippincott Williams & Wilkins, 2002; p. 710-836.