

- van der Zwaag PA, van Rijnsing IA, Asimaki A, Jongbloed JD, van Veldhuisen DJ, Wiesfeld AC, et al. Phospholamban R14del mutation in patients diagnosed with dilated cardiomyopathy or arrhythmogenic right ventricular cardiomyopathy: evidence supporting the concept of arrhythmogenic cardiomyopathy. *Eur J Heart Fail.* 2012;14:1199–207.
- van der Zwaag PA, van Rijnsing IA, de Ruiter R, Nannenberg EA, Groeneweg JA, Post JG, et al. Recurrent and founder mutations in the Netherlands-Phospholamban p.Arg14del mutation causes arrhythmogenic cardiomyopathy. *Neth Heart J.* 2013;21:286–93.
- Jiménez-Jáimez J, López Moreno E, Barrio López MT, González-Molina M, Álvarez M, Tercedor L. Herencia autosómica recesiva como causa de miocardiopatía arritmogénica biventricular. *Rev Esp Cardiol.* 2014;67:772–4.
- van Rijnsing IA, van der Zwaag PA, Groeneweg JA, Nannenberg EA, Jongbloed JD, Zwinderman AH, et al. Outcome in Phospholamban r14del carriers: results of a large Multicentre cohort study. *Circ Cardiovasc Genet.* 2014;7:455–65.

<http://dx.doi.org/10.1016/j.rec.2014.11.012>

## Radial Artery Pseudoaneurysm Following Cardiac Catheterization: Clinical Features and Nonsurgical Treatment Results



### Seudoaneurisma de la arteria radial tras cateterización cardiaca: características clínicas y resultados del tratamiento no quirúrgico

#### To the Editor,

The use of radial access for catheterization and cardiac intervention is becoming increasingly popular, mainly because of its lack of complications.<sup>1</sup> Radial artery pseudoaneurysm (RAP)<sup>2</sup> is an extremely rare complication, so many of its clinical features are unknown and treatment is not systematic. In the few reported cases of RAP, surgical repair was the most commonly used treatment,<sup>3</sup> although recently there have been reports of successful nonsurgical treatment in single patients.<sup>4,5</sup> During the period 2004–2013, we prospectively collected all cases of RAP occurring in our center. In this article, we describe their clinical characteristics and outcomes following initial nonsurgical treatment.

During this period, 16 808 catheterizations were performed (96.5% transradial), and 5 radial artery RAP were detected (incidence, 3 of 10 000 catheterizations). The Table shows the

characteristics of the RAP and the treatment applied. All cases presented as a pulsatile erythematous mass at the puncture site (Figure A). One patient (case 5) presented with pulsatile bleeding through an ulceration/erosion of the RAP. In another patient (case 4) we observed crusted erosion of the RAP without spontaneous bleeding (Figure A). All RAP were confirmed by vascular ultrasound (Figure B). The most common factors associated with the occurrence RAP were the use of coumarin anticoagulation during the procedure (4 patients) and the occurrence of hematoma in the forearm during/after compression (4 patients). Nonsurgical treatment was effective in all patients (mechanical compression was successful in 3 and failed in 2; in these patients, thrombin injection was performed, occluding the RAP in both). Direct mechanical compression of the RAP resulted in iatrogenic rupture of the outer wall (Figure C) in 2 patients (cases 2 and 5). In one patient (case 2), thrombin injection produced acute occlusion of the radial artery, which was asymptomatic.

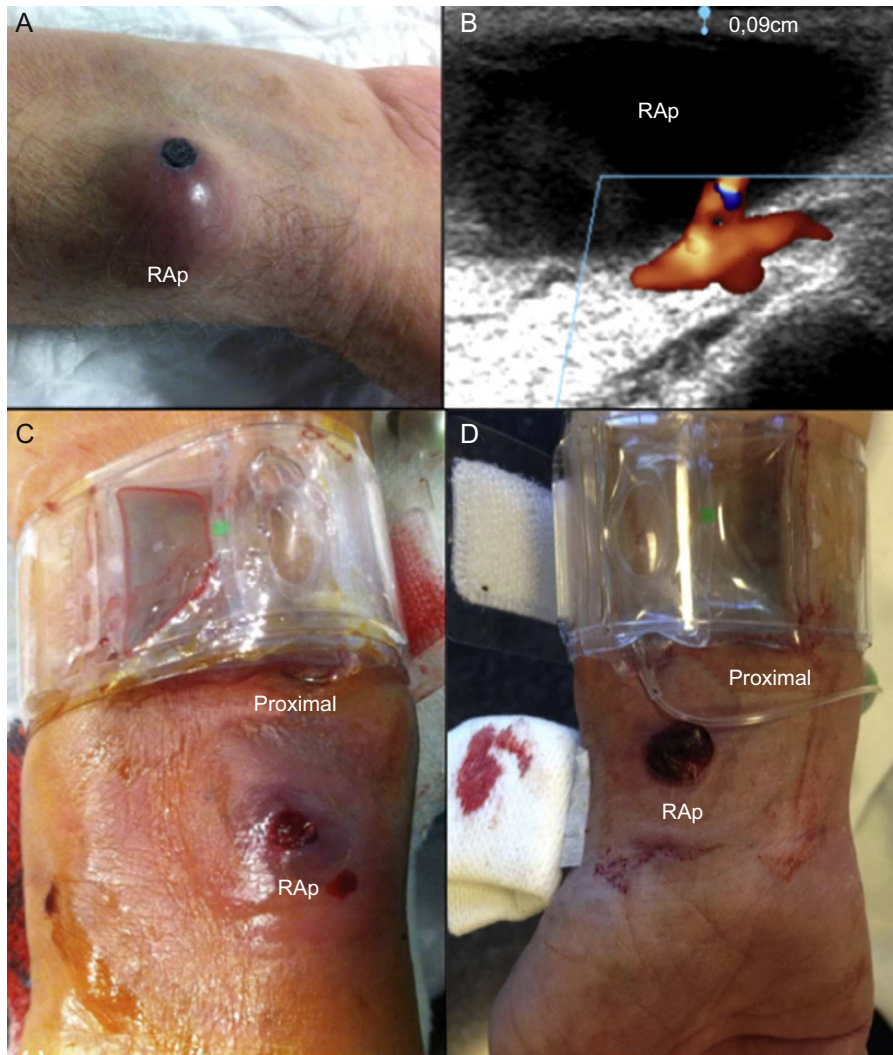
With this series of radial artery RAP, the most extensive published to date, we highlight 3 as yet undescribed features that we consider important for preventing and treating future cases:

- The presence of a hematoma in the forearm during/after compression (probably due to inadequate compression), along with the presence of predisposing factors (anticoagulation), is a

**Table**  
Clinical Characteristics of the Series

	Case 1	Case 2	Case 3	Case 4	Case 5
Age, y	55	76	79	88	81
Sex	Male	Male	Male	Male	Female
Body surface, m <sup>2</sup>	1.9	1.8	1.9	1.8	1.7
Anticoagulation with coumarin	Yes	Yes	Yes	No	Yes
Anti-GPIIb/IIIa	No	No	No	No	No
Sheath size, Fr	6	6	5	6	6
Diagnosis time, d	15	5	4	17	10
Clinical features apart from pulsatile swelling	No	No	No	Encrusted lesion at the apex	Ulceration with spontaneous bleeding
Interruption of OAC during procedure	No	No	No	Not applicable	No
Prolonged direct mechanical compression (> 12 h)	With pneumatic device	With pneumatic device	With pneumatic device but only 5 h	With pneumatic device	With direction compression with the echo probe
Initial success	No	No	Yes	No	No
Complications	No	Rupture of RAP	No	No	Rupture of RAP
Final treatment	Compression with elastic bandages 48 h	Thrombin injection	Not recorded	Thrombin injection	Compression proximal to the RAP
Interruption of OAC during follow up	Yes	No	Not applicable	Not applicable	Yes
Ultimately successful	Yes	Yes	Yes	Yes	Yes
Complications	None	Asymptomatic radial occlusion	None	None	None

OAC, oral anticoagulants; Anti-GPIIb/IIIa, glycoprotein IIb/IIIa inhibitors; RAP, radial artery pseudoaneurysm.



**Figure.** A: Erythematous mass. Note the encrusted erosion of the radial artery pseudoaneurysm (RAp) at its apex. B: Thin outer wall of RAp (0.9-mm thick). C and D: Radial pneumatic compression proximal to the RAp. Distally, both RAp are visible, including their ruptured outer wall. Note: **Figure D** corresponds to the RAp of a patient in the intensive care unit (not in our series) who has recently been successfully treated with proximal compression, as described in the recommendations.

risk factor for radial artery RAp. Patients with this easily recognizable complication, especially those undergoing anticoagulant therapy, should undergo clinical monitoring to confirm or rule out RAp.

2. RAp are very fragile. The layer of tissue separating them from the exterior is extremely thin (average thickness in our series, 1 [0.9-1.2] mm) (**Figure B**) and can rupture, resulting in external bleeding. This rupture may be spontaneous or iatrogenic (on applying direct mechanical pressure to the RAp). Unlike its homonym, the communication of a femoral RAp with the exterior is rare, probably because of the thick layer of tissue separating it from the outside.
3. Nonsurgical treatment is an alternative to surgical treatment. In our series, 100% of cases were resolved conservatively.

Despite the small number of cases in this series, we propose some recommendations based on our experience, in order to prevent and treat future radial artery RAp:

1. Prevention is key. For anticoagulated patients, we recommend firm and more prolonged compression of the puncture point, as well as a thorough exploration of the puncture site and forearm after compression. If a hematoma appears, the patient should be informed of the signs of radial artery RAp that should be reported, to allow an early diagnosis.
2. If the patient does develop radial artery RAp, we recommend conservative treatment initially (without anticoagulating the patient, if possible) using compression with a pneumatic device applied against the radial artery proximally to the RAp (**Figures C and D**) and not directly against the RAp (as is done currently, imitating the treatment of femoral RAp). In this way, potential iatrogenic rupture of the RAp is avoided. This proximal compression must be occlusive. Because of the possibility that blood may enter the RAp through the palmar arch via the ulnar artery, the absence of flow in the RAp must be verified by vascular ultrasound, or if not possible, by palpation (absence of pulsatility). We then recommend using a finger to apply direct but mild compression

against the RAP in order to expel the blood from the cavity into the radial artery and collapse it (using this simple digital compression, it can be observed that the swelling disappears completely). Once the RAP has collapsed (it is now flat), we recommend applying a semicompressive bandage directly over it. After proximal occlusive compression of the RAP for 3 to 4 hours, we then recommend a semioclusive compression (of the RAP and proximally) for an additional 24 hours. Due to the risk of external breakage, we recommend hospitalization for the following 24 hours.

3. If the above is ineffective, we recommend treatment with ultrasound-guided injection of thrombin (1 mL, 500 IU).
4. Surgery should be reserved for cases in which this more conservative management strategy has not been effective.

Isabel Zegrí, Arturo García-Touchard,\* Sofía Cuenca, Juan Francisco Oteo, José Antonio Fernández-Díaz, and Javier Goicolea

Servicio de Cardiología, Hospital Universitario Puerta de Hierro, Majadahonda, Madrid, Spain

\* Corresponding author:

E-mail address: [agtouchard@gmail.com](mailto:agtouchard@gmail.com) (A. García-Touchard).

Available online 13 February 2015

## REFERENCES

1. Rodríguez-Olivares R, García-Touchard A, Fernández-Díaz JA, Oteo JF, Zorita B, Goicolea J. Abordaje transulnar con arteria radial homolateral ocluida: descripción de la vascularización del antebrazo y seguimiento a largo plazo. *Rev Esp Cardiol*. 2014;67:854-5.
2. Sanmartín M, Cuevas D, Goicolea J, Ruiz-Salmerón R, Gómez M, Argibay V. Complicaciones vasculares asociadas al acceso transradial para el cateterismo cardiaco. *Rev Esp Cardiol*. 2004;57:581-4.
3. Collins N, Wainstein R, Ward M, Bhagwande R, Dzavik V. Pseudoaneurysm after transradial cardiac catheterization: case series and review of the literature. *Catheter Cardiovasc Interv*. 2012;80:283-7.
4. Nazer B, Boyle A. Treatment of recurrent radial artery pseudoaneurysms by prolonged mechanical compression. *J Invasive Cardiol*. 2013;25:358-9.
5. Herold J, Brucks S, Boenigk H, Said SM, Braun-Dullaeus RC. Ultrasound guided thrombin injection of pseudoaneurysm of the radial artery after percutaneous coronary intervention. *Vasa*. 2011;40:78-81.

<http://dx.doi.org/10.1016/j.rec.2014.11.013>

## Apical 4-Chamber Longitudinal Strain by Vector Velocity Imaging: A Promising Predictor of Left Ventricular Ejection Fraction in Healthy Individuals



### Strain longitudinal apical 4 cámaras por vector velocity imaging: promotor predictor de fracción de eyección de ventrículo izquierdo en sujetos sanos

#### To the Editor,

Left ventricular systolic function is one of the main prognostic determinants of cardiomyopathy and left ventricular ejection fraction (LVEF), the most widely used echocardiographic parameter both in clinical practice and in large research studies. Studies with new echocardiographic techniques have shown that global left-ventricular longitudinal strain is a good predictor of early systolic dysfunction, although it shows a weak correlation with normal or mildly abnormal LVEF measured by 2-dimensional echocardiography.<sup>1,2</sup> There is little published evidence on the predictive value of myocardial strain measured by vector velocity imaging.<sup>3,4</sup> Our group has demonstrated excellent intra- and interobserver correlation for the estimation of longitudinal strain with this method, with interclass correlation coefficients of 0.97 and 0.81, respectively.<sup>5</sup>

The aim of this study was to analyze the correlation of global and regional longitudinal strain measured by vector velocity imaging with LVEF measured by 2-dimensional echocardiography in a healthy population.

The study included 51 volunteers who agreed to undergo echocardiographic examination and who were in good cardiovascular health (no cardiovascular risk factors or previous cardiovascular disease, normal physical examination and blood pressure, normal Doppler echocardiogram, and an ultrasound window appropriate for objective evaluation of LVEF and strain). Examinations were conducted with a Siemens Sequoia C-512 echocardiography scanner equipped with a 2.5-4 MHz transducer. We measured LVEF by the Simpson rule in 2- and 4-chamber views, and the study ended with the determination of regional and global longitudinal strain (tracing endocardial borders). Regional longitudinal strain (at the basal, mid cavity, and apical levels) was calculated as the mean of the maximum systolic values in the

anterior and inferior segments (2-chamber view) or in the lateral and septal segments (4-chamber view). Global longitudinal strain was calculated independently for 2- and 4-chamber views as the mean of the 6 values obtained in each case, and total global longitudinal strain was calculated as the mean of all 12 values. Qualitative variables are expressed as absolute number and percentage. Quantitative variables are shown as mean (standard deviation). Normal distribution was confirmed with the Shapiro-Wilk test, and differences between independent samples were therefore analyzed with Student's *t* test. Longitudinal strain (regional and global) and LVEF were compared by Pearson's correlation test and by uni- and multivariate analysis (simple linear regression). Differences were considered significant at  $P < .05$ .

Study population characteristics and mean values of variables are shown in [Table 1](#). Twenty-two participants (43.1%) were women. Of the 612 longitudinal strain segments recorded, 586 were analyzed (feasibility 95.7%). The 26 segments not analyzed comprised 5 at the base, 4 at mid cavity, and 4 at the apex in 4-chamber view and 4 at the base, 5 at mid-cavity, and 4 at the apex in 2-chamber view. A strong linear correlation was found between LVEF and apical 4-chamber longitudinal strain ( $R = -0.79$ ;  $r^2 = 0.62$ ;  $P = .000$ ), whereas the correlation was weak between LVEF and 4-chamber global longitudinal strain ( $R = -0.55$ ;  $r^2 = 0.3$ ;  $P = .001$ ), 2-chamber global longitudinal strain ( $R = -0.4$ ;  $r^2 = 0.16$ ;  $P = .01$ ), and total global longitudinal strain ( $R = -0.47$ ;  $r^2 = 0.23$ ;  $P = .001$ ). In the univariate analysis, basal and mid cavity strain showed no statistically significant correlation with LVEF in either the 2- or 4-chamber views (4-chamber base,  $P = .48$ ; 4-chamber mid cavity,  $P = .71$ ; 2-chamber base,  $P = .82$ ; 2-chamber mid cavity,  $P = .64$ ). In contrast, statistically significant correlations were found for 2- and 4-chamber apical strain. After the multivariate analysis, the only predictor of LVEF was 4-chamber longitudinal strain ([Table 2](#)); for every 1% reduction in 4-chamber apical longitudinal strain, LVEF increased by 1.45%.

We conclude that apical 4-chamber longitudinal strain is a good independent predictor of LVEF in healthy individuals. Given its predictive capacity and accessibility, we propose the use of this parameter as a single measure of strain in patients with conserved LVEF who require close monitoring of decreases in systolic function, for example patients undergoing chemotherapy. The explanation underlying this finding might be related to the type