

Radial and Circumferential Strain as Markers of Fibrosis in an Experimental Model of Myocardial Infarction

Strain radial y circunferencial como marcadores de fibrosis en un modelo experimental de infarto de miocardio

To the Editor,

The cardiac remodeling and left ventricular fibrosis that occur after myocardial infarction (MI) are important mediators of later development of heart failure leading to cardiovascular death.¹

Following MI, in addition to repair fibrosis, there is a remodeling of the extracellular matrix and an increase in collagen synthesis that affects the myocardium at sites far from the affected necrotic portion.² The relationship between myocardial strain, evaluated by speckle-tracking echocardiography, and the fibrosis that takes place after MI is unknown. This study analyzes the utility of radial strain (RS) and circumferential strain (CS) to assess the degree of repair fibrosis and remote fibrous tissue at the left ventricular in an experimental MI rat model.

Sham surgery was performed on 6 Wistar rats, and 6 others underwent ligation of the left anterior descending artery. Six weeks later, the rats were sacrificed.

All animals underwent echocardiography before and at one month after the procedure to obtain long-axis and short-axis images at the level of the papillary muscles. The left ventricular ejection fraction was calculated by both the Teichholz method and the Simpson method. The EchoPAC™ v110.1.2 software (GE Healthcare; Waukesha, Wisconsin, United States) was used for the analysis of short-axis images with speckle-tracking.

Hearts were sectioned at the papillary muscles, 6- μ m sections were prepared and stained with Masson trichrome, and the size of the infarct was measured every 60 μ m. Using the values obtained, the size of the MI was calculated in each heart and expressed as the percentage of infarcted area relative to the total myocardial area.

Collagen III concentration was determined by Western blot in the basal sections.

In all MI cases, the infarcted area showed histological features consistent with fibrosis (Figure). In parallel, Western blot study of areas at a distance from the infarcted tissue showed significantly higher collagen III expression in rats with MI than in sham-operated rats (Table and Figure).

At baseline, both groups presented similar RS and CS values at the papillary muscles (Table). However, at 4 weeks after the intervention, rats that underwent ligation of the anterior descending artery presented significantly lower overall RS and CS values than the sham-operated group (Table).

At 4 weeks after the procedure, CS values were significantly correlated with the end-diastolic diameter ($\rho=0.59$; $P=.04$) and the end-systolic diameter ($\rho=0.788$; $P=.002$). For RS, negative correlations were obtained for both the end-diastolic diameter ($\rho=-0.56$; $P=.055$) and the end-systolic diameter ($\rho=-0.55$; $P=.059$), with a trend to statistical significance that would likely be confirmed as significant in a larger sample size.

A significant correlation was observed between the size of the MI and collagen III concentrations ($\rho=0.709$; $P=.01$). We also found a significant correlation between the size of the MI and ejection fraction estimated by the Simpson method, RS, and CS ($\rho=-0.783$, $\rho=-0.709$, and $\rho=0.729$, respectively; $P<.01$ in all).

Collagen III concentrations correlated negatively with the ejection fraction, RS, and CS ($\rho=-0.737$, $\rho=-0.608$, and $\rho=0.823$, respectively; $P<.05$ in all) (Fig.).

Following MI, together with repair fibrosis, an increase occurs in extracellular matrix replacement and collagen synthesis that affects the non-necrotic segments and originates remodeling.² Although several studies have shown the utility of strain as a predictor of adverse remodeling following MI,³ the relationship between the reduction in strain values and the fibrosis phenomena occurring after MI remain uncertain.

In keeping with the results of previous studies,^{4,5} we found a significant reduction in RS and CS values in our rat MI model and a

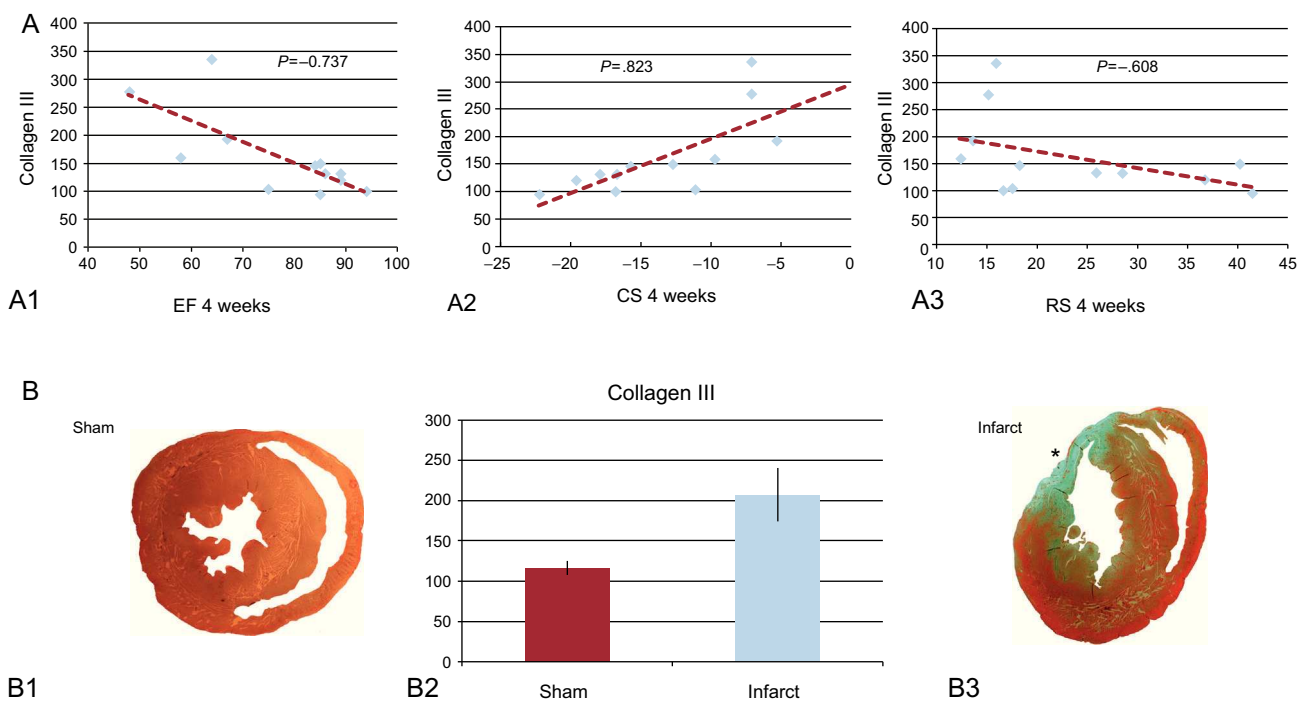


Figure. A: correlation between collagen III and the ejection fraction (A1), circumferential strain (A2), and radial strain (A3). B1 and B3: histological section at the papillary muscles obtained from a sham-operated rat (B1) and a rat with myocardial infarction (B3). B2: concentration of collagen III in an area far from the infarcted tissue (sham vs myocardial infarction). CS, circumferential strain; EF, ejection fraction; RS, radial strain. *Anterior segment transmural scar.

Table

Western Blot Results for Areas Distant From the Infarcted Tissue in Rats With Myocardial Infarction vs Sham-operated Rats

	Sham	Infarct	P
<i>Baseline</i>			
EDD, mm	5.58 (0.28)	6.01 (0.23)	.267
ESD, mm	2.57 (0.34)	2.6 (0.35)	.749
EF, %	86.33 (4.7)	92.16 (1.3)	.589
RS, %	23.01 (2.5)	34.51 (6.5)	.262
CS, %	-18.3 (0.77)	-20.01 (1.09)	.126
<i>Final</i>			
EDD, mm	5.86 (0.22)	6.8 (0.34)	.055
ESD, mm	3.00 (0.23)	4.15 (0.67)	.262
EF Simpson, %	81.66 (6.15)	53.66 (24.21)	.02
EF Teichholz, %	85.66 (2.55)	68.33 (6.3)	.041
RS, %	29.75 (4.5)	17.32 (2.3)	.037
CS, %	-16.72 (1.7)	-10.26 (1.96)	.025
Area of infarct, %	0	21.79 (1.3)	.002
Collagen III	116.46 (8.68)	207.19 (33.45)	.016

CS, circumferential strain; EDD, end-diastolic diameter; EF, ejection fraction; ESD, end-systolic diameter; RS, radial strain.

correlation between the size of the infarction scar and the reduction in strain. Furthermore, we documented greater type III collagen expression in myocardial areas far from the infarcted region that correlated with RS and CS values at the papillary muscles. This correlation would indicate that the regional RS and CS are not only a reflection of the status of myocardial function affected by the scar, but also the increase in collagen synthesis that takes place in the extracellular remodeling process occurring after MI.⁶ The correlation observed between CS and collagen III was slightly stronger than that seen between RS and collagen III. This may be because RS is a function derived from the longitudinal and circumferential shortening, whereas CS is the result of direct measurement of the circumferential shortening in a specific region of myocardium.

The main limitation of this study is that the measurements of strain and infarcted area were taken in only one plane (short axis view at the papillary muscles) due to the difficulty of obtaining views in different planes in rats.

In conclusion, this study documents a correlation of the size of the infarction scar and remote fibrosis with the RS and CS. Strain could be a marker of myocardial fibrosis following MI.

FUNDING

This study was partially supported by a research grant from Spanish Society of Cardiology.

Juan Acosta-Martínez,^{a,*} José E. López-Haldón,^a Encarnación Gutiérrez-Carretero,^a Ignacio Díaz-Carrasco,^b Tarik Smani Hajam,^b and Antonio Ordóñez Fernández^b

^aServicio de Cardiología, Hospital Universitario Virgen del Rocío, Seville, Spain

^bInstituto de Biomedicina de Sevilla (IBIS), Seville, Spain

* Corresponding author:

E-mail address: juan.acostamartinez@yahoo.es

(J. Acosta-Martínez).

Available online 18 April 2013

REFERENCES

- Cheong BY, Muthupillai R, Wilson JM, Sung A, Huber S, Amin S, et al. Prognostic significance of delayed-enhancement magnetic resonance imaging: survival of 857 patients with and without left ventricular dysfunction. *Circulation*. 2009; 120:2069–76.
- Cohn JN, Ferrari R, Sharpe N. Cardiac remodeling concepts and clinical implications: a consensus paper from an international forum on cardiac remodeling. Behalf of an International Forum on Cardiac Remodeling. *J Am Coll Cardiol*. 2000;35:569–82.
- Park YH, Kang SJ, Song JK, Lee EY, Song JM, Kang DH, et al. Prognostic value of longitudinal strain after primary reperfusion therapy in patients with anterior-wall acute myocardial infarction. *J Am Soc Echocardiogr*. 2008;21:262–8.
- Liao S, Ruan Q, Lin M, Yan L. Value of segmental myocardial strain by 2-dimensional strain echocardiography for assessment of scar area induced in a rat model of myocardial infarction. *Cardiovasc Ultrasound*. 2012;10:17.
- Popovic ZB, Benejam C, Bian J, Mal N, Drinko J, Lee K, et al. Speckle-tracking echocardiography correctly identifies segmental left ventricular dysfunction induced by scarring in a rat model of myocardial infarction. *Am J Physiol Heart Circ Physiol*. 2007;292:H2809–16.
- Weber KT, Sun Y, Tyagi SC, Cleutjens JP. Collagen network of the myocardium: function, structural remodeling and regulatory mechanisms. *J Mol Cell Cardiol*. 1994;26:279–92.

<http://dx.doi.org/10.1016/j.rec.2013.01.009>