

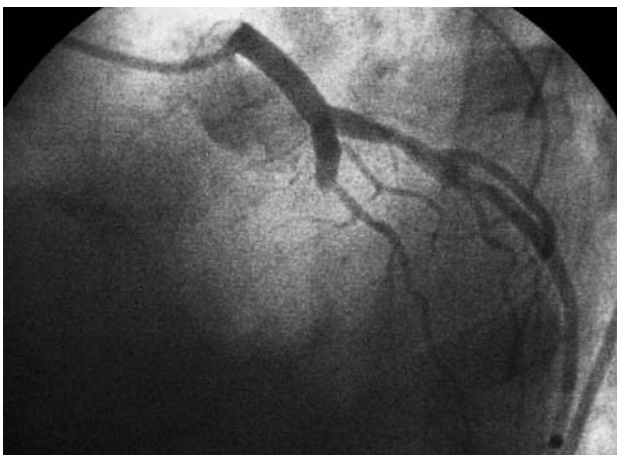

Fig. 1.

Quick Resolution with Abciximab of Giant Coronary Thrombus

A 47-year-old man with an acute anterolateral myocardial infarct more than 24 hours old and without previous fibrinolytic treatment was admitted with clinical signs of postinfarct angina. Coronary angiography revealed a complete occlusion, with thrombotic material, of the descending anterior proximal artery without visualization of the distal vein by collateral circulation (Figure 1), moderate stenosis of the circumflex artery, and extensive occupational thrombus in the median and distal segments of the right coronary artery (Figure 2A), with decreased coronary flow (TIMI II). Ventricular function was significantly reduced (IVEF=42%), with the presence of a thrombus in the apex. Before the procedure abciximab (bolus and perfusion) and 6000 U of heparin were administered. Permeability of the descending anterior artery was achieved and normal coronary flow was reestablished through implantation of a stent before dilatation with a balloon catheter. At the conclusion of the procedure (40 minutes) a new contrast injection into the right coronary artery was made, showing the complete disappearance of the thrombus on angiography (Figure 2B).

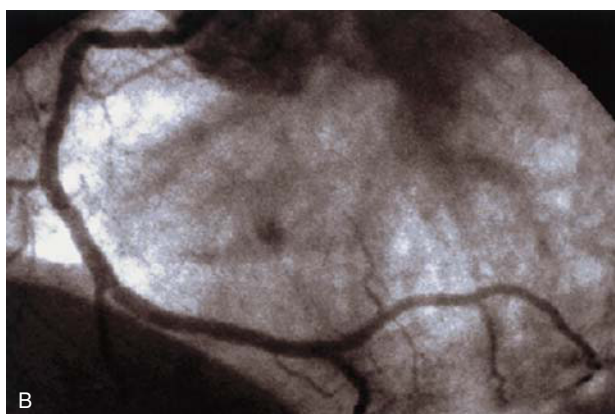
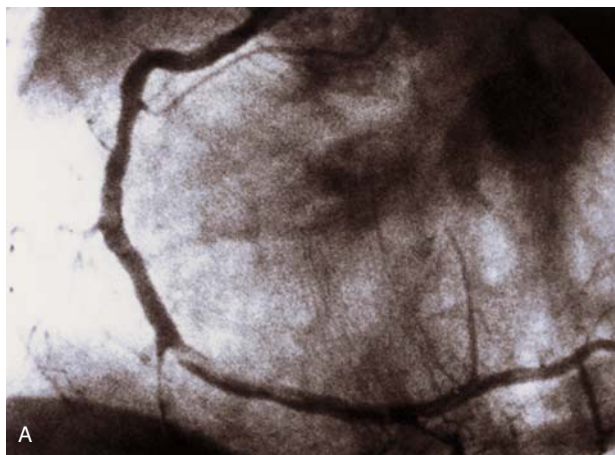


Fig. 2A y B.

The patient's clinical course was satisfactory.

We believe that the state of hypercoagulability coupled with the elevated left ventricular telediastolic pressure inherent in extensive anterior infarct contributed to the formation of a large thrombus in the right coronary artery. The administration of heparin and abciximab, together with improvement in left ventricular function after the reperfusion, enabled rapid lysis of the thrombus in the right coronary artery.

What is interesting in this case is the angiographic rendering of early lysis of a large thrombus present in an artery that had nothing to do with the infarct, found during a rescue angioplasty of the responsible artery.

Juan L. Delcán Domínguez, Eulogio García Fernández and José E. Guerrero Sanz^a

Unidad de Cardiología Intervencionista. ^aUnidad de Cuidados Intensivos. Hospital de Madrid-Montepríncipe. Madrid. España.