

Pulmonary Vein Ablation in Atrial Fibrillation. Initial Experience

José Luis Velarde^a, Ricardo Martellotto^a, Mauricio Scanavacca^b, Aldo Arévalo^a, Roberto Colque^a and Marcelo Jiménez^a

^aUnidad de Arritmias, Electrofisiología y Marcapasos. Instituto de Cardiología. Hospital Italiano. Córdoba. Argentina. ^bInstituto do Coração (InCor). Hospital das Clínicas. FM USP. São Paulo. Brasil.

Despite the progress in the knowledge of the pathophysiology of the atrial fibrillation (AF), the pharmacologic and non pharmacologic approach to prevent and control this arrhythmia has been shown to be discouraging. In the past few years a new type of AF has been described, of which the focal mechanism—especially bound to the pulmonary veins—allows ablation treatment through the radiofrequency (RF) with a catheter. We present our initial experience with this type of method, in two young patients who suffered from multiples episodes of AF and resistance to the conventional treatment. In both patients the RF ablation was done in the left superior pulmonary vein. One of them received an ablation in only one focus, and the other needed a veno-atrial disconnection through the elimination of the pulmonary venous potential from this vein. After three month of follow-up, patients remain asymptomatic with no relapse.

Key words: *Atrial fibrillation. Ablation. Radiofrequency.*

Full English text available at: www.revespcardiol.org

INTRODUCTION

In recent years new information has been published regarding the incidence, mechanisms, and treatment of atrial fibrillation (AF), as well as the effect of this arrhythmia on the quality of life and its worldwide cost to social security. AF is not only the most common cardiac arrhythmia, it is also associated with an increased risk of mortality and morbidity due to thromboembolism and cardiac insufficiency.¹⁻⁴

Correspondencia: Dr. J.L. Velarde.
Instituto de Cardiología. Hospital Italiano.
Sarmiento 1595. B.º General Paz. Córdoba. 5000 Argentina.
E-mail: cardiologia@hospital-italiano.com.ar

Recibido 1 de February 2001.
Accepted for publicación 29 august de 2001.

Ablación de las venas pulmonares en la fibrilación auricular. Experiencia inicial

A pesar del avance en el conocimiento de la fisiopatología de la fibrilación auricular, el tratamiento farmacológico y no farmacológico para controlar y prevenir esta arritmia es con frecuencia desalentador. En los últimos años se ha descrito un tipo de fibrilación auricular cuyo mecanismo focal—especialmente ligado a las venas pulmonares—permite el tratamiento mediante la ablación con catéter con radiofrecuencia (RF). Presentamos nuestra experiencia inicial con este tipo de terapéutica en 2 pacientes jóvenes con múltiples episodios de fibrilación auricular y refractarias al tratamiento convencional. En ambos pacientes se realizó la ablación con radiofrecuencia en la vena pulmonar superior izquierda. En uno de ellos se realizó ablación en un único foco y en el otro se llevó a cabo la desconexión venoauricular mediante la eliminación de un potencial venoso pulmonar en dicha vena. Tras un seguimiento de 3 meses, los pacientes permanecen asintomáticos, sin recurrencia de su arritmia.

Palabras clave: *Fibrilación auricular. Ablación. Radiofrecuencia.*

In spite of this information, pharmacological and non-pharmacological (surgery or catheterization) treatment for the control and prevention of AF is usually discouraging.⁵⁻⁸

Recently, focal ablation in or near the ostium of 1 of more pulmonary veins has been proposed an alternative treatment, based on the electrophysiological evidence that the ectopic beats that generate AF originate in these regions.⁹⁻¹³

We present our first 2 cases of radiofrequency (RF) ablation of pulmonary veins in young patients with multiple AF episodes that were refractory to pharmacologic anti-arrhythmia intervention.

Radiofrequency ablation procedure

Medications (flecainide and propafenone) were discontinued in both patients 15 days prior to the study.

By Seldinger technique, puncturing the left femoral vein, a quadripolar USCI 6 Fr catheter was introduced and positioned in the upper part of the right atrium, near the mouth of the superior venas cava, and via puncture of the right jugular vein an octapolar 6 Fr IBI catheter was introduced and positioned within the coronary chest. After puncture of the right femoral vein, 2 transseptal punctures were made and 2 7 Fr IBI catheters were introduced, with 4 mm distal deflectable electrodes and temperature control for mapping the left atrium and pulmonary veins.

Endocavity electrogram tracing was obtained with a computerized polygraph (Feas Electrónica model 1415-Córdoba, Argentina) and the temperature-controlled RF applications made with a Feas Electrónica model 7000 generator.

CLINICAL CASES

Case 1

A 34-year-old woman with a history of rapid, irregular, and nearly permanent palpitations from approximately 7 years of age. In 1998, at another center, an electrophysiological study was performed and the presence of nodal tachycardia and anomalous leaks was ruled out. Her diagnosis at the time of the study was multifocal atrial tachycardia with episodes of atrial fibrillation (AF). She was referred to our center for diagnosis and treatment.

Electrocardiogram revealed atrial tachycardia with episodes of FA (Figure 1). Complementary studies (chest X-ray, complete laboratory studies, thyroid function tests, and 2-dimensional Doppler echocardiogram) did not reveal cardiac or extracardiac

changes. A 24-hour Holter monitor showed a sinus rhythm alternating with rapid atrial tachycardia and episodes of AF, with multiple isolated atrial extrasystoles or extrasystoles that initiated the arrhythmia. She had been treated with various anti-arrhythmia medications (etenolol, amiodarone, flecainide, and propafenone) without effective control of the arrhythmia being achieved.

With regard to the study and ablation, at the beginning of the study the patient presented with an irregular, permanent tachycardia with some sinus beats. We proceeded to map the atrial extrasystoles causing the bursts of tachyarrhythmia. After selective mapping of the 4 pulmonary veins, the existence of an early electrogram in the left superior pulmonary vein was observed as the source of the irregular tachycardia, with sudden changes in the cycle length (AF pattern on electrocardiograph). The earliest atrial electrogram in the coronary chest was 56 ms (Figure 2). Two RF applications were performed at this site, 1 at a temperature of 60 °C for 60 seconds, with interruption of the tachycardia being noted after the first application (Figure 3). Later, we attempted to reproduce the tachycardia with overstimulation, using 2 extrastimuli with and without isoproterenol, without being able to achieve any type of arrhythmia.

At 3-month followup, the patient remained in a stable sinus rhythm, without taking any medication. There was no evidence of palpitations and a 24-hour Holter revealed a sinus rhythm during the entire recording.

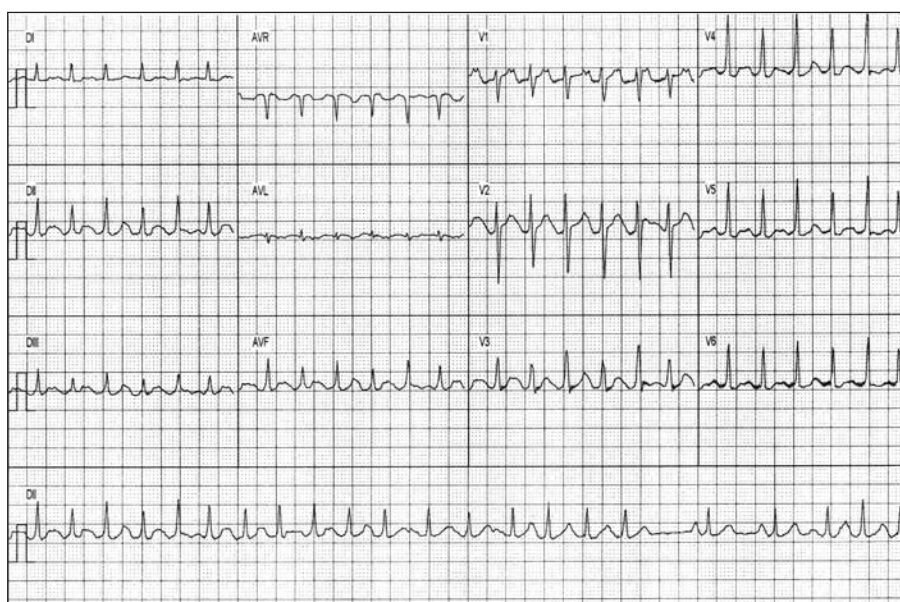


Fig. 1. Case 1. ECG showing irregular tachycardia (atrial fibrillation pattern) with some sinus beats.

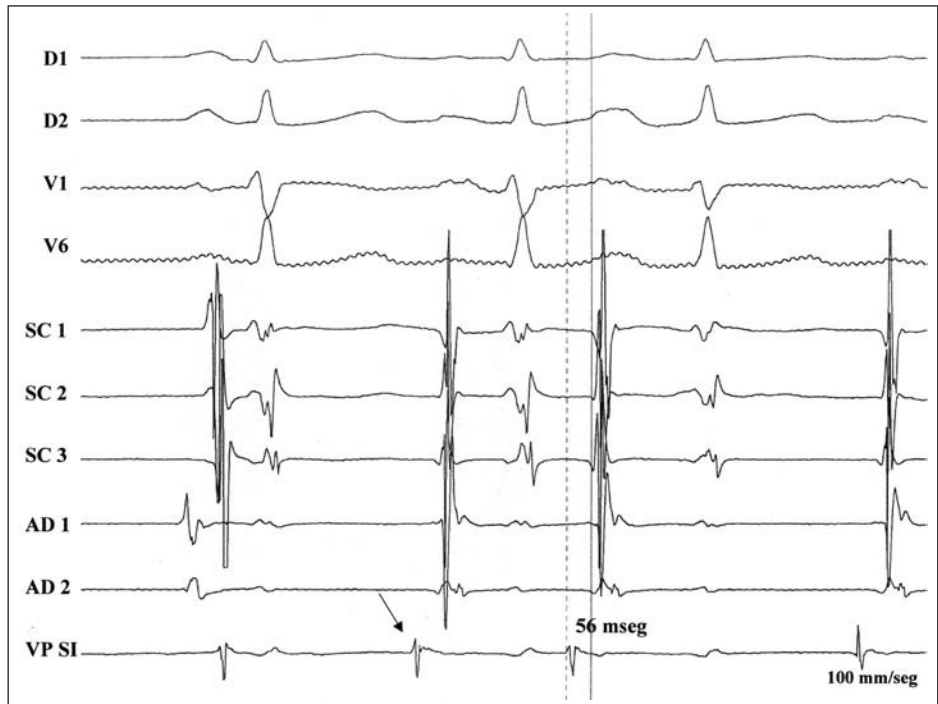


Fig. 2. Case 1. Tracing of the electrograms showing the initiation of tachyarrhythmia (the first beat is sinusoidal), with the greatest precocity in the LSPV. CC indicates coronary chest; RA, right atrium; LSPV, left superior pulmonary vein.

Case 2

The patient was a 26-year-old man with an 8-year history of irregular palpitations and an electrocardiographic diagnosis of AF. He suffered multiple crises that required hospital admission on 7 occasions, with electric cardioversion performed on 6 occasions. Other episodes of AF were treated on an outpatient basis, reverting with the administration of amiodarone or quinidine, or both.

Complementary studies revealed normal laboratory results (including thyroid function) and an unchanged chest X-ray. 2-dimensional Doppler echocardiogram showed a left atrium measuring 4.1 cm, and the rest of the cavities and ventricular function were normal. A 24-hour Holter monitor showed a permanent AF rhythm with short periods of sinus rhythm. An electrophysiological study was performed in 1998 to evaluate the presence of

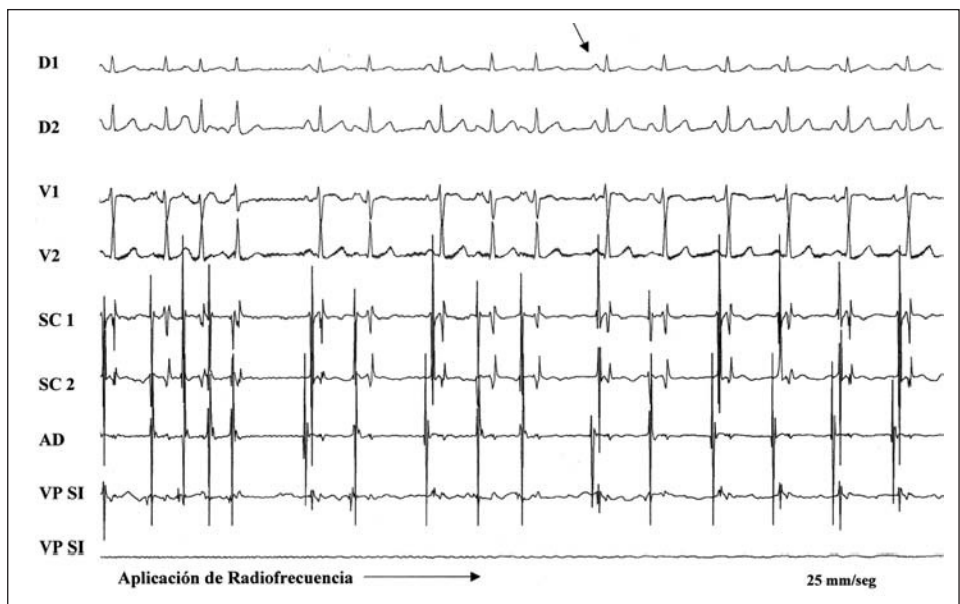


Fig. 3. Case 1. Tracing showing the application of radiofrequency to the LSPV, with the interruption (arrow) of the tachyarrhythmia. CC indicates coronary chest; RA, right atrium; LSPV, left superior pulmonary vein.

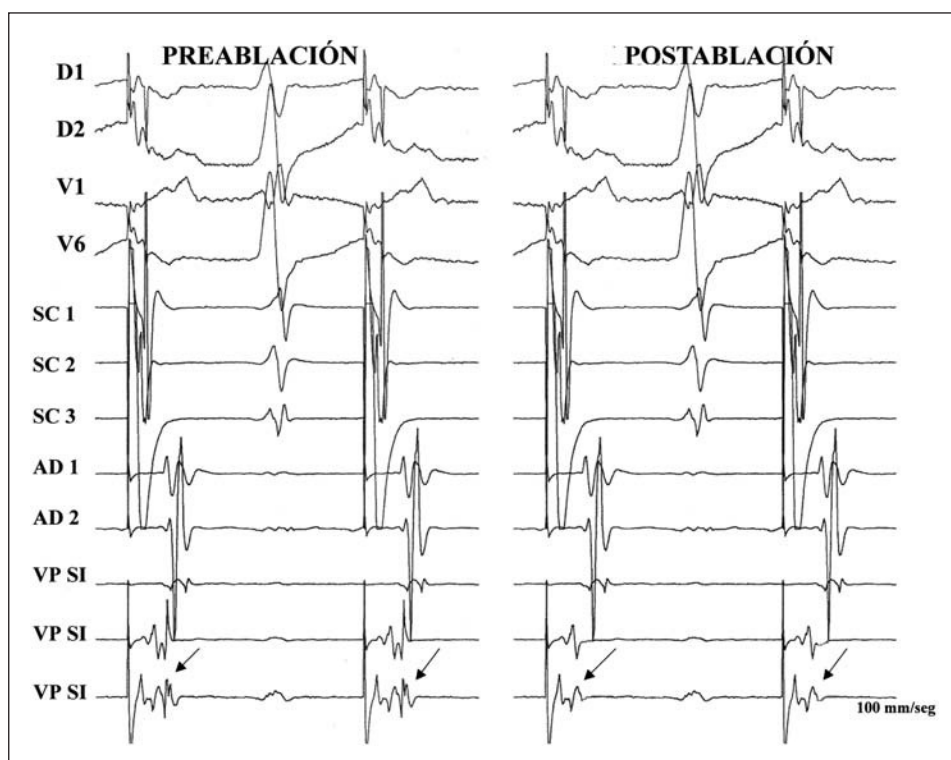


Fig. 4. Case 2. Tracing of the electrograms pre- and post-stabilization during stimulation in the coronary chest. Before ablation, a small potential can be seen at the end of the LSPV electrograms (arrow) and its posterior elimination in the same. CC indicates coronary chest; RA: right atrium; LSPV: left superior pulmonary vein.

anomalous leaks and nodal tachycardia, or both. Once these arrhythmias were discounted, we were only able to induce AF.

The patient was medicated alternately with atenolol, amiodarone, propafenone, flecainide, and sotalol, without effective control of his crisis.

Because of his arrhythmia, the patient underwent psychological changes and developed had difficulty working and was unable to enjoy his usual sport activities; he required treatment by a specialist and specific medication (sertraline) for his psychiatric problems.

Regarding the study and ablation, the patient was in a sinus rhythm at the beginning of the procedure. In spite of trying to induce tachyarrhythmia by various methods (overstimulation, vagal manipulation, and the administration of isoproterenol and adenosine), we could not reproduce it. We decided to map the 4 pulmonary veins to see whether venous potentials were present and attempt disconnection if that were the case. During continuous stimulation of the coronary chest, we recorded a venous potential in only the left superior vena cava, where we performed 10 RF applications at 50 °C for 30 seconds around the ostium, until this potential was eliminated (enoatrial isolation) (Figure 4).

Later, during isoproterenol overstimulation, we were able to induce typical, self-limited atrial flutter, but not AF. For this reason, RF ablation of the cavotricuspid isthmus was performed, and the

presence of a bidirectional block was observed in this area, which made it impossible to reintroduce atrial flutter.

At 3-month followup, the patient continued to be in sinus rhythm, was taking 300 mg de propafenone (we decided to continue pharmacological treatment for arrhythmia in this case), and did not have palpitations. A 24-hour Holter revealed a permanent sinus rhythm without arrhythmias. The patient had returned to work and his sporting activities, and no longer required psychiatric medication.

The procedures were performed for 125 and 225 minutes, respectively. There were no complications during or following the studies.

DISCUSSION

Recently, a pioneer group led by Haissaguerre has shown that foci that fire rapidly in or near pulmonary veins may be the reason for arrhythmias in some patients who suffer from paroxysmal AF.^{9,10} In paroxysmal AF, an arrhythmogenic focus may be the only abnormality in some patients in whom the focus discharges for long periods of time (focal FA). More commonly, a brief string of focal discharges triggers AF that subsequently continue independently of the initiation of the AF event (focally initiated AF). In some patients, paroxysmal AF seems to have a focal origin (focally initiated AF), and these foci are predominantly tied to the pulmonary veins. On rare

occasions, the triggers may originate in other veins (superior or inferior vena cava, Marshall ligament, coronary chest) or in the atrial tissue (particularly of the left posterior atrium). The importance of this focal mechanism is due to the possibility of curative treatment via catheter ablation, as has been shown by Haissaguerre and other investigators.¹³⁻¹⁵

For mapping pulmonary veins, a transeptal uncton and placement of 1 or 2 catheters in the veins must be undertaken. In patients with isolated atrial extrasystoles or extrasystoles that initiate non-sustained AF, earlier mapping of the focus of origin and successful ablation can be performed, with the elimination of the extrasystoles.¹⁰

Case 1 presented with these characteristics, and ablation of the AF trigger focus located in the left superior pulmonary vein completely eliminated the arrhythmia. Mapping was relatively easy, given the practically continuous presence of the arrhythmia..

At other times it is not possible to observe the atrial extrasystoles or initiation of AF, so that in sinus rhythm or during stimulation of the left atrium, small potentials corresponding to the pulmonary veins can be seen. The application of RF to 1 or more pulmonary veins achieves disconnection of these potentials, which appears to be an excellent outcome of the procedure.^{13,16}

In case 2, the procedure was more difficult due to the impossibility of inducing extrasystoles or AF. Given the patient characteristics, we decided to map the pulmonary vein potentials and were able to observe a potential in the left superior vein, and we proceeded to perform venoatrial disconnection at that site. As it was not possible to reproduce the arrhythmia, the purpose of this procedure was the elimination of this potential. Given the parameters of the case, the result of the procedure, and the high possibility of AF recurrence, we decided to keep the patient on anti-arrhythmia medication, and the patient continued to be asymptomatic during the short followup period.

Beyond the random successes reported in different published studies, ablation of AF still frequently presents problems (difficulty in mapping the extrasystole triggers of AF; the presence of multiple foci that trigger AF; application of RF causing stenosis of the pulmonary veins and thromboembolism, and the high rate of recurrence),^{13,14,17,18} and we still do not know the long-term result of this procedure.

In spite of the fact that our knowledge of the mechanisms and physiopathology of AF has increased, and in spite of enormous technological advances, RF ablation of FA is still only used for a small group of patients with paroxysmal AF who are very symptomatic, refractory to multiple medications, or young, with frequent atrial extrasystoles or short repetitive bursts of irregular atrial tachycardia.

REFERENCES

1. Feinberg WM, Blackshear JL, Laupacis A. Prevalence, age distribution and gender of patients with atrial fibrillation: analysis and implications. *Arch Intern Med* 1995;155:469-73.
2. Kopecky SL, Gersh BJ, McGoon MD, Whisnant JP, Holmes DR Jr, Ilstrup DM, et al. The natural history of lone atrial fibrillation: a population-based study over three decades. *N Engl J Med* 1987; 317:669-74.
3. Barriales Álvarez V, Moris de la Tassa C, Sánchez Posada I, Barriales Villa R, Rubin López J, de la Hera Galarza JM, et al. Estudio de la etiología y factores de riesgo asociados en una muestra de 300 pacientes con fibrilación auricular. *Rev Esp Cardiol* 1999; 52:403-14.
4. Prystowsky EN, Benson DW, Fuster V. Management of patients with atrial fibrillation: a statement for healthcare professionals from the subcommittee on electrocardiography and electrophysiology. American Heart Association. *Circulation* 1996;93:1262-77.
5. Langberg JJ, Chin M, Schamp DJ. Ablation of atrioventricular junction with radiofrequency current energy using a new electrode catheter. *Am J Cardiol* 1991;67:142-7.
6. Cox JL, Boineau JP, Schuessler RB, Kater KM, Lappas DG. Five years experience with the maze procedure for atrial fibrillation. *Ann Thorac Surg* 1993;56:814-23.
7. Swartz JF, Pellersels G, Silvers J. A catheter-based curative approach to atrial fibrillation in humans. *Circulation* 1994; 90: 1335.
8. Haissaguerre M, Jais P, Shah DC, Gencel L, Pradeau V, Garrigues S, et al. Right and left atrial radiofrequency catheter therapy of paroxysmal atrial fibrillation. *J Cardiovasc Electrophysiol* 1996;7:1132-44.
9. Jais P, Haissaguerre M, Shah DC, Chouairi S, Gencel L, Hocini M, et al. A focal source of atrial fibrillation treated by discrete radiofrequency ablation. *Circulation* 1997;95:572-6.
10. Haissaguerre M, Jais P, Shah DC, Takahashi A, Hocini M, Quiniou G, et al. Spontaneous initiation of atrial fibrillation by ectopic beats originating in the pulmonary veins. *N Engl J Med* 1998; 339:659-66.
11. Jais P, Haissaguerre M, Shah DC, Chouairi S, Gencel L, Hocini M, et al. A focal source of atrial fibrillation treated by discrete radiofrequency ablation. *Circulation* 1997;95:572-6.
12. Chen SA, Hsieh MH, Tai CT. Initiation of atrial fibrillation by ectopic beats originating from the pulmonary veins: electrophysiologic characteristics, pharmacological responses, and effects of radiofrequency ablation. *Circulation* 1999;100:1879-86.
13. Haissaguerre M, Shah DC, Jais P, Hocini M, Yamane T, Deisenhofer II, et al. Mapping-guided ablation of pulmonary veins to cure atrial fibrillation. *Am J Cardiol* 2000;86(Suppl 1):K9-K19.
14. Chen SA, Tai CT, Hsieh MH, Tsai CF, Ding YA, Chang MS. Radiofrequency catheter ablation of atrial fibrillation initiated by spontaneous ectopic beats. *Europace* 2000;2:99-105.
15. Peinado Peinado R, Merino Llorens JL, Gómez Guindal JA, Sobrino Daza JA. Fibrilación auricular focal: ablación con catéter mediante radiofrecuencia. *Rev Esp Cardiol* 1998;51:494-97.
16. Haissaguerre M, Jais P, Shah DC, Garrigue S, Takahashi A, Lavergne T, et al. Electrophysiological end point for catheter ablation of atrial fibrillation initiated from multiple pulmonary venous foci. *Circulation* 2000;101:1409-17.
17. Scanavacca MI, Kajitqa LJ, Vieira M, Sosa E. Pulmonary vein stenosis complicating catheter ablation of focal atrial fibrillation. *J Cardiovasc Electrophys* 2000;11:677-81.
18. Kay Neal G. Catheter ablation of atrial fibrillation: challenges and promise. *Am J Cardiol* 2000;86(Supl 1):K25-K27.