

**Proximal Left Anterior Descending Artery Acute Occlusion With an Unusual Electrocardiographic Pattern: Not Everything Is ST Elevation**



**Oclusión aguda de la arteria descendente anterior proximal con patrón electrocardiográfico inusual: no todo es ascenso del ST**

**To the Editor,**

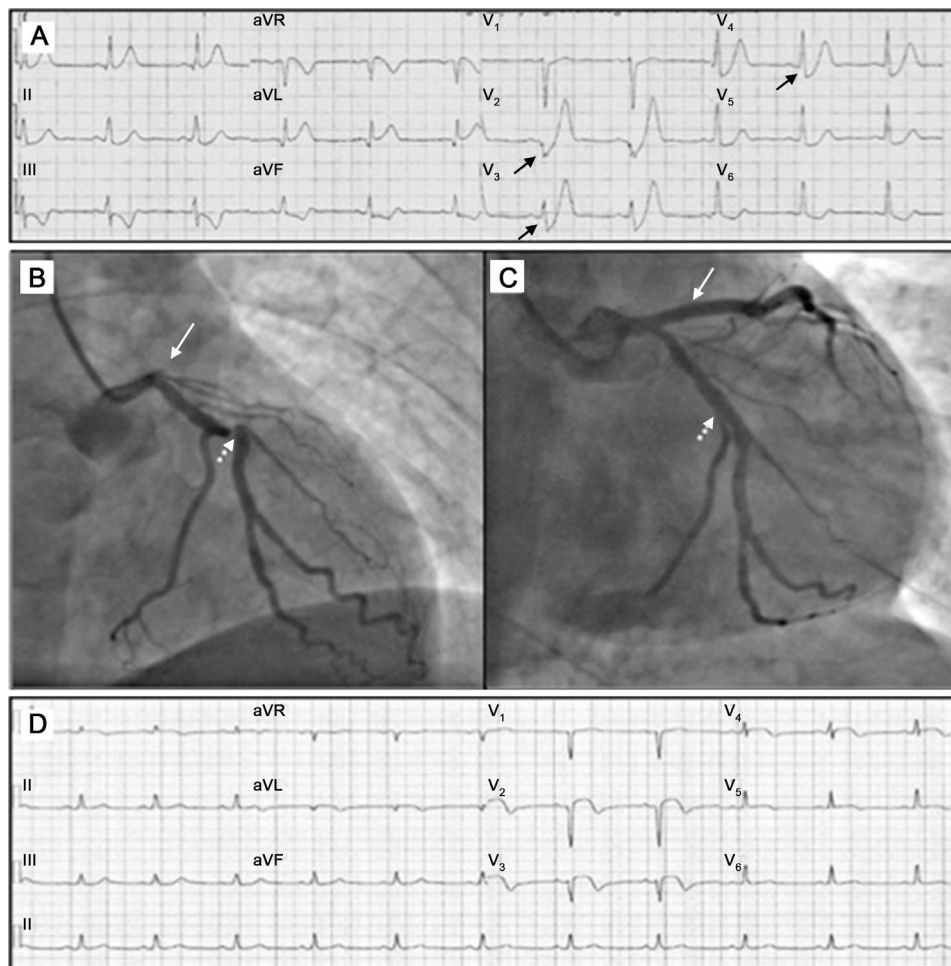
Early detection of electrocardiogram (ECG) abnormalities indicative of acute coronary artery occlusion is crucially important to identify candidates for emergency revascularization. In most cases, ST elevation is the finding that enables diagnosis to be established. However, in some situations, ST elevation corresponding to the territory affected by coronary artery occlusion may not be present, resulting in a delay in reperfusion treatment and larger infarcted areas.

We present 2 cases of acute occlusion of the left anterior descending artery with an uncommon but characteristic ECG pattern.

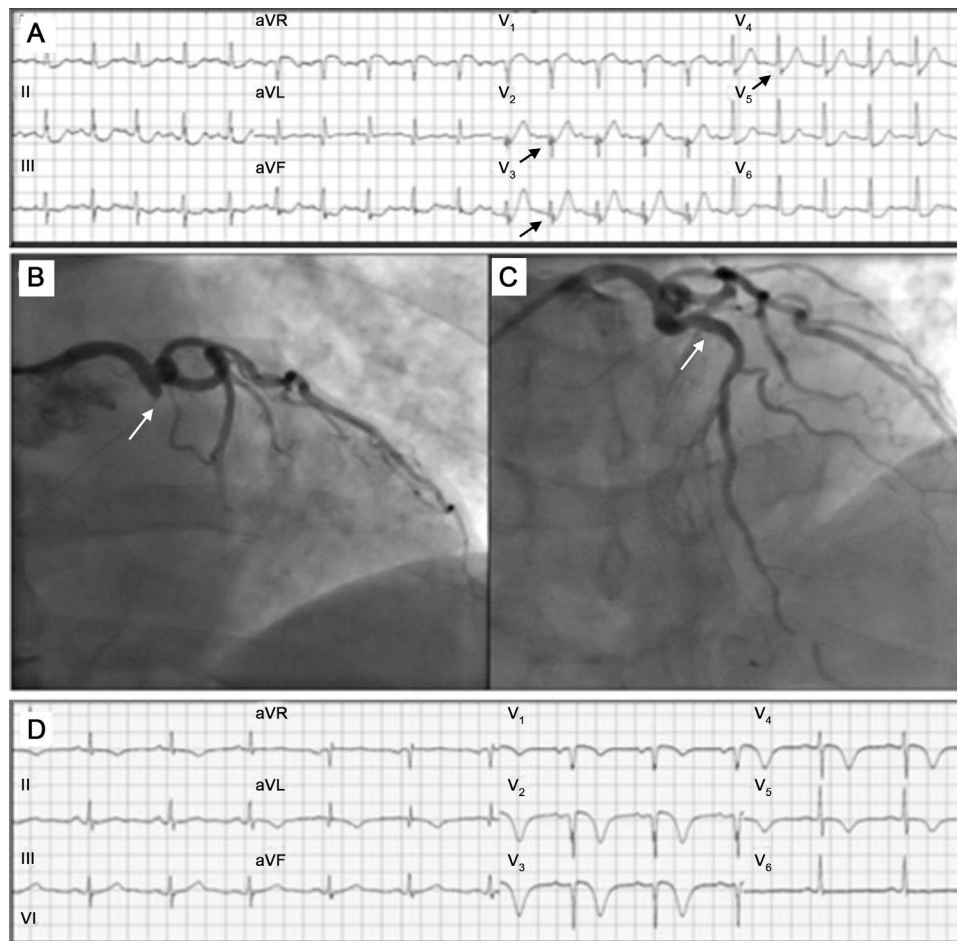
The first patient was 61-year-old man with no relevant history of cardiac events, who was attended at home by the emergency

services for acute chest pain. In the first ECG performed, approximately 30 minutes after onset of pain, marked ST-segment depression of up to 3 mm was observed after the J point, with steep Q and T waves in the precordial leads V<sub>2</sub>-V<sub>5</sub>, 0.5 mm ST elevation in leads aVL and aVR, and ST-segment depression of 1 mm in the inferior leads (Figure 1A). The patient was referred to the catheterization laboratory, where total occlusion of the left anterior descending artery (Figure 1B) was observed with no collateral filling. The lesion was treated by angioplasty and placement of a drug-eluting stent. During the same procedure, 2 lesions with 70% occlusion of the circumflex artery and the right coronary artery were treated by angioplasty and stent placement (Figure 1C). The ECG recorded after the procedure (Figure 1D) showed electrical abnormalities characteristic of the outcome of an anterior infarction, with QS complexes in V<sub>1</sub>-V<sub>2</sub>, rS in lead V<sub>3</sub>, persistent ST elevation, and a negative T wave.

The second patient was a 65-year-old man with no relevant history, who was attended for sudden chest pain. The first ECG once again showed ST-segment depression of up to 3 mm after the J point, with minimal Q wave, loss of R wave progression, and prominent T waves in the precordial leads (particularly in leads V<sub>2</sub>-V<sub>3</sub>) (Figure 2A). In this case, there was ST elevation in lead aVR of up to 1.5 mm, Q wave in lead aVL, and ST-segment depression in the inferior leads, which reached 2 mm in lead II. Emergency



**Figure 1.** A: Electrocardiogram at 30 minutes after onset of pain; De Winter complexes can be seen in leads V<sub>2</sub>-V<sub>4</sub>. B: Occlusion of the left anterior descending artery (arrows) and significant stenosis of the circumflex artery (shaded arrows). C: Coronary angiography after angioplasty; reperfusion of the left anterior descending artery (arrow) and the circumflex lesion after treatment (shaded arrow) can be observed. D: Electrocardiogram after the procedure; image of the outcome of the anterior infarction, with Q waves in leads V<sub>1</sub>-V<sub>2</sub> and persistent elevation of the ST segment in leads V<sub>2</sub>-V<sub>5</sub>, I, and aVL.



**Figure 2.** A: Electrocardiogram at 120 minutes after onset of pain, with De Winter complexes in leads V<sub>2</sub>-V<sub>5</sub> (arrows). B: Occlusion of the left anterior descending artery (arrow). C: Reperfusion of the left anterior descending artery after angioplasty and stent placement (arrow). D: Electrocardiogram after the procedure; image of the outcome of the anterior infarction, with Q waves in leads V<sub>1</sub>-V<sub>3</sub>, minimal ST elevation, and T wave negativity in leads V<sub>1</sub>-V<sub>5</sub>.

coronary angiography showed thrombotic occlusion of the left anterior descending artery (Figure 2B) with no distal collateral filling. The lesion was treated by angioplasty and placement of a drug-eluting stent (Figure 2C). The ECG recorded after the procedure (Figure 2D) once again showed the typical outcome of an anterior infarction.

The first description of this unusual ST-segment depression associated with a hyperacute T wave was made more than 50 years ago in a patient with recent-onset angina and subsequent ECG progression of the anterior infarction.<sup>1</sup> However, it was De Winter et al<sup>2,3</sup> who reported this ECG pattern (consisting of an upsloping ST-segment depression after the J point with a rising gradient in precordial leads, prominent positive and symmetric T waves, loss of R wave progression and, occasionally, simultaneous elevation of 1-2 mm in lead aVR) in 2% of the patients in a series of 1532 patients with occluding anterior infarction of the left anterior descending artery. Unlike the known transient hyperacute T waves of the initial phase of the infarction, the pattern was detected a mean of 1.5 hours after symptom onset (in our case, 30 and 120 minutes after onset of pain, respectively). Lack of ST elevation in the course of infarction is common. ST elevation was not detected in ECGs taken prior to revascularization in either of our patients. Likewise, the infarcted area after coronary reperfusion was characteristically extensive. The exact electrophysiological mechanisms underlying the changes described are not known.

Although most protocols for the management of infarction emphasize ST elevation as the indication for emergency reperfusion strategies, appropriate training of health care workers is needed so they can identify the ECG patterns that point to acute occlusion or critical coronary stenosis in the absence of ST elevation in leads associated with affected territory.<sup>4,5</sup> Given the potential morbidity and mortality resulting from failure to recognize these findings, knowledge of this pattern should be mandatory for all professionals who attend patients with chest pain.

José M. Montero-Cabezas,\* Frank van-der-Kley,  
Ioannis Karalis, and Martin J. Schalij

*Interventional Cardiology Unit, Department of Cardiology,  
Leiden University Medical Center, Leiden, The Netherlands*

\*Corresponding author:  
E-mail address: [jmmonterocabezas@gmail.com](mailto:jmmonterocabezas@gmail.com)  
(J.M. Montero-Cabezas).

Available online 7 May 2015

## REFERENCES

1. Dressler W, Roesler H. High T waves in the earliest stage of myocardial infarction. *Am Heart J.* 1947;34:627-46.

2. De Winter RJ, Verouden NJ, Wellens HJ, Wilde AA. A new ECG sign of proximal LAD occlusion. *N Engl J Med*. 2008;359:2071–3.
3. Verouden NJ, Kock KT, Peters RJ, Henriques JP, Baan J, van der Schaaf RJ, et al. Persistent precordial “hyperacute” T-waves signify proximal left anterior descending artery occlusion. *Heart*. 2009;95:1701–6.
4. Gorgels AP. ST-elevation and non-ST elevation acute coronary syndromes: should the guidelines be changed? *J Electrocardiol*. 2013;46:318–23.
5. Birnbaum Y, Bayés de Luna A, Fiol M, Nikus K, Macfarlane P, Gorgels A, et al. Common pitfalls in the interpretation of electrocardiograms from patients with acute coronary syndromes with narrow QRS: a consensus report. *J Electrocardiol*. 2012;45:463–75.

<http://dx.doi.org/10.1016/j.rec.2015.02.014>