

Primary Cardiac Lymphoma: Diagnosis by Transjugular Biopsy

Ángela Flox Camacho,^a Felipe Hernández Hernández,^a Rafael Salguero Bodes,^a Ignacio Sánchez Pérez,^a Amparo Carbonell Porras,^b and Juan Tascón Pérez^a

^aUnidad de Hemodinámica y Cardiología Intervencionista, Hospital 12 de Octubre, Madrid, Spain

^bUnidad de Cuidados Intensivos Coronarios, Hospital 12 de Octubre, Madrid, Spain.

Primary cardiac lymphoma, defined as a non-Hodgkin's lymphoma involving only the heart and pericardium, is an extremely rare malignancy. It should be suspected in patients with a heart mass and heart failure, unexplained refractory pericardial effusion or rhythm disturbances. Transvenous intracardiac tumor biopsy under fluoroscopic or transesophageal echocardiographic guidance, is a minimally invasive technique which makes definite diagnosis possible. We describe a patient in whom primary cardiac lymphoma was diagnosed by this technique. He also underwent percutaneous balloon pericardiectomy because of severe refractory pericardial effusion. Seven months after diagnosis and treatment with standard chemotherapy, the patient remained free of disease.

Key words: *Cardiac tumor. Pericardial effusion. Echocardiography.*

Full English text available at: www.revespcardiol.org

Linfoma cardíaco primario: diagnóstico mediante biopsia transyugular

El linfoma cardíaco primario, definido como linfoma no hodgkiniano con afección exclusiva del corazón y pericardio, es un tumor maligno extremadamente raro. Debe sospecharse en pacientes con masas cardíacas y fallo cardíaco, derrame pericárdico refractario o trastornos del ritmo. La biopsia transvenosa, bajo control fluoroscópico o por ecocardiografía transesofágica, es un procedimiento mínimamente invasivo que permite el diagnóstico definitivo. Presentamos un caso de linfoma cardíaco primario diagnosticado mediante esta técnica y al que se practicó una pericardiectomía percutánea con balón por derrame pericárdico severo recidivante. El paciente está libre de enfermedad tras tratamiento quimioterápico 7 meses después del diagnóstico.

Palabras clave: *Tumor cardíaco. Derrame pericárdico. Ecocardiografía.*

INTRODUCTION

Primary cardiac lymphoma (PCL) is a rare tumor that progresses rapidly. This characteristic and the fact that the diagnosis is often made late in the course of the disease contribute to a poor prognosis. Primary cardiac lymphoma is defined as non-Hodgkin's lymphoma involving only the heart and pericardium or a large tumor located in the heart.^{1,2} It is predominantly found in the right chambers. Associated symptoms are non-specific and depend on the location of the tumor and its extension. Imaging techniques are important for the diagnosis of this process, but definite diagnosis

is established by histological study.³ Transvenous biopsy is currently the most advantageous technique for this purpose. Primary cardiac lymphoma is an aggressive tumor and treatment is based on polychemotherapy.⁴ Although the prognosis is poor and there are no long-term follow up studies on this condition, early diagnosis and appropriate, aggressive treatment may result in longer survival.

CASE REPORT

A 64-year-old man with hypertension and psoriatic arthropathy under treatment with methotrexate and cyclosporine was admitted to his referral hospital for right heart failure. Transthoracic echocardiography detected severe pericardial effusion without hemodynamic compromise. The electrocardiogram demonstrated atrial flutter and high-degree atrioventricular block at 40 bpm. Steroid treatment was initiated, the effusion decreased to a moderate level and a VVI pa-

Correspondence: Dra. A. Flox Camacho.
Unidad de Hemodinámica y Cardiología Intervencionista.
Servicio de Cardiología. Hospital 12 de Octubre. Avda. de Córdoba, s/n.
28041 Madrid, España.
E-mail: angelaflox@terra.es

Received 24 March 2003.

Accepted for publication 6 August 2003.

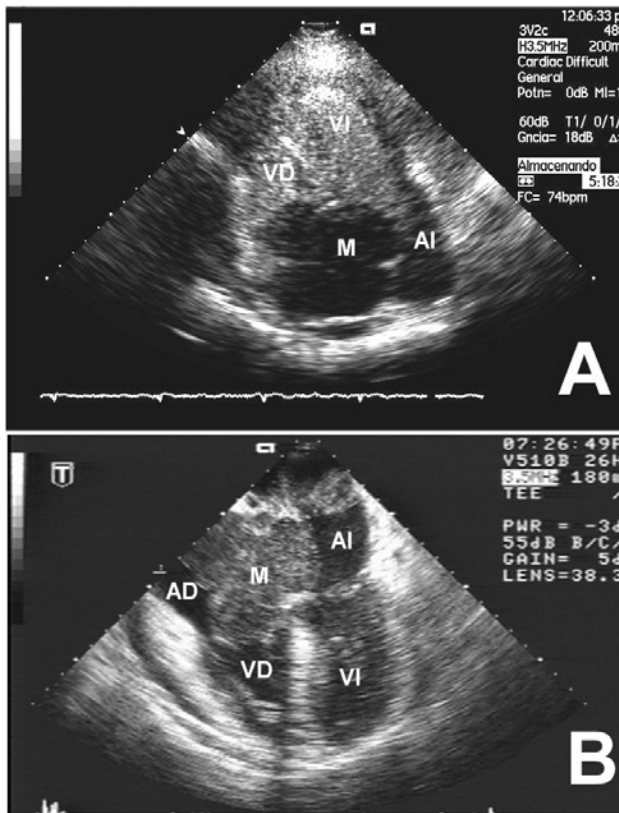


Fig. 1. A: transthoracic echocardiogram, apical four-chamber view after intravenous contrast injection. B: transesophageal echocardiogram, four-chamber view without contrast. RA indicates right atrium; LA, left atrium; M, mass; LV, left ventricle; RV, right ventricle.

emaker was implanted. Three months later the patient was hospitalized for biventricular cardiac insufficiency. A new echocardiogram revealed mild effusion and a large mass in the right atrium. The patient was then transferred to our hospital where another echocardiogram with intravenous contrast (Levovist®) confirmed the tumor (Figure 1A). Transesophageal echocardiography and contrast-enhanced helical CT scanning showed that the mass originated in the atrial septum, extended to both atria and occupied nearly the entire right atrium (Figures 1B and 2A). No mediastinal lymphadenopathy was detected. Since recurrence of the effusion caused hemodynamic instability, we performed draining pericardiocentesis and percutaneous pericardiotomy with a valvuloplasty balloon (BALT Crystal 45/20 mm) using a subxiphoid approach, and right transjugular biopsy of the mass (Figure 3). Pathology studies of the pericardial fluid and tissue from the atrial mass identified diffuse, high-grade B-cell non-Hodgkin's lymphoma. Bone marrow biopsy showed no lymphoma infiltration. Chemotherapy was initiated according to the CHOP protocol (cyclophosphamide, vincristine, doxorubicin and prednisone). A new helical CT scan one week af-

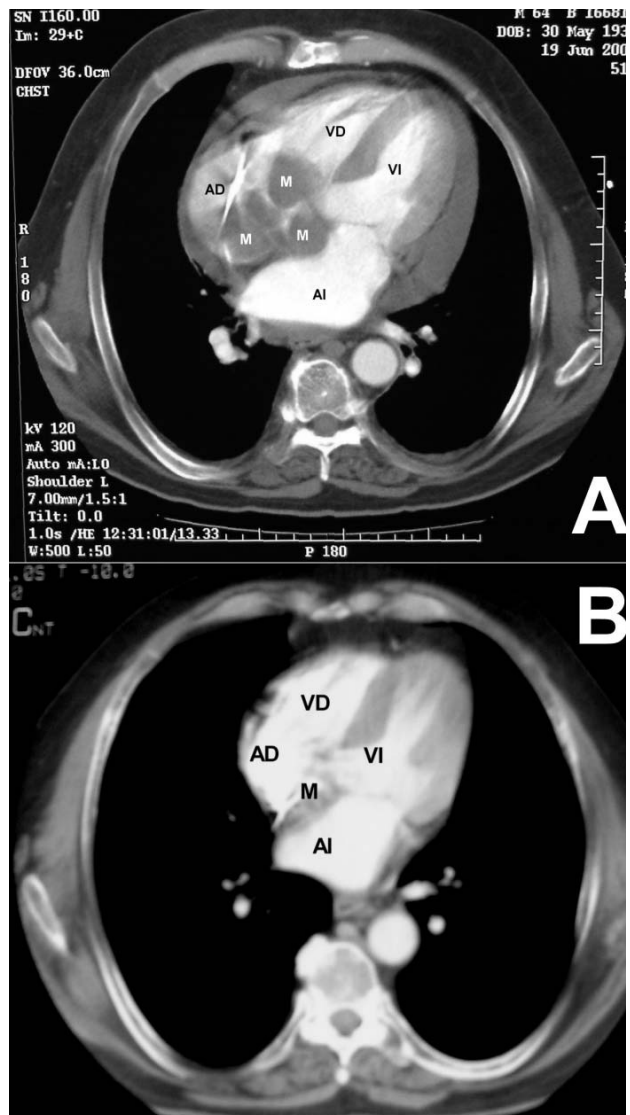


Fig. 2. A: contrast-enhanced helical CT image. The artifact in the RA is caused by a pacemaker electrode. B: contrast-enhanced helical CT image after chemotherapy. RA indicates right atrium; LA, left atrium; M, mass; LV, left ventricle; RV, right ventricle.

ter the start of treatment demonstrated a 40% reduction in the size of the mass (Figure 2B). Transthoracic echocardiography performed five months later showed no evidence of an intracardial mass or pericardial fluid. Seven months after the diagnosis the patient remained free of disease and there was no recurrence of effusion.

DISCUSSION

Primary cardiac tumors are extremely rare. Their incidence in autopsy studies of unselected populations varies from 0.0017% to 0.19%, and in some series is as high as 0.21%. Some 75% of these tumors are benign and the most frequent are myxomas.⁵ Primary

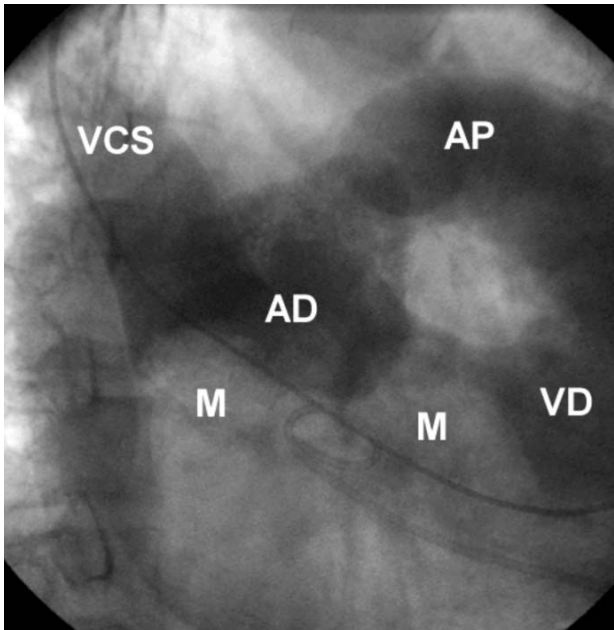


Fig. 3. Fluoroscopic image after transjugular administration of contrast medium. Pig-tail catheter inserted in the pericardial cavity. Pacemaker electrode passing from the superior vena cava toward the apex of the right ventricle. A mass is apparent in the right atrium. RA indicates right atrium; PA, pulmonary artery; M, mass; SVC, superior vena cava; RV, right ventricle.

cardiac lymphoma accounts for only 1.3% of primary cardiac tumors and 0.5% of extranodal lymphomas. Some 80% are diffuse, large B-cell non-Hodgkin's lymphoma, showing high-grade malignancy and rapid growth. Up to 28% of disseminated lymphomas infiltrate the heart. The most frequent location of PCL is the right atrium, followed by the pericardium. Signs and symptoms are non-specific and depend on the location and extent of the tumor; these include right-sided heart failure precordial pain, arrhythmias, conduction disorders and cardiac tamponade. Diagnosis is usually late in the course of the disease, a fact that contributes to the poor prognosis.^{3,4} In the case presented, the tumor was not detected on the first echocardiogram, although it must have been present since there was right-sided heart failure, and the effusion did not cause hemodynamic compromise. It should be mentioned that it is not appropriate to treat cardiac effusion of unknown origin with corticoids.

Although diagnostic imaging techniques are important in this condition, the definite diagnosis is made on the basis of pathological study. Pericardial fluid cytology is positive in up to 88% of cases, although the specificity is low.⁶ The presence of atypical lymphoid cells can also indicate reactive lymphocytosis or other neoplasms. In inconclusive cases, immunohistochemistry, flow cytometry, and cytogenetic study can define the lymphocyte line and detect the monoclonal population, findings that suffice to establish the diag-

nosis and initiate chemotherapy.³

Although in our case the two diagnostic procedures were done simultaneously, biopsy can be used to obtain tissue samples when pericardial fluid cannot be taken. Open thoracotomy and mediastinoscopy have a 100% success rate; however, these procedures are aggressive and are not without morbidity and mortality.³ Currently, the most accessible diagnostic method is transesophageal echocardiography-guided transjugular biopsy, which is highly effective for obtaining samples (100% success)³ and has a relatively low risk of complications (tamponade, tumor embolization, arrhythmias, valve damage, pneumothorax and vasovagal reactions).⁷⁻⁹ Because echocardiographic study of the atrium provided excellent visualization of the mass in our patient, transesophageal echocardiography was not used.

Balloon pericardiotomy, a percutaneous version of the subxiphoid surgical approach, is a simple procedure for treating patients with severe recurrent pericardial effusion. Its low rate of associated complications makes it preferable to other surgical options in patients with effusions of neoplastic origin.¹⁰⁻¹² To our knowledge, the use of this technique in patients with PCL has not been reported up to now.

With regard to the treatment of these tumors, there has been no evidence of increased survival with surgery. Polychemotherapy seems to be the best therapeutic option, although the prognosis continues to be poor. Early diagnosis together with aggressive treatment may prolong the life of these patients.^{3,4} Heart transplantation has been considered a therapeutic alternative in patients with primary cardiac tumors and poor response to conventional treatment. To date, there are very few reported cases treated in this way, with sarcoma being the tumor most frequently involved. It is still not clear what effect chemotherapy and immunosuppressor treatment may have on the graft; thus, the benefits of this strategy need to be more extensively assessed.^{13,14}

REFERENCES

1. McAllister HA, Fenoglio JJ. Tumors of the cardiovascular system. Atlas of tumor pathology. 2nd series. Fascicle 15. Washington DC: Armed Forces Institute of Pathology, 1978; p. 73-109.
2. Cairns P, Butany J, Fulop J, Rakowski H, Hassaram S. Cardiac presentation of non-Hodgkin's lymphoma. Arch Pathol Lab Med 1987;111:80-3.
3. Ceresoli GL, Ferreri A, Bucci E, Ripa C, Ponzoni M, Villa E. Primary cardiac lymphoma in immunocompetent patients. Diagnostic and therapeutic management. Cancer 1997;80:1497-506.
4. Porcar Ramells C, Clemente González C, García Parés D, Guardia Sánchez R, Pérez Ayuso M, García-Bragado Dalmau F. Linfoma cardíaco primario: diagnóstico citológico y tratamiento con respuesta a poliquimioterapia y autotrasplante de precursores

- hematopoyéticos. Presentación de un caso y revisión de la literatura. *An Med Interna* 2002;19:305-9.
5. Gabe ED, Rodríguez Correa C, Vigliano C, San Martino J, Wisner JN, González P, et al. Mixomas cardíacos: correlación anatomoclínica. *Rev Esp Cardiol* 2002;55:505-13.
 6. Springgs AI, Vanhegan RI. Cytological diagnosis of lymphoma in serous effusions. *J Clin Pathol* 1981;34:1311-25.
 7. Salka S, Siegel R, Sagar KB. Transvenous biopsy of intracardiac tumor under transesophageal echocardiographic guidance. *Am Heart J* 1993;125:1782-4.
 8. Unger P, Kentos A, Cogan E, Renard M, Crasset V, Stoupel E. Primary cardiac lymphoma: diagnosis by transvenous biopsy under transesophageal echocardiographic guidance. *J Am Soc Echocardiogr* 1998;11:89-91.
 9. Jurkovich D, Marchena E, Bilsker M, Fierro-Renoy C, Temple D, García H. Primary cardiac lymphoma diagnoses by percutaneous intracardiac biopsy with combined flurosopic and transesophageal echocardiographic imaging. *Cathet Cardiovasc Intervent* 2000;50:226-33.
 10. Palacios I, Murat Tuzcu E, Ziskind A, Younger J, Block P. Percutaneous balloon pericardial window for patients with malignant pericardial effusion and tamponade. *Cathet and Cardiovas Diagn* 1991;22:244-9.
 11. Ziskind A, Craig A, Lemmon C, Burstein S, Gimple L, Herrmann H, et al. Percutaneous balloon pericardiotomy for the treatment of cardiac tamponade and large pericardial effusions: description of technique and report of the first 50 cases. *J Am Coll Cardiol* 1993;21:1-5.
 12. Navarro del Amo LF, Córdoba Polo M, Orejas Orejas M, López Fernández T, Mohandes M, Iñíguez Romo A. Pericardiotomía percutánea con balón en pacientes con derrame pericárdico recurrente. *Rev Esp Cardiol* 2002;55:25-8.
 13. Jiménez Mazuecos JM, Fuentes Manso R, Segovia Cubero J, Toquero Ramos J, Oteo Domínguez JF, Alonso-Pulpón Rivera L. ¿Es útil el trasplante cardíaco como tratamiento del sarcoma cardíaco primario? *Rev Esp Cardiol* 2003;56:408-11.
 14. Gowdamarajan A, Michler RE. Therapy for primary cardiac tumors: is there a role for heart transplantation? *Curr Opin Cardiol* 2000;15:121-5.