

Image in cardiology

Postpartum Multivessel Spontaneous Coronary Artery Dissection



Diseción coronaria espontánea multivaso en el puerperio

Luis Enrique Lezcano Gort,* Sebastián Alejandro Romani, and Cecilio Raúl Rodríguez Carreras

Unidad de Hemodinámica y Cardiología Intervencionista, Servicio de Cardiología, Hospital San Pedro de Alcántara, Cáceres, Spain

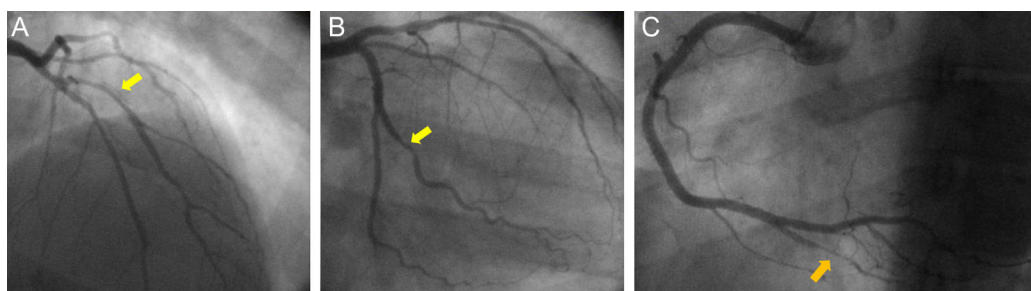


Figure 1.

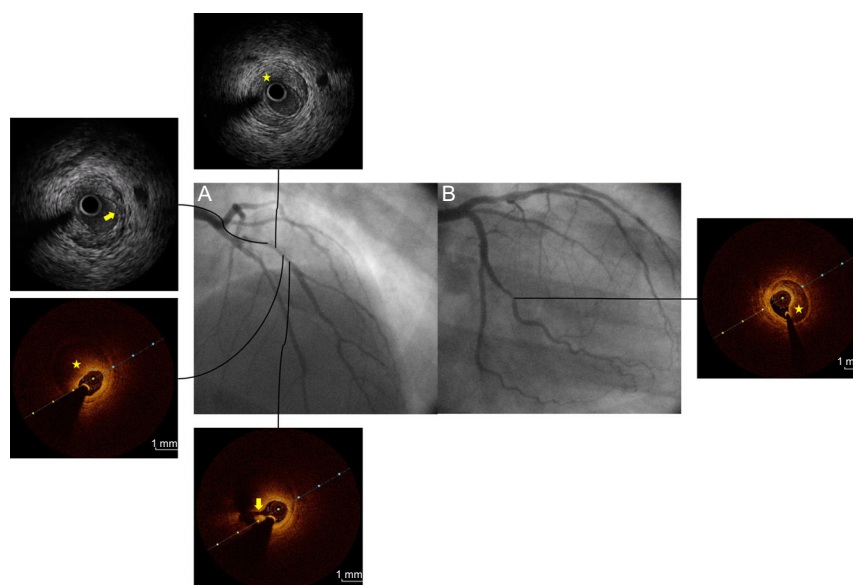


Figure 2.

A 40-year-old postpartum woman with no relevant clinical history was admitted for myocardial infarction without ST segment elevation 12 days after a natural delivery. Emergency coronary angiography showed dissection of the first diagonal branch of the left anterior descending artery, an intermediate lesion in the second obtuse marginal branch of the circumflex artery, and severe stenosis in the right posterior descending artery (Figure 1, arrows). In the diagonal branch, intracoronary ultrasound and optical coherence tomography confirmed intramural hematoma (Figure 2A, asterisks) and an intimal flap (Figure 2A, arrows). Optical coherence tomography revealed an intramural hematoma causing stenosis of the obtuse marginal artery (Figure 2B, asterisk) but this finding was not confirmed in the posterior descending artery due to procedure failure (poor image quality). Two overlapping bioabsorbable stents were implanted in the diagonal side branch, with the end adjusted to the bifurcation. Another 2 overlapping bioabsorbable stents were positioned in the main left anterior descending artery, from the bifurcation along the length of the hematoma. The stents were inflated using the kissing balloon technique (Figure 3).

* Corresponding author:

E-mail address: lezcanogort@gmail.com (L.E. Lezcano Gort).

Available online 8 April 2016

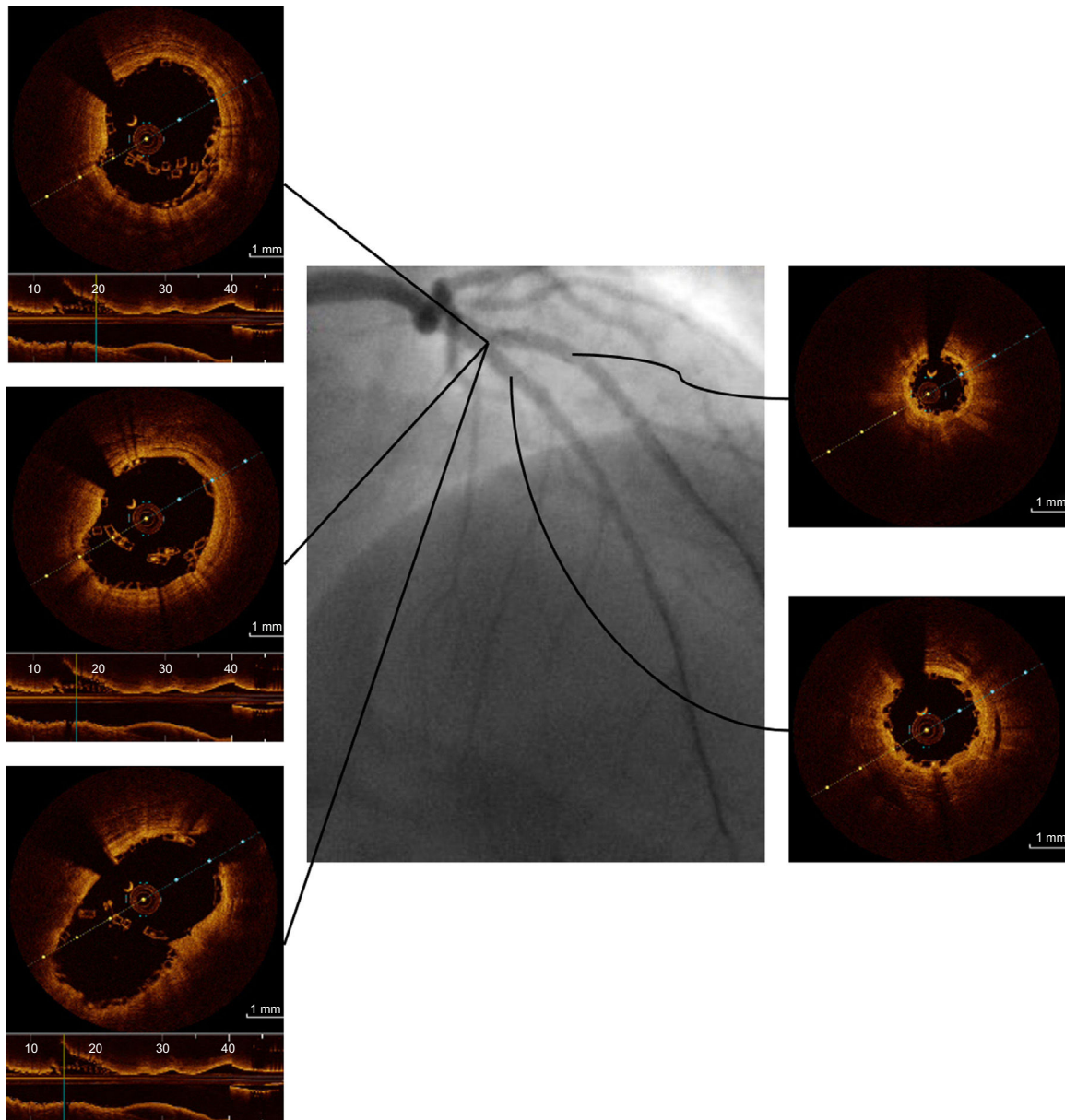


Figure 3.

Spontaneous coronary artery dissection is a major cause of acute coronary syndrome in women younger than 50 years, with a prevalence of up to 30%. The condition develops from a predisposing arterial disease, such as fibromuscular dysplasia or pregnancy-associated disease. The advent of intracoronary imaging techniques has greatly improved recognition of this condition. Treatment is conservative in most cases, and the decision to revascularize (via percutaneous or surgical intervention) depends on the patient's clinical status and the affected part of the coronary anatomy. The use of bioabsorbable stents has the theoretical advantage of avoiding inadequate late apposition after reabsorption of the intramural hematoma.