

Pitfalls in Left Atrial Reduction. Superior Neo-Cava with Pericardium

Ovidio A. García-Villarreal^a, Amadeu B. Gouveia^a, Edgardo López-Mata^a, Martha Bermúdez^b and Rubén Argüero^c

^aDepartamentos de Cirugía Cardiorácica y ^bMedicina Nuclear. Hospital Regional N.º 34. IMSS. Monterrey. Nuevo León. México.

^cDepartamento de Cirugía Cardíaca. Hospital de Cardiología. Centro Médico Nacional Siglo XXI. IMSS. México, DF. México.

Left atrial reduction is a surgical technique that has been proposed for eliminating chronic atrial fibrillation associated with mitral valve disease. A potential complication of the technique is the unnoticed rotation of the heart while the left atrium is anastomosed. Such an event makes it impossible to reconstruct the superior vena cava, leading to superior vena cava syndrome due to the rotation of that vessel. We report our experience with a case of left atrial reduction and rotation of the superior vena cava while it was being anastomosed. The complication was successfully resolved by placing an autologous pericardial tube between the two ends of the superior vena cava.

Key words: *Atrial fibrillation. Mitral valve. Atrium. Surgery.*

Full English text available at: www.revespcardiol.org

Errores en la reducción auricular izquierda. Neo-cava superior con pericardio

La reducción auricular izquierda es una técnica quirúrgica que ha sido propuesta para eliminar la fibrilación auricular crónica asociada a la enfermedad valvular mitral. Una de las potenciales complicaciones del uso de esta técnica es la rotación inadvertida del corazón durante la anastomosis de la aurícula izquierda. Esto imposibilita la correcta reconstitución de la vena cava superior, resultando en un síndrome de vena cava superior debido a la torsión de la misma. Se presenta aquí la experiencia de un caso de reducción auricular izquierda con torsión de la vena cava superior en el momento de su anastomosis, problema que se solventó con éxito mediante el uso de un tubo de pericardio autólogo interpuesto entre ambos extremos de la vena cava superior.

Palabras clave: *Fibrilación auricular. Válvula mitral. Aurícula. Cirugía.*

INTRODUCTION

Left atrial reduction has been proposed by Sankar¹ as an alternative for eliminating chronic atrial fibrillation (AF) associated with mitral valve disease. We have performed this procedure in 17 patients during mitral valve surgery; nevertheless, this surgery involves risks, such as the inadvertent rotation of the left atrium (LA) when it is anastomosed. The displacement of the heart to the right, including the proximal portion of the superior vena cava (SVC), makes correct anastomosis impossible. In such cases, alternative surgical techniques must be used in order to avoid a superior vena cava syndrome.

Correspondence: Dr. Ovidio A. García-Villarreal
Vista Florida, 460, Col. Linda Vista.
67130 Guadalupe. Nuevo León. México.
E-mail: ovidio@voila.fr

Recibido el 9 de marzo de 2001.

Aceptado para su publicación el 18 de septiembre de 2001.

CLINICAL CASE

A 47-year-old woman was diagnosed with a double mitral valve lesion and chronic AF, and was categorized as New York Heart Association (NYHA) functional capacity III. She underwent surgery in February of 2001. A Carbomedics Inc. 29 mm mechanical mitral valve prosthesis (Austin, Tex., USA) was implanted. A left atrial reduction was performed to eliminate the chronic AF.² The SVC could not be anastomosed directly due to inadvertent displacement of the heart to the right. A superior neocava was constructed at the base of the patient's pericardium, using a Hegar dilator as a mold (Figure 1). The superior and inferior ends of the pericardium were anastomosed to the ends of sectioned SVC, re-establishing normal cardiopulmonary flow to the right atrium (Figure 2). Cardiopulmonary bypass was utilized for 140 minutes, and aortic clamping for 110 minutes during the left atrial reduction procedure. The

ABBREVIATIONS

LA: left atrium
 AF: atrial fibrillation
 SVC: superior vena cava

construction and anastomosis of the superior neocava was performed with the aorta unclamped and the heart beating. Normal sinus rhythm resumed as soon as the aorta was unclamped. The patient's post-operative course was uneventful and there was no sign of SVC syndrome. Radioisotope superior venocavography was performed using sulfur-99mTc colloid 5 days after surgery (Figure 3) and was repeated 3 months post-surgery—these studies showed graft permeability. A transmitral flow Doppler echocardiograph showed post-operative recovery of left atrial functional capacity upon reappearance of the atrial «a» wave, which had been absent previously. The study also revealed a significant reduction in LA size.

DISCUSSION

Mitral valve disease is one of the most common causes of chronic AF,³ especially when the LA is large. Nevertheless, valve surgery *per se* does not eliminate this arrhythmia in the majority of cases. Various surgical techniques have been proposed.^{1,2,4-9} We have successfully used the atrial reduction technique described by Sankar¹ in 17 patients who underwent mitral valve surgery with concomitant chronic AF; eliminating chronic AF with this technique is highly effective.^{1,2} Experimental studies by Chorro et al¹⁰ have shown that when the atria are distended, they can cause both atrial flutter patterns and complete re-entries. This can be eradicated by the formation of obstacles secondary to surgical suture lines, which can also eradicate complete areas of arrhythmia, such as in the base of the left atrial appendage. The technique also incorporates 2 principles cited by Cox:⁴ isolation of the AF reentrant microcircuits in the LA and reduction of the LA critical mass. This procedure consists of isolating the pulmonary vein heads and extirpation of a circumferential band of LA tissue that

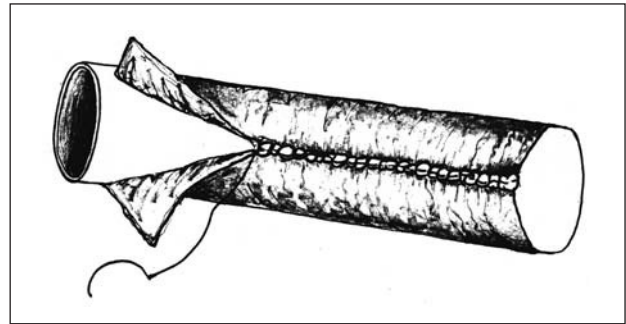


Fig. 1. This illustration shows how to construct an autologous pericardial tube using a Hegar dilator as a mold.

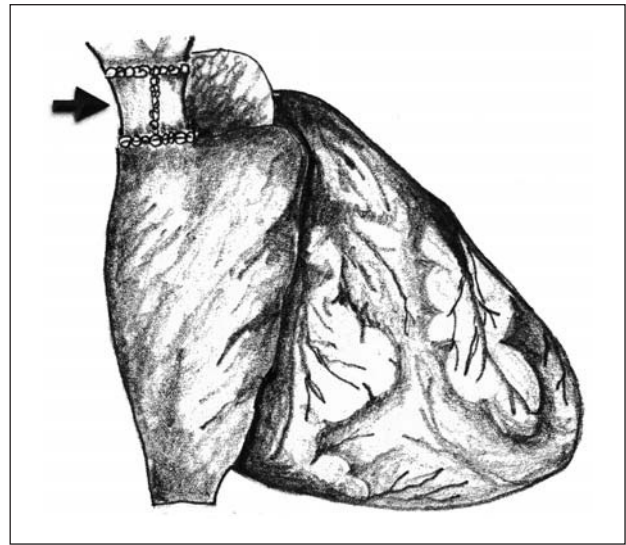


Fig. 2. Artist's rendition of the interposition of the autologous pericardial tube in the superior vena cava. The arrow indicates the pericardial graft.

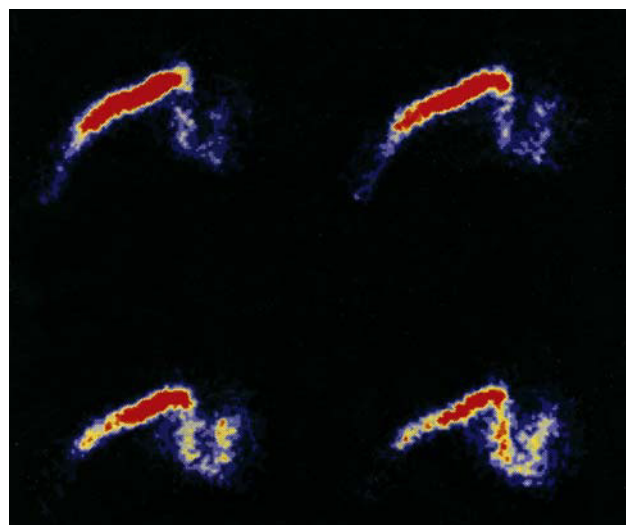


Fig. 3. Radioisotope superior venocavography (5 days post-surgery). The images obtained reveal the adequate flow of radiopharmaceutical material (sulfur-99mTc colloid) through the subclavian vein, superior vena cava, and the right cardiac cavities, indicating graft permeability.

TABLA 1. Left atrium values on transthoracic echocardiography

Values	Pre-operative	Post-operative
Anteroposterior diameter, mm	57	45
Superoinferior diameter, mm	61	49
Transverse diameter, mm	55	47
Area, cm ² *	36.01	23.94

*Area calculated by planimetry.

includes the base of the left appendage and anastomosis of the LA. The SVC is resected transversely to expose the roof of the LA.

LA transport function can be determined by echocardiographic study.¹¹ The re-establishment of LA transport function can be established by electrocardiography when the «a» wave is apparent after this surgical procedure is performed to eliminate AF. Nevertheless, this new technique is not without complications. We found a potential complication of this procedure is the inadvertent torsion of the heart to the right when performing the LA reconstruction, making it impossible to re-suture the SVC directly because of the risk of developing SVC syndrome caused by partial or total obstruction of the SVC. In the case presented here, this problem was successfully solved by using an autologous pericardial tube to ensure SVC permeability. The interposition of the superior neocava of the pericardium was performed with aortic clamping, with the heart beating, without increasing the duration of cardiopulmonary bypass by more than 25 minutes.

In conclusion, we believe that the use of an autologous pericardial tube to prevent unanticipated SVC torsion during left atrial reduction is an excellent surgical option.

ACKNOWLEDGEMENT

We would like to thank Miss Maria del Carmen Colomer for her valuable assistance in preparing this manuscript.

BIBLIOGRAFÍA

1. Sankar NM, Farnsworth AE. Left atrial reduction for chronic atrial fibrillation associated with mitral valve disease. *Ann Thorac Surg* 1998;66:254-6.
2. García-Villarreal OA, Rodríguez H, Treviño A, Gouveia AB, Argüero R. Left atrial reduction and mitral valve surgery: the «functional-anatomic unit» concept. *Ann Thorac Surg* 2001;71:1044-5.
3. Barriales Álvarez V, Morris de la Tassa C, Sánchez Posada I, Barriales Villa R, Rubin López J, De la Hera Galarza JM et al. Estudio de la etiología y factores de riesgo asociados en una muestra de 300 pacientes con fibrilación auricular. *Rev Esp Cardiol* 1999; 52:403-14.
4. Cox JL, Schuessler RB, D'Agostino HJ, Stone CM, Chang BC, Cain ME, et al. The surgical treatment of atrial fibrillation. III. Development of a definitive surgical procedure. *J Thorac Cardiovasc Surg* 1991;101:569-83.
5. Cox JL. The surgical treatment of atrial fibrillation. IV. Surgical technique. *J Thorac Cardiovasc Surg* 1991;101:584-92.
6. Cox JL. Evolving applications of the maze procedure for atrial fibrillation. *Ann Thorac Surg* 1993;55:578-80.
7. Defauw JJ, Guiraudon GM, van Hemmel NM, Vermeulen FE, Kingma H, De Baker JM. Surgical therapy of paroxysmal atrial fibrillation with «the corridor» operation. *Ann Thorac Surg* 1992; 53:564-71.
8. Isomura H, Hisatomi K, Hirano A, Maroyama H, Kosuga K, Ohishi K. Left plication and mitral valve replacement for giant left atrium accompanying mitral lesion. *J Cardiac Surg* 1993;8: 365-70.
9. Hioki M, Ikeshita M, Iedokoro Y, Nitta T, Harada A, Assano T et al. Successful combined operation for mitral stenosis and atrial fibrillation. *Ann Thorac Surg* 1993;55:776-8.
10. Chorro FJ, Mainar L, Sanchis J, Canoves J, Porres JC, Guerrero J et al. Patrones de activación durante la fibrilación auricular en un modelo experimental. *Rev Esp Cardiol* 1999;52:327-38.
11. Albirini A, Scalia GM, Murray D, Chung MK, McCarhty PM, Griffin BP, et al. Left and right transport function after maze procedure for atrial fibrillation: an echocardiographic Doppler follow-up study. *J Am Soc Echocardiogr* 1997;10:937-45.