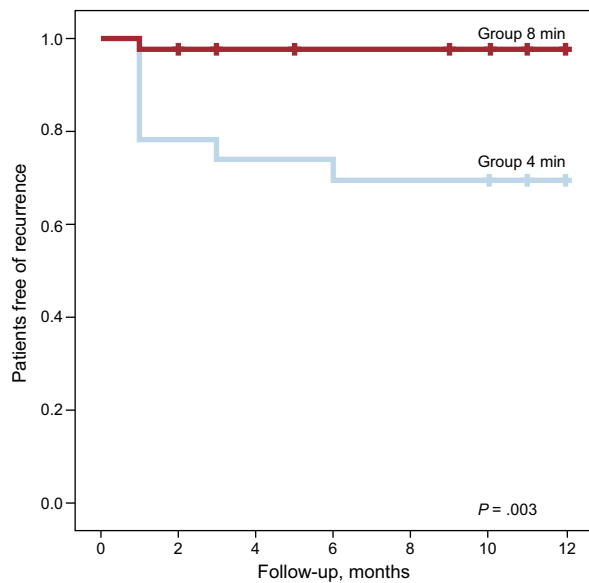

**Figure.** Outcomes presented as a Kaplan-Meier plot of recurrence after cryoablation. Red line: 8-minute application group; blue line: 4-minute application group.

21 patients with complete abolition of conduction through the slow pathway (recurrence rate of 9.5%) were compared with the 41 patients with residual conduction through the slow pathway with a single echo beat (recurrence rate of 14.6%,  $P = .4$ ). The other variables analyzed were not associated with a higher recurrence rate.

The main findings in this series of patients with nodal reentrant tachycardia treated with cryoablation with an 8-mm catheter are as follows: *a*) we confirmed that the initial efficacy in an adult population is very high, with similar success rates to those obtained with radiofrequency ablation; *b*) the safety profile was excellent, even with 8-mm catheters, which do not allow cryomapping; *c*) our results suggest that the recurrence rate during the first year can be reduced by extending the duration of initially successful application to 8 minutes; *d*) modification of the slow pathway was not found to be important, as failure to detect anterograde conduction was not associated with better clinical outcome than residual conduction inducing a single echo beat.

The most controversial aspect of cryoablation is the higher recurrence rate associated with this technique compared with radiofrequency (10% vs 4%, respectively).<sup>1</sup> There is a lack of

comparative studies, but the recurrence rates in the published series with 8-mm catheters of around 5% are lower than those reported with cryoablation with 4- and 6-mm catheters and are similar to those reported with radiofrequency ablation. These results may have been influenced by the conditions in which cryoablation was applied. For example, Chan et al,<sup>3</sup> who reported a relapse rate of 5.6%, performed a security freeze in the same area as the successful application, and Peyrol et al,<sup>4</sup> who reported a recurrence rate of 4.9%, also mention that they performed an additional application of 4 minutes at the site of successful application. Bearing in mind that tissue adherence is lost during periods of heating and thus precision may be lost, we decided to simply extend the duration of cryoapplications from 4 minutes to 8 minutes in our patients.

If low recurrence rates were to be confirmed in larger prospective series when applications are extended to 8 minutes, this catheter and application method could improve the outcomes of treatment of nodal reentrant tachycardia with cryoablation.

Eduardo Castellanos,\* Jesús Almendral, Rafael Peinado, Jefferson Salas, and Mercedes Ortiz

Unidad de Electrofisiología Cardíaca y Arritmología Clínica, Centro Integral de Enfermedades Cardiovasculares, Hospital Universitario Montepríncipe, Grupo HM Hospitales, Universidad CEU-San Pablo, Madrid, Spain

\* Corresponding author:

E-mail address: [ecastellanos@secardiologia.es](mailto:ecastellanos@secardiologia.es) (E. Castellanos).

Available online 21 February 2015

## REFERENCES

- Hanninen M, Yeung-Lai-Wah N, Massel D, Gula LJ, Skanes AC, Yee R, et al. Cryoablation versus RF ablation for AVNRT: A meta-analysis and systematic review. *J Cardiovasc Electrophysiol.* 2013;24:1354-60.
- Ferrero de Loma-Osorio A, Gil-Ortega I, Pedrote-Martínez A; en representación de los colaboradores del Registro Español de Ablación con Catéter. XIII Informe Oficial de la Sección de Electrofisiología y Arritmias de la Sociedad Española de Cardiología (2013). *Rev Esp Cardiol.* 2014;67:925-35.
- Chan NY, Mok NS, Choy CC, Lau CL, Chu PS, Yuen HC, et al. Treatment of atrioventricular nodal re-entrant tachycardia by cryoablation with an 8-mm-tip catheter versus radiofrequency ablation. *J Interv Card Electrophysiol.* 2012;34:295-301.
- Peyrol M, Sbragia P, Uhry S, Boccarda G, Dolla E, Quatre A, et al. Slow pathway elimination for atrioventricular nodal reentrant tachycardia with the 8-mm tip cryoablation catheter: an 18-month follow-up study. *J Interv Card Electrophysiol.* 2013;37:105-9.

<http://dx.doi.org/10.1016/j.rec.2014.11.011>

## Phospholamban p.Arg14del Mutation in a Spanish Family With Arrhythmogenic Cardiomyopathy: Evidence for a European Founder Mutation



### Mutación p.Arg14del en fosfolambán en una familia española con miocardiopatía arritmogénica: evidencia de una mutación europea fundadora

To the Editor,

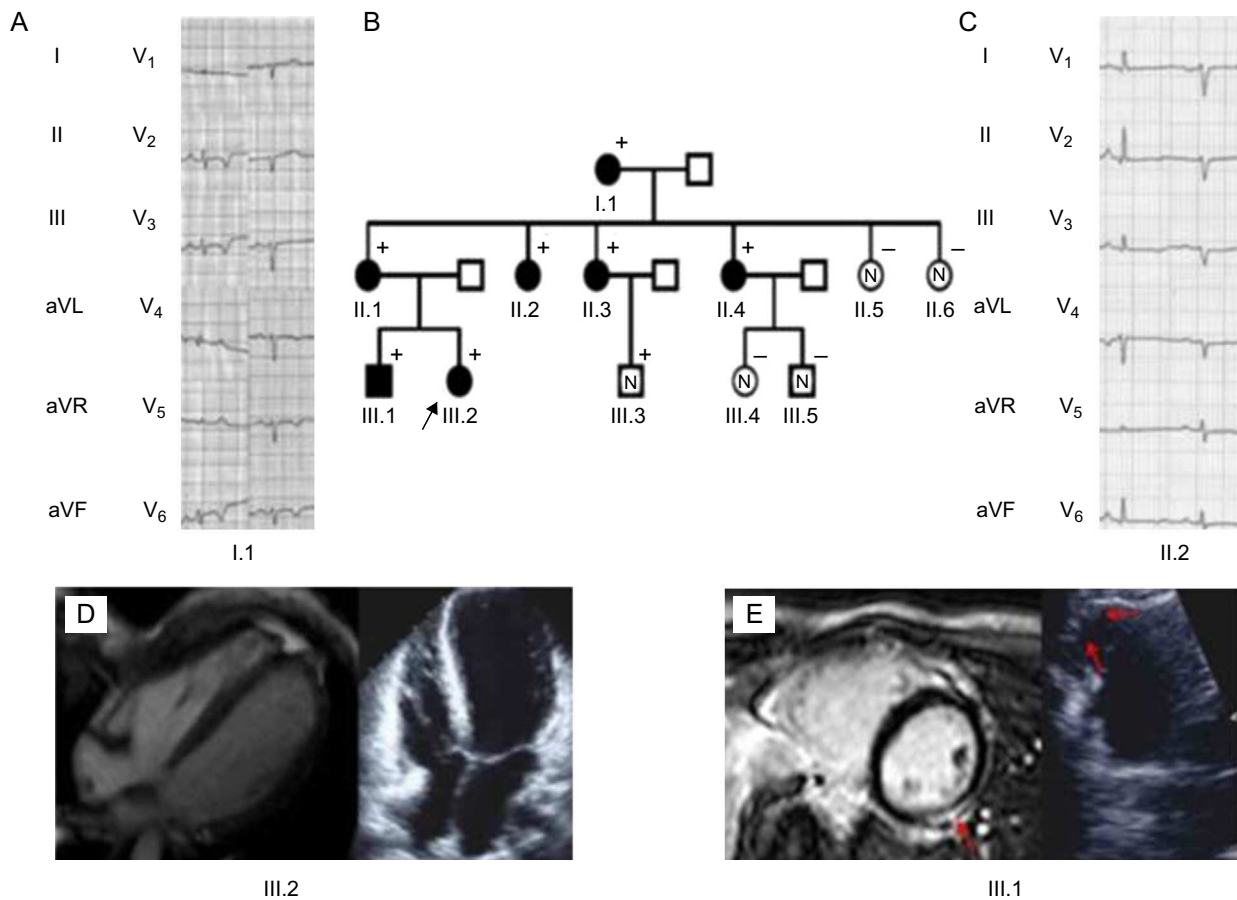
Phospholamban is an inhibitor of the sarcoplasmic calcium pump, which regulates contractility and relaxation. Mutations in its gene, *PLN*, have been associated with aggressive phenotypes of

both dilated cardiomyopathy and arrhythmogenic right ventricular cardiomyopathy.<sup>1,2</sup>

Herein we report a family diagnosed with arrhythmogenic cardiomyopathy with some peculiar features, carrying a Dutch founder mutation in phospholamban (*PLN* c.40\_42delAGA; p.Arg14del).<sup>3</sup> The genotype-phenotype correlation allowed the identification of some red flags, which should lead to suspicion of this mutation in the clinical work-up.

The proband (III.2, Figure 1) was a 28-year-old woman with a past medical history of presyncope. The electrocardiogram (ECG) showed QS inferiorly and striking low voltages throughout all leads (Figure 2).

Echocardiography showed a nondilated left ventricle with global hypokinesia and a left ventricular ejection fraction of 40%.



**Figure 1.** A and C: Electrocardiograph of the carriers: Low voltages and poor R wave progression are the hallmark. Notice the inverted T waves in left precordial leads. B: Family tree. The black arrow points to the proband (III.2). + represent carriers. Filled black figures represent affected carriers. D: The proband's echocardiogram and cardiac magnetic resonance revealed normal biventricular volumes, severe biventricular dysfunction, and absence of late gadolinium enhancement. E: Cardiac imaging and electrocardiographic findings of III.1. Red arrows indicate left ventricle lateral late gadolinium enhancement patch. On the left, a right ventricle aneurysm of the free wall is observed.

Cardiac magnetic resonance with gadolinium did not show late enhancement. The right ventricle was not dilated and had global normal systolic (right ventricular ejection fraction of 51%) function, although the apex was remarkably hypokinetic.

Blood tests were unremarkable. A coronary computed tomography scan showed normal coronaries. The results of 24-hour Holter monitoring were normal. The patient was discharged on beta-blockers, an angiotensin-converting enzyme inhibitor, and spironolactone.

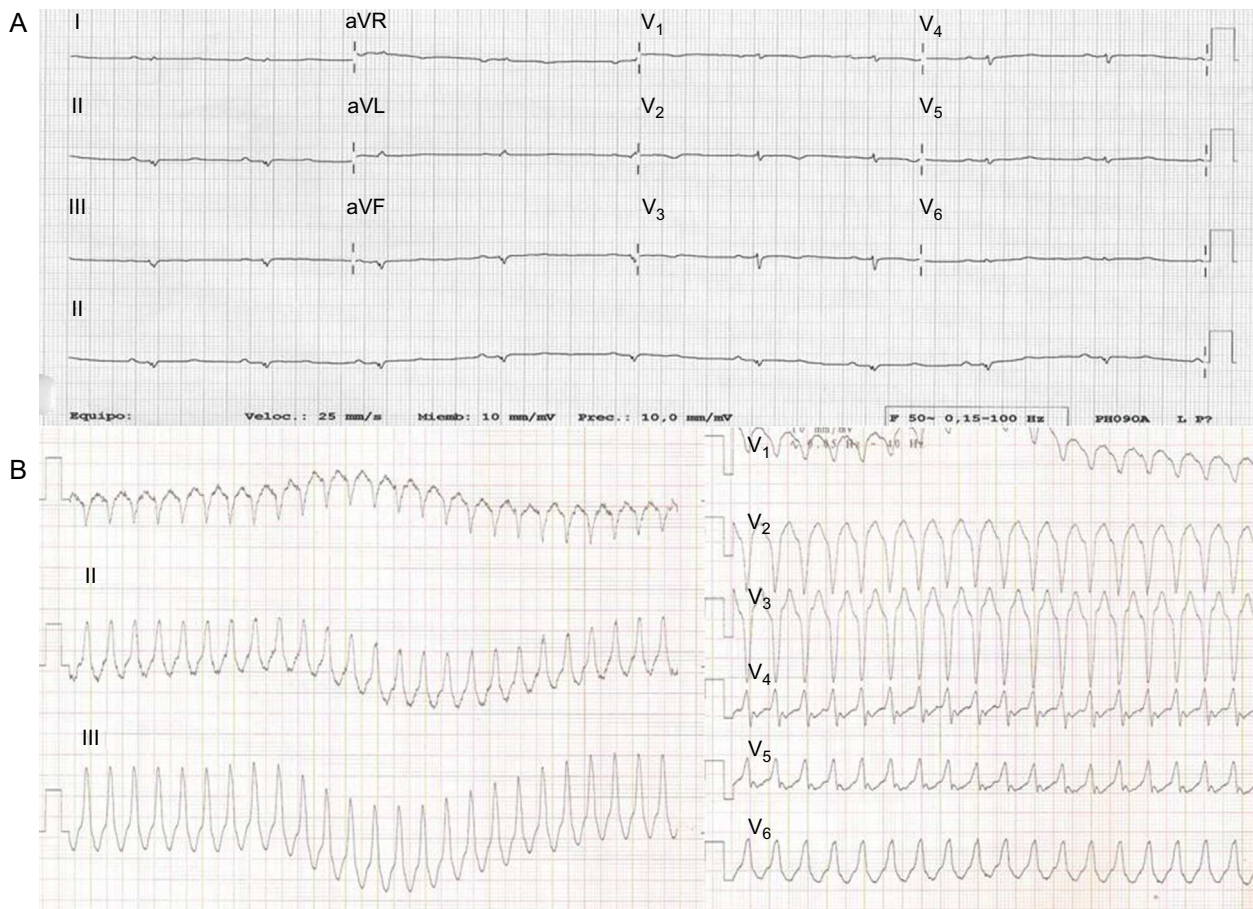She was readmitted for a new collapse 3 months later. During that admission, sustained ventricular tachycardia (Figure 2) was documented, prompting implantation of an implantable cardioverter-defibrillator. The patient remained in New York Heart Association (NYHA) functional class I. Genetic analysis ruled out pathogenic mutations in the 5 desmosomal genes, *LMNA* and *MYBPC3*. However, a pathogenic mutation in *PLN*, p.Arg14del, was identified. There was no other relevant family history of cardiomyopathy or sudden death.

Cascade family screening identified 7 additional carriers of the *PLN* p.Arg14del mutation:

1. An asymptomatic 25-year-old brother (III.1, Figure 1) had frequent (>1000/24 h) ventricular ectopics. His ECG showed late R wave transition in precordial leads. Although the echocardiogram was normal, cardiac magnetic resonance revealed a

hypokinetic right ventricle apex and a subepicardic late gadolinium enhancement patch in the lateral wall of the left ventricle. Biventricular systolic function was normal. Recurrent episodes of symptomatic nonsustained ventricular tachycardia (15-20 beats) were documented. Beta-blockers were started and an implantable cardioverter-defibrillator was implanted.

2. The proband's 52-year-old mother (II.1) was asymptomatic. Her ECG showed late R transition in the precordial leads. The results of echocardiogram and cardiac magnetic resonance were normal.
3. The maternal grandmother (I.1) was incidentally diagnosed at the age of 74 years in a preoperative cardiac evaluation. Her ECG demonstrated negative T waves in inferior and lateral leads. The echocardiogram showed a left ventricular ejection fraction of 45% with normal-sized left ventricular diameters. An exercise echocardiogram was negative for ischemia, and Holter monitoring failed to demonstrate any arrhythmia. She had a good response to medical treatment with left ventricular ejection fraction normalization.
4. Three asymptomatic maternal aunts (II.2, II.3, and II.4) showed poor R wave progression and flat T waves throughout the ECG. The results of echocardiograms and cardiac magnetic resonance were normal.
5. A 16-year-old cousin (III.3) was asymptomatic and the clinical work-up was normal.



**Figure 2.** A: The proband's electrocardiogram. Notice the strikingly low voltages throughout and inverted T waves in right precordial leads. B: Sustained ventricular tachycardia suggestive of a right ventricle outflow tract origin.

Due to the morphology of ventricular tachycardia and ECG abnormalities and their status as carriers, 2 patients met the criteria for definitive arrhythmogenic right ventricular cardiomyopathy whilst 3 had a borderline diagnosis.

Haplotype analyses of markers around *PLN*, in 2 affected Spanish *PLN* mutation carriers, were compared with the Dutch series. Interestingly, the Spanish patients shared 4 out of 5 markers from the shared Dutch haplotype, suggesting a common founder ancestor.

In the family presented herein, the penetrance of the disease is 6/8 (75%). Because *PLN* p.Arg14del is a pathogenic mutation, this family is a clear example of the variability of the clinical phenotype in relatives with arrhythmogenic right ventricular cardiomyopathy.<sup>4</sup> Of note, recent evidence shows a trend for female carriers to show milder phenotypes than males yet they nevertheless show malignant ventricular arrhythmias.<sup>5</sup> A notable finding was the wide variety of ECG abnormalities found in the family: widespread low QRS voltage (even reminiscent of restrictive cardiomyopathy) in the proband, inverted T waves in inferolateral leads (typical of arrhythmogenic left ventricular cardiomyopathy), and poor R wave progression in all but 1 carrier.

Low voltage and poor R wave progression in ECG is a red flag in arrhythmogenic right ventricular cardiomyopathy or dilated cardiomyopathy patients and should lead to suspicion of a *PLN* mutation as a cause of the disease. This is paramount, particularly when assessing the timing of implantable cardioverter-defibrillator implantation, which, in view of the current data, should be

indicated before the patient has severely depressed systolic dysfunction.<sup>5</sup>

José María López-Ayala,<sup>a</sup> Ludolf Boven,<sup>b</sup>  
Arthur van den Wijngaard,<sup>b</sup> Pablo Peñafiel-Verdú,<sup>c</sup>  
Johan Peter van Tintelen,<sup>b,d</sup> and Juan Ramón Gimeno<sup>c,\*</sup>

<sup>a</sup>Sección de Cardiología, Servicio de Medicina Interna, Hospital Universitario Los Arcos del Mar Menor, Murcia, Spain

<sup>b</sup>Department of Genetics, University of Groningen, University Medical Center Groningen, the Netherlands

<sup>c</sup>Servicio de Cardiología, Hospital Clínico Universitario Virgen de la Arrixaca, El Palmar, Murcia, Spain

<sup>d</sup>Department of Clinical Genetics, Academic Medical Center, University of Amsterdam, Amsterdam, the Netherlands

\*Corresponding author:

E-mail address: [jgimeno@secardiologia.es](mailto:jgimeno@secardiologia.es) (J.R. Gimeno).

Available online 17 February 2015

## REFERENCES

- Schmitt JP, Kamisago M, Asahi M, Li GH, Ahmad F, Mende U, et al. Dilated cardiomyopathy and heart failure caused by a mutation in phospholamban. *Science*. 2003;299:1410-3.

2. van der Zwaag PA, van Rijnsing IA, Asimaki A, Jongbloed JD, van Veldhuisen DJ, Wiesfeld AC, et al. Phospholamban R14del mutation in patients diagnosed with dilated cardiomyopathy or arrhythmogenic right ventricular cardiomyopathy: evidence supporting the concept of arrhythmogenic cardiomyopathy. *Eur J Heart Fail.* 2012;14:1199–207.
3. van der Zwaag PA, van Rijnsing IA, de Ruiter R, Nannenberg EA, Groeneweg JA, Post JG, et al. Recurrent and founder mutations in the Netherlands-Phospholamban p.Arg14del mutation causes arrhythmogenic cardiomyopathy. *Neth Heart J.* 2013;21:286–93.
4. Jiménez-Jáimez J, López Moreno E, Barrio López MT, González-Molina M, Álvarez M, Tercedor L. Herencia autosómica recesiva como causa de miocardiopatía arritmogénica biventricular. *Rev Esp Cardiol.* 2014;67:772–4.
5. van Rijnsing IA, van der Zwaag PA, Groeneweg JA, Nannenberg EA, Jongbloed JD, Zwinderman AH, et al. Outcome in Phospholamban r14del carriers: results of a large Multicentre cohort study. *Circ Cardiovasc Genet.* 2014;7:455–65.

<http://dx.doi.org/10.1016/j.rec.2014.11.012>

## Radial Artery Pseudoaneurysm Following Cardiac Catheterization: Clinical Features and Nonsurgical Treatment Results



### Seudoaneurisma de la arteria radial tras cateterización cardiaca: características clínicas y resultados del tratamiento no quirúrgico

#### To the Editor,

The use of radial access for catheterization and cardiac intervention is becoming increasingly popular, mainly because of its lack of complications.<sup>1</sup> Radial artery pseudoaneurysm (RAP)<sup>2</sup> is an extremely rare complication, so many of its clinical features are unknown and treatment is not systematic. In the few reported cases of RAP, surgical repair was the most commonly used treatment,<sup>3</sup> although recently there have been reports of successful nonsurgical treatment in single patients.<sup>4,5</sup> During the period 2004–2013, we prospectively collected all cases of RAP occurring in our center. In this article, we describe their clinical characteristics and outcomes following initial nonsurgical treatment.

During this period, 16 808 catheterizations were performed (96.5% transradial), and 5 radial artery RAP were detected (incidence, 3 of 10 000 catheterizations). The Table shows the

characteristics of the RAP and the treatment applied. All cases presented as a pulsatile erythematous mass at the puncture site (Figure A). One patient (case 5) presented with pulsatile bleeding through an ulceration/erosion of the RAP. In another patient (case 4) we observed crusted erosion of the RAP without spontaneous bleeding (Figure A). All RAP were confirmed by vascular ultrasound (Figure B). The most common factors associated with the occurrence RAP were the use of coumarin anticoagulation during the procedure (4 patients) and the occurrence of hematoma in the forearm during/after compression (4 patients). Nonsurgical treatment was effective in all patients (mechanical compression was successful in 3 and failed in 2; in these patients, thrombin injection was performed, occluding the RAP in both). Direct mechanical compression of the RAP resulted in iatrogenic rupture of the outer wall (Figure C) in 2 patients (cases 2 and 5). In one patient (case 2), thrombin injection produced acute occlusion of the radial artery, which was asymptomatic.

With this series of radial artery RAP, the most extensive published to date, we highlight 3 as yet undescribed features that we consider important for preventing and treating future cases:

1. The presence of a hematoma in the forearm during/after compression (probably due to inadequate compression), along with the presence of predisposing factors (anticoagulation), is a

**Table**  
Clinical Characteristics of the Series

	Case 1	Case 2	Case 3	Case 4	Case 5
Age, y	55	76	79	88	81
Sex	Male	Male	Male	Male	Female
Body surface, m <sup>2</sup>	1.9	1.8	1.9	1.8	1.7
Anticoagulation with coumarin	Yes	Yes	Yes	No	Yes
Anti-GPIIb/IIIa	No	No	No	No	No
Sheath size, Fr	6	6	5	6	6
Diagnosis time, d	15	5	4	17	10
Clinical features apart from pulsatile swelling	No	No	No	Encrusted lesion at the apex	Ulceration with spontaneous bleeding
Interruption of OAC during procedure	No	No	No	Not applicable	No
Prolonged direct mechanical compression (> 12 h)	With pneumatic device	With pneumatic device	With pneumatic device but only 5 h	With pneumatic device	With direction compression with the echo probe
Initial success	No	No	Yes	No	No
Complications	No	Rupture of RAP	No	No	Rupture of RAP
Final treatment	Compression with elastic bandages 48 h	Thrombin injection	Not recorded	Thrombin injection	Compression proximal to the RAP
Interruption of OAC during follow up	Yes	No	Not applicable	Not applicable	Yes
Ultimately successful	Yes	Yes	Yes	Yes	Yes
Complications	None	Asymptomatic radial occlusion	None	None	None

OAC, oral anticoagulants; Anti-GPIIb/IIIa, glycoprotein IIb/IIIa inhibitors; RAP, radial artery pseudoaneurysm.