

Percutaneous Treatment of Early Denergeration of a Sutureless Bioprosthesis



Tratamiento percutáneo de una prótesis aórtica sin sutura degenerada precozmente

To the Editor,

Recent advances in the treatment of patients with severe aortic stenosis have led to greater use of unconventional procedures as an alternative to classic aortic valve replacement.^{1,2} One of these procedures is sutureless prosthesis implantation. These prostheses reduce the aortic cross-clamp and extracorporeal circulation time, and are particularly useful for high-surgical-risk patients and for minimally-invasive approaches.^{3,4}

There is previous experience in the treatment of conventional bioprosthesis dysfunction using valve-in-valve percutaneous procedures,⁵ but such experience is rare in the treatment of sutureless bioprosthesis dysfunction.

We report the case of a 79-year-old woman with hypertension and dyslipidemia, who underwent valve replacement in 2011 due to severe degenerative aortic stenosis by using a Perceval size S sutureless prosthesis (Sorin Group; Saluggia, Italy) with an aortic cross-clamp time of 23 minutes and extracorporeal circulation time of 45 minutes. This is a self-expandable bovine pericardial prosthesis fixed in a Nitinol frame without the need for sutures, leaving the leaflets in the annular position and the fixation structure in the supra-annular position. The outcome was good, with no periprosthetic regurgitation and with a maximum transvalvular gradient of 23 mmHg, no perioperative complications, and an excellent clinical course. At discharge, the valve area was 1.6 cm², and the indexed valve area was 1 cm²/m².

The patient remained asymptomatic during the follow-up period, but developed permanent atrial fibrillation in 2015 and

consequently began oral anticoagulation with acenocoumarol. The patient reported the gradual onset of dyspnea from early 2016. A transthoracic echocardiogram revealed thickened, calcified leaflets, with restricted opening leading to severe aortic stenosis (peak gradient [PG], 99 mmHg; mean gradient [MG], 49 mmHg), with a valve area of < 0.5 cm² (Figure A, Video 1 of the supplementary material). The patient had an international normalized ratio (INR) of 2 to 3 in all determinations over the last 6 months. Given evidence of valve degeneration on ultrasound and adequate anticoagulation, the case was assessed by the local multidisciplinary team, composed of a clinical cardiologist, an interventional cardiologist, a cardiac surgeon, and a geriatrician. The patient was considered to be at high risk for conventional surgery, given her frailty (logistic EuroSCORE, 18%; Society of Thoracic Surgeons score, 4.335%). Despite the presence of a small prosthesis, it was decided to perform a percutaneous procedure, given that the prosthetic valve was sutureless.

The preliminary study was completed with computed tomography (Figure B) and a transesophageal echocardiogram to assess the optimal arterial access and the effective annular size. In accordance with the manufacturer's specifications and with the help of the ViV Aortic app 2.0 (UBQO Limited), a true internal lumen of 17.5–19 mm was established, which is compatible (among others) with a 23-mm SAPIEN 3 prosthesis (Edwards Lifesciences, Inc; Irvine, California, United States).

The implantation was carried out with conscious sedation and transthoracic echocardiogram monitoring. The Heart Navigator system was used as a reference to determine the optimal projection and confirm the size of the selected prosthesis (Figure C). Via right femoral access with surgical exposure, with a 14-Fr sheath, the e-sheath device was advanced over an extrastiff guidewire, according to a previously described procedure.⁶ In the alignment process, the radio-opaque marker of the SAPIEN 3

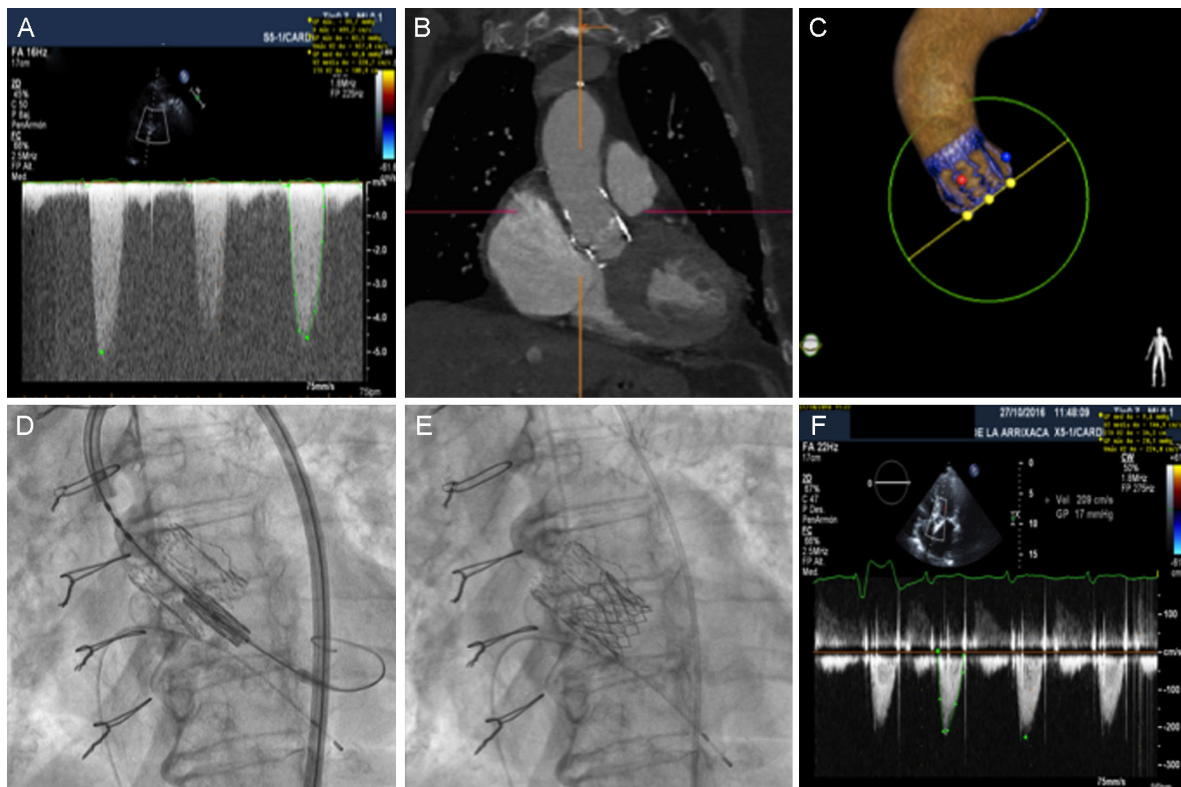


Figure. A: transvalvular gradient of the degenerated prosthesis. B: computed tomography image of the Perceval prosthesis. C: Heart Navigator image for planning the procedure. D: alignment of the SAPIEN 3 prosthesis during the valve-in-valve procedure. E: angiographic result, which revealed a position slightly below the edge of the Perceval prosthesis. F: optimal transvalvular gradient at discharge, after implantation.

prosthesis was aligned with the lower edge of the Perceval prosthesis (Figure D). Once aligned, the prosthesis was implanted without predilation, with rapid ventricular stimulation. The hemodynamic outcome was optimal (Figure E), with a resulting maximum gradient of 20 mmHg and a mean gradient of 10 mmHg, with no significant regurgitation (Figure F, Video 2 of the supplementary material). Angiography showed that the prosthesis remained in a position slightly below the lower edge of the Perceval prosthesis. After implantation, the patient experienced complete atrioventricular block. A provisional pacemaker was implanted with implantation of a definitive VVIR device after 48 hours. The patient progressed favorably and was discharged 5 days after implantation. Two months later, she remained asymptomatic.

This case is an example of the new reality in terms of aortic valve treatment and the emergence of new procedures. Multidisciplinary care in these cases allows us to provide patients with an enhanced level of safety. This is one of the few published cases that demonstrates the safety of transfemoral aortic prosthesis valve-in-valve implantation over a previous sutureless prosthesis.

SUPPLEMENTARY MATERIAL



Supplementary material associated with this article can be found in the online version available at doi:10.1016/j.rec.2017.05.023.

Juan García-Lara,^{a,*} Julio García-Puente,^b Alicia Mateo-Martínez,^c Eduardo Pinar-Bermúdez,^a Francisco Gutiérrez-García,^b and Mariano Valdés-Chávarri^a

^aServicio de Cardiología, Hospital Universitario Virgen de la Arrixaca, El Palmar, Murcia, Spain

^bServicio de Cirugía Cardiovascular, Hospital Universitario Virgen de la Arrixaca, El Palmar, Murcia, Spain

^cSección de Cardiología, Hospital Comarcal del Noroeste, Caravaca de la Cruz, Murcia, Spain

* Corresponding author:

E-mail address: jgarciadelara@gmail.com (J. García-Lara).

Available online 17 June 2017

REFERENCES

- Salinas P, Moreno R, Calvo L, et al. Seguimiento a largo plazo tras implante percutáneo de válvula aórtica por estenosis aórtica grave. *Rev Esp Cardiol.* 2016;69:37–44.
- Morís C, Pascual I, Avanzas P. ¿Será el TAVI el tratamiento de elección para la estenosis aórtica? *Rev Esp Cardiol.* 2016;69:1131–1134.
- Forcillo J, Bouchard D, Nguyen A, et al. Perioperative outcomes with sutureless versus stented biological aortic valves in elderly persons. *J Thorac Cardiovasc Surg.* 2016;151:1629–1636.
- Pollari F, Santarpino G, Dell'Aquila AM, et al. Better short-term outcome by using sutureless valves: a propensity-matched score analysis. *Ann Thorac Surg.* 2014;98:611–616.
- Eggebrecht H, Schäfer U, Treede H, et al. Valve-in-valve transcatheter aortic valve implantation for degenerated bioprosthetic heart valves. *JACC Cardiovasc Interv.* 2011;4:1218–1227.
- Binder RK, Rodés-Cabau J, Wood DA, et al. Transcatheter aortic valve replacement with the SAPIEN 3: a new balloon-expandable transcatheter heart valve. *JACC Cardiovasc Interv.* 2013;6:293–300.

<http://dx.doi.org/10.1016/j.rec.2017.05.023>

1885-5857/

© 2017 Sociedad Española de Cardiología. Published by Elsevier España, S.L.U. All rights reserved.

Vascular Age, RR, ALLY, RALLY and Vascular Speed, Based on SCORE: Relations Between New Concepts of Cardiovascular Prevention



Edad vascular, RR, ALLY, RALLY y velocidad de envejecimiento, basados en el SCORE: relaciones entre nuevos conceptos de prevención cardiovascular

To the Editor,

When treating patients with cardiovascular risk factors, their quantification can help tailor treatment goals and intensity to individual circumstances.¹ The most widely used system for quantifying cardiovascular risk factors in Europe is the SCORE system, which is recognized by the 2016 European Guidelines on cardiovascular prevention and the 2016 European guidelines for the management of dyslipidaemias.² These guidelines concur on the value of calculating relative risk (RR) and vascular age (VA), particularly in young patients. Clinicians can now consult specific VA charts derived from the SCORE charts³ or a single, sex-specific, cardiovascular disease relative risk (RR) chart that is valid for patients of any age.^{1,2} The relationship between RR and VA or any other VA-derived indicators, however, has not been studied.

Avoidable lost life years (ALLY) are defined as the difference between chronological age (CA) and VA (ALLY = VA - CA). As ALLY vary according to CA, a second concept, RALLY (ratio of avoidable lost life years), can be used to measure the ratio between ALLY and CA (RALLY = ALLY/CA).

Vascular aging, or vascular speed (VS), in turn, refers to the relationship between VA and CA (VS = VA/CA). It is expressed as a percentage. Based on the above definitions, VS is clearly

related to RALLY. If ALLY = VA - CA and RALLY = ALLY/CA, then RALLY = (VA - CA)/CA. In other words, RALLY = (VA/CA - CA/CA) = VS - 1 and VS = 1 + RALLY.

This study had 2 objectives. The first was to determine whether a given RR would correspond to the same proportional number of ALLY at any age (remember that a single chart covers all ages for RR). In other words, we wanted to investigate whether there was an association between RR and RALLY. As RR is a risk ratio, we checked if there was a linear correlation between the logarithm of RR (LnRR) and RALLY. The second objective, assuming RR and RALLY were associated and knowing that VS is related to RALLY (VS = 1 + RALLY), was to create a single VS chart valid for all ages, similar to the RR chart. To do this, we performed multiple linear regression to investigate the association between VS and the

Table 1

Association Between Relative Risk (RR) and Ratio of Available Lost Life Years (RALLY) in Women and Men

	Women	Men
RR	RALLY	RALLY
1	0	0
1.5	0.06	0.09
2	0.11	0.16
2.5	0.15	0.21
3	0.17	0.25
3.5	0.20	0.29
4	0.22	0.32
4.5	0.24	0.35
5	0.25	0.37