

## Image in cardiology

## Percutaneous treatment of a surgical complication of sinus venosus atrial septal defect



## Tratamiento percutáneo en complicación quirúrgica de comunicación interauricular tipo seno venoso

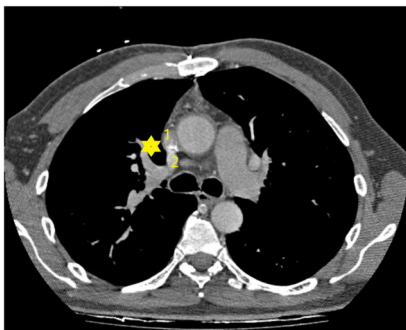
Javier Jimeno Sánchez,<sup>a,\*</sup> Marta López Ramón,<sup>a</sup> and Ángel Sánchez-Recalde<sup>b</sup><sup>a</sup> Servicio de Cardiología, Hospital Universitario Miguel Servet, Zaragoza, Spain<sup>b</sup> Servicio de Cardiología, Hospital Universitario Ramón y Cajal, Madrid, Spain

Figure 1.

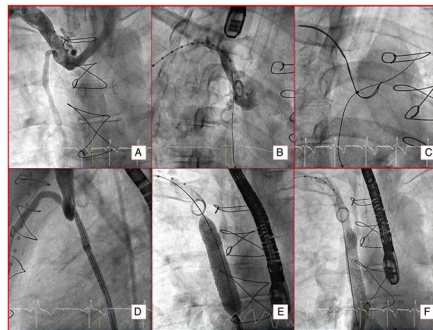


Figure 2.

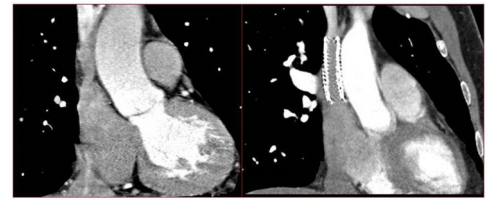


Figure 3.

A 49-year-old man with a history of sinus venosus atrial septal defect with partial anomalous pulmonary venous return—right superior pulmonary vein (RSPV) and middle lobe pulmonary vein draining to superior vena cava (SVC)—underwent surgical correction with a bovine pericardium patch, redirecting the RSPV and middle lobe pulmonary vein to the left atrium, with SVC enlargement.

Two years later, the patient was admitted due to transient ischemic attack. Echocardiography showed abundant bubble passage to the left chambers (with no bubbles previously in the right chambers). Computed tomography of the heart revealed SVC stenosis and a 4-mm defect (figure 1) between the SVC (1) and RSPV (2); dehiscence of the suture patch was then diagnosed (asterisk). Following assessment in a medical-surgical session, the patient underwent a percutaneous procedure that showed (figure 2) complete occlusion of the entire SVC from the right atrium to the distal end of the brachiocephalic veins (A); guidewire crossing of chronic occlusion via right femoral venous access (B); snare retrieval of the guidewire through the antecubital vein (C); advance of the delivery sheath, crossing the occlusion (D); implantation of Begraft 14/59-mm stent (Bentley; Germany) (E), and final angiographic outcome (F).

To date, the patient remains asymptomatic. Tomography (figure 3) shows stenosis in the SVC leading to the right atrium (left), treated by stent implantation (right).

In conclusion, residual shunt should be ruled out in the event of stroke in a patient with a repaired atrial septal defect. Percutaneous intervention, as performed in our patient, may be a valid option that is equally effective for the treatment of SVC obstruction and residual shunt by coated stent.

## CONFLICTS OF INTEREST

Á. Sánchez-Recalde is associate editor of *Revista Española de Cardiología*; the editorial procedure established by the journal has been followed to ensure impartial management of the manuscript.

\* Corresponding author:

E-mail address: javierjimeno1@gmail.com (J. Jimeno Sánchez).