

## Brief report

Percutaneous Treatment of a Dysfunctional Aortic Bioprosthesis With the CoreValve<sup>®</sup> Prosthesis

José M. Hernández-García,<sup>a</sup> Antonio J. Muñoz-García,<sup>a,\*</sup> Juan H. Alonso-Briales,<sup>a</sup> Manuel F. Jiménez-Navarro,<sup>a</sup> Antonio J. Domínguez-Franco,<sup>a</sup> Isabel Rodríguez-Bailón,<sup>a</sup> Eduardo Olalla-Mercadé,<sup>b</sup> and Eduardo de Teresa-Galván<sup>a</sup>

<sup>a</sup>Servicio de Cardiología, Hospital Universitario Virgen de la Victoria, Málaga, Spain

<sup>b</sup>Servicio de Cirugía Cardíaca, Hospital Universitario Virgen de la Victoria, Málaga, Spain

## ARTICLE INFO

## Article history:

Received 27 January 2010

Accepted 9 March 2010

Available online 17 December 2010

## Keywords:

Valve prosthesis

Cardiac catheterization

## Palabras clave:

Prótesis valvular

Cateterismo cardíaco

## ABSTRACT

Recently, percutaneous aortic valve replacement has emerged as a therapeutic option for patients with severe symptomatic aortic stenosis and a high surgical risk. We report our initial experience in four patients with percutaneous implantation of a CoreValve aortic prosthesis to treat aortic bioprosthesis dysfunction involving aortic stenosis or regurgitation. In-hospital and medium-term outcomes were analyzed. The procedure was performed under local anesthesia and guided by angiography. The prosthesis was implanted successfully in all patients, although a second prosthesis was required in one case because the first was positioned too high. There were no major complications. After a mean follow-up of 7 months (SD, 4.7), all patients remained asymptomatic.

© 2010 Sociedad Española de Cardiología. Published by Elsevier España, S.L. All rights reserved.

### Tratamiento percutáneo de las bioprótesis aórticas disfuncionantes con la prótesis CoreValve<sup>®</sup>

## RESUMEN

El implante valvular aórtico percutáneo ha surgido recientemente como alternativa terapéutica para pacientes con estenosis aórtica severa sintomática y alto riesgo quirúrgico. Se presenta la experiencia inicial en el tratamiento de la disfunción de la bioprótesis aórtica mediante el implante percutáneo de prótesis aórtica CoreValve en 4 pacientes, tanto con estenosis como con insuficiencia aórtica, y se analiza los resultados hospitalarios y a medio plazo. El procedimiento se realizó con anestesia local y guiado por angiografía. Se implantaron con éxito en todos los casos, si bien uno precisó una segunda prótesis por posicionamiento alto de la primera. No hubo complicaciones mayores. Tras un seguimiento medio de  $7 \pm 4,7$  meses, todos los pacientes se encuentran asintomáticos.

© 2010 Sociedad Española de Cardiología. Publicado por Elsevier España, S.L. Todos los derechos reservados.

## INTRODUCTION

The worldwide incidence of aortic valve stenosis has been increasing exponentially as life expectancy rises.<sup>1,2</sup> Aortic valve replacement is the standard treatment, and biological prostheses have been the treatment of choice for patients of advanced age or with comorbidities.<sup>3</sup> These cardiac biological prostheses have a short life-span, which may be further shortened by various degenerative processes,<sup>4</sup> and repeat procedures involve considerable risk to this patient group.<sup>5</sup>

Percutaneous aortic valve replacement is an alternative for the treatment of severe symptomatic aortic valve stenosis at high surgical risk.<sup>6–10</sup> Patients with aortic bioprosthesis dysfunction can be considered a subgroup at high risk. We present our initial experience in treating aortic bioprosthesis dysfunction (due to stenosis or regurgitation) by percutaneous implantation of the CoreValve aortic valve prosthesis.

\* Corresponding author: Servicio de Cardiología, Hospital Universitario Virgen de la Victoria, Campus de Teatinos, s/n, 29010 Málaga, Spain.

E-mail address: ajmunozgarcia@secardiologia.es (A.J. Muñoz-García).

## METHODS

In 2008 an assessment and percutaneous CoreValve aortic prosthesis implantation program was put into practice for high-risk surgical or elderly (>80 years) patients who refused valve replacement surgery. Patients were selected in accordance with the recommendations of the various scientific societies<sup>11</sup> and the anatomic criteria required for percutaneous implantation.<sup>6</sup>

Between April 2008 and November 2009, 69 patients were consecutively treated with the CoreValve percutaneous aortic prosthesis due to severe symptomatic aortic valve disease at high surgical risk. Aortic bioprosthesis dysfunction was present in 4 patients: 2 with severe aortic regurgitation and 2 with aortic stenosis.

All patients were clinically assessed, and surgical risk was estimated by the logistic EuroSCORE. In addition, all patients underwent echocardiography, coronary angiography, aortography of the aortic root, and angiography of the iliofemoral axis.

The large CoreValve prosthesis was selected for a surgical bioprosthesis with a diameter of 23 mm or larger and the small prosthesis for a diameter smaller than 23 mm.

## Description of the Device and Procedure

The CoreValve aortic prosthesis is a biological prosthetic trileaflet valve of porcine pericardium, fitted and sutured onto a self-expanding nitinol structure. There are 2 valve sizes: small (26 mm in the portion inserted into the native annulus) and large (29 mm). The length of the prosthesis is 50 mm.

## Procedure

The procedures were performed under local anesthesia with superficial sedation. In all 4 patients, access was through the femoral artery using a 18 French introducer and the femoral puncture was closed with the Prostar XL<sup>®</sup> percutaneous device. The aortic prosthesis was expanded under angiographic control. In the case of bioprosthesis dysfunction with aortic regurgitation, valvuloplasty was not performed before the prosthesis was implanted. No difficulties were experienced while advancing the CoreValve prosthesis through the surgical bioprosthesis. Echocardiographic follow-up was performed at 72 h.

The procedure was considered successful if the normal functioning prosthesis was correctly implanted and there was no in-hospital mortality.

## RESULTS

The mean age of the patients with bioprosthesis dysfunction was 77.2 (SD, 13.5; range, 60–89) years; the mean logistic EuroSCORE was 33.7% (SD, 24.6%; range, 7.14%–63.9%). Table 1 summarizes the baseline characteristics. The 2 patients with prosthetic dysfunction caused by severe stenosis had a Carpentier-Edwards bioprosthesis (19 and 27 mm, respectively). In the patients with aortic regurgitation, the aortic bioprosthesis was frameless and with radiolucent ring: 23-mm Intact (Medtronic) and 21-mm Mosaic (Medtronic).

The CoreValve aortic prosthesis was successfully implanted in all 4 patients. Small prostheses were used in 2 patients and large prostheses in 2. The mean procedure time was 117 (11.5) min and the mean aortic prosthesis expansion time, 7.7 (2.8) min.

CoreValve aortic prosthesis expansion was easier in patients with a radio-opaque ring because the bioprosthesis ring was visualized under radioscopia (Fig. 1), unlike the frameless bioprosthesis (Fig. 2). Following implantation of the CoreValve aortic prosthesis, hemodynamic improvement was obtained and the aortic gradient disappeared. One patient required a second

prosthesis during the same procedure because the first one remained in the supra-annular position, leading to severe aortic regurgitation (Fig. 3). Postprocedure aortic regurgitation grade was trivial in 2 patients and mild in the other 2. There were no cardiovascular or cerebrovascular complications.

The maximum echocardiographic aortic gradient decreased from 66.7 (25.7) mmHg to 24 (7.4) mmHg and the mean, from 44 (22.7) mmHg to 14.7 (5.6) mmHg.

One patient required a pacemaker 4 days after the procedure due to paroxysmal atrioventricular block on the third day.

The in-hospital stay was 5.2 days (SD, 0.9; range, 4–6). By the time of discharge, NT-proBNP had dropped from 5308 to 3418 pg/ml and the patients presented clinical improvement (from New York Heart Association functional class IV to I–II).

After a mean follow-up of 7 months (SD, 4.7; range, 4–14), all patients remained asymptomatic.

## DISCUSSION

Percutaneous implantation of the CoreValve aortic prosthesis represents a new option for the treatment of severe aortic stenosis in patients at high surgical risk.<sup>6–10</sup> Once the initial learning curve was overcome and excellent periprocedure and medium-term outcomes were observed, however, the use of the bioprosthesis has been extended to other indications not originally considered. One is aortic bioprosthesis dysfunction (usually due to aortic regurgitation) in keeping with the concept of one valve over another.<sup>12</sup>

Cardiac biological prostheses have a short mean life despite huge improvements made in the newer generations of prosthesis. In fact, at 15 years the percentage of patients with no aortic valve replacement was 58% in the case of first-generation Carpentier-Edwards prostheses (implanted in the late 1970s)<sup>4</sup> and 83% in the case of second-generation prostheses (implanted in the 1980s and 1990s).<sup>13</sup> Repeat procedures pose a very high risk to these patients because most are in their 80s. In the series described by Langenay et al.,<sup>14</sup> which analyzed aortic valve surgery in octogenarians, the main predictor of mortality was reoperation. Therefore, a therapeutic approach that entails less risk may offer unquestionable advantages to more patients.

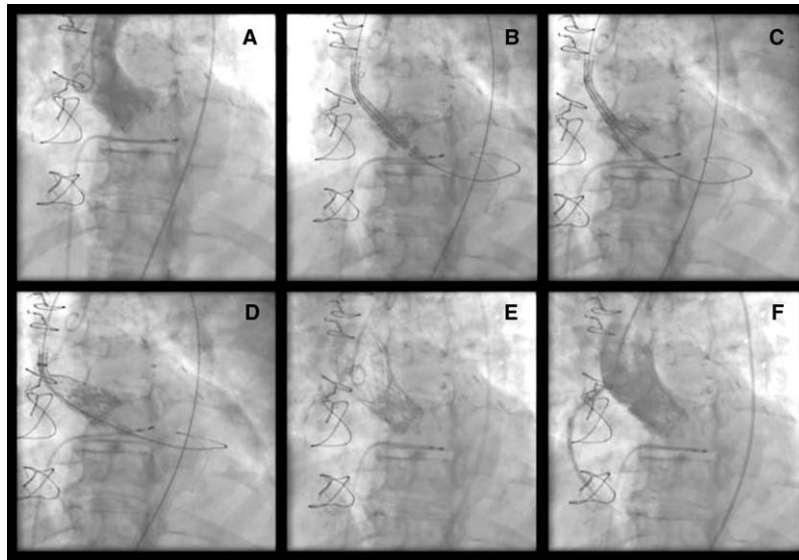
Another important issue is the age at implantation of a bioprosthesis versus mechanical prosthesis, as the controversy concerns the risk of reoperation compared to the risk of long-term anticoagulation. In a recent study, event-free survival would be higher after age 60 years in the case of the bioprosthesis.<sup>15</sup> In the future, percutaneous implantation may be offered to high-risk patients instead of reoperation and, therefore, the use of

**Table 1**  
Baseline Characteristics of Patients with Degenerated Bioprosthesis<sup>\*</sup>

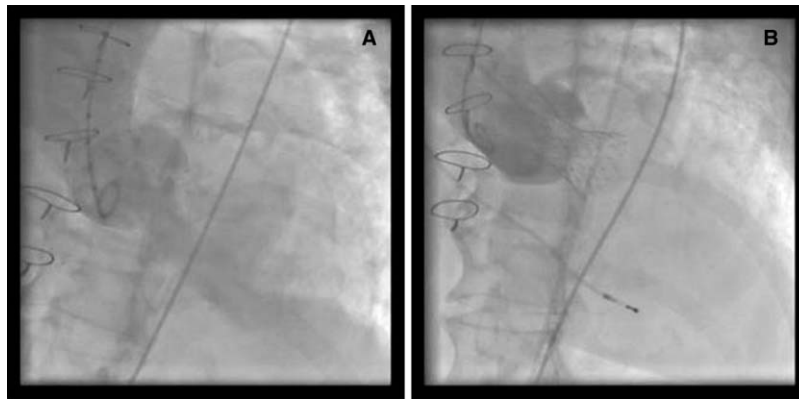
	1	2	3	4
Age, years	60	87	73	89
Sex	Male	Female	Female	Female
Logistic EuroSCORE, %	7.14	41.92	22.1	63.9
Coronary disease	Yes	Yes	Yes	Yes
Dyspnea, NYHA functional class	IV	IV	IV	IV
Ejection fraction, %	66	68	57	75
Bioprosthesis	27-mm C-E	19-mm C-E	23-mm intact	21-mm mosaic
Degree of calcification	Mild	Moderate	Moderate	Mild
Duration of bioprosthesis, y	3	11	14	9
Dysfunction	Stenosis	Stenosis	Regurgitation	Regurgitation
Comorbidity			Rheumatoid arthritis	

Abbreviations: C-E, Carpentier-Edwards; NYHA, New York Heart Association.

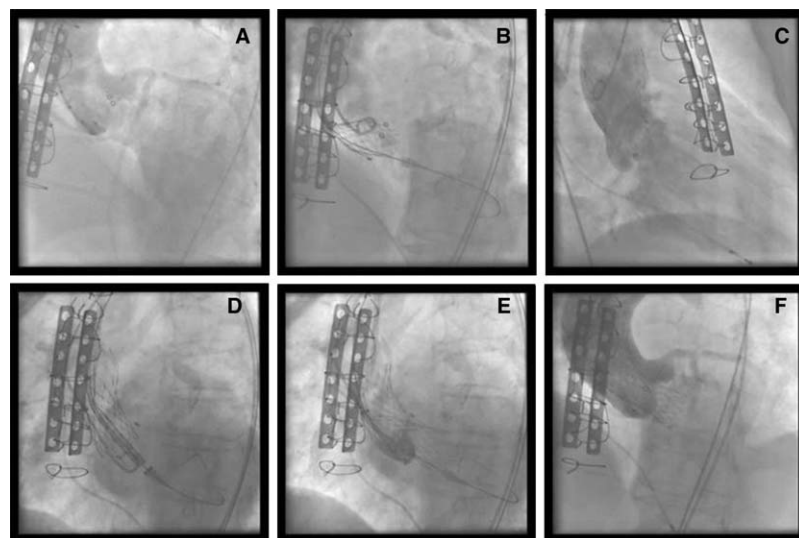
<sup>\*</sup> Patient 1 presented as comorbidity a cirrhosis of the liver complicated with portal hypertension. Patient 3 presented as comorbidity a rheumatoid arthritis with chest deformation.



**Figure 1.** (A) Carpentier-Edwards bioprosthesis dysfunction due to severe stenosis. (B-D) Different time points during CoreValve prosthesis expansion. (E-F) Angiographic outcome after implantation.



**Figure 2.** Dysfunctional frameless aortic bioprosthesis. (A) Severe aortic regurgitation. (B) Angiographic outcome after implantation.



**Figure 3.** Degenerated biological prosthesis. (A) Severe aortic regurgitation. (B) Prosthesis expansion. (C) Severe aortic regurgitation after high implantation of the prosthesis. (D-E) Implantation of second CoreValve prosthesis. (F) Angiographic outcome.

mechanical prostheses plus anticoagulation therapy would be reserved for younger patients.

Because a percutaneous prosthesis would be implanted in these cases, a lower incidence of adverse phenomena (paravalvular leaks or cerebral strokes) could be expected, compared to the treatment of a calcified native aortic valve. We had no such complications in our patients; however, larger studies are needed to confirm this observation.

In conclusion, the outcomes obtained with percutaneous implantation of the CoreValve aortic prosthesis indicate that the treatment is feasible and achieves hemodynamic and clinical improvement in patients with aortic bioprosthesis dysfunction.

## CONFLICTS OF INTEREST

The authors state that they have no conflicts of interest.

## REFERENCES

- Iung B, Baron G, Butchart EG, Delahaye F, Gohlke-Bärwolf C, Levang OW, et al. A prospective survey of patients with valvular heart disease in Europe: The Euro Heart Survey on Valvular Heart Disease. *Eur Heart J*. 2003;24:1231-43.
- NKomo VT, Gardin JM, Skelton TN, Gottdiener JS, Scott CG, Enríquez-Sarano M. Burden of valvular heart diseases: a population based study. *Lancet*. 2006;368:1005-11.
- Cohn LH. Use of heart valves in older patients. *Circulation*. 2005;111:2152-3.
- Jamieson WR, Munro I, Miyagishima RT, Allen P, Burr LH, Tyers FO. Carpentier-Edwards standar porcine bioprosthesis: Clinical performance to seventeen years. *Ann Thorac Surg*. 1995;60:999-1007.
- Pansini S, Ottino G, Forsennati PG, Serpieri G, Zattera G, Casabona R, et al. Reoperations on heart valve protheses: an analysis of operative risks and late results. *Ann Thorac Surg*. 1990;50:590-6.
- Grube E, Buellesfeld L, Mueller R, Sauren B, Zickmann B, Nair D, et al. Progress and current status of percutaneous aortic valve replacement: results of three device generations of the CoreValve revalving system. *Circ Cardiovasc Intervent*. 2008;1:167-75.
- Webb JG, Altwegg L, Boone RH, Cheung A, Ye J, Lichenstein S, et al. Transcatheter aortic valve implantation. Impact on clinical and valve related outcomes. *Circulation*. 2009;119:3009-16.
- Avanzas P, Muñoz-García AJ, Segura J, Pan M, Alonso-Briales JH, Lozano I, et al. Implante percutáneo de la prótesis valvular aórtica autoexpandible CoreValve en pacientes con estenosis aórtica severa: experiencia inicial en España. *Rev Esp Cardiol*. 2010;63:141-8.
- García E, Pinto AG, Sarnago Cebada F, Pello AM, Paz M, García-Hernández MA, et al. Implantación percutánea de prótesis valvular aórtica: experiencia inicial en España. *Rev Esp Cardiol*. 2008;61:1210-4.
- Moreno R, Calvo L, Figueiras D, López T, Sánchez-Recalde A, Jiménez-Valero S, et al. Implantación de prótesis valvulares en pacientes con estenosis aórtica severa sintomática rechazados para cirugía de sustitución valvular. *Rev Esp Cardiol*. 2008;61:1215-9.
- Vahanian A, Alfieri O, Al-Attar N, Antunes M, Bax J, Cormier B, et al. Transcatheter valve implantation for patients with aortic stenosis: a position statement from the European Association of Cardio-Thoracic Surgery (EACTS) and the European Society of Cardiology (ESC) in collaboration with the European Association of Percutaneous Cardiovascular Interventions (EAPCI). *Eur Heart J*. 2008;29:1463-70.
- Wenaweser P, Buellesfeld L, Gerckens U, Grube E. Percutaneous aortic valve replacement for severe aortic regurgitation in degenerated bioprosthesis: the first valve in valve procedure using the CoreValve revalving system. *Catheter Cardiovasc Interv*. 2007;70:760-4.
- Jamieson WR, Janusz MT, Burr LH, Ling H, Miyagishima RT, Germann E, Carpentier Edwards supraannular porcine bioprosthesis: second generation prosthesis in aortic valve replacement. *Ann Thorac Surg*. 2001;71 Suppl: S224-7.
- Langanay T, Verhoye JP, Ocampo G, Vola M, Tauran A, De La Tour B, et al. Current hospital mortality of aortic valve replacement in octogenarians. *J Heart Valve Dis*. 2006;15:630-7.
- Van Geldorp MW, Jamieson WR, Kappetein AP, Ye J, Fradet GJ, Eijkemans MJ, et al. Patients outcome after aortic valve replacement with a mechanical or biological prosthesis: weighing lifetime anticoagulant-related event risk against reoperation risk. *J Thorac Cardiovasc Surg*. 2009;137:881-6.