

Percutaneous Transluminal Angioplasty in Patients with Subclavian Stenosis and Internal Mammary Grafts

Alberto Berenguer Jofresa, Francisco Marín Ortuño, Francisco de España^a, Juan Miguel Ruiz Nodar, Clara Oliver Navarrete and Vicente Mainar Tello

Servicios de Cardiología y ^aRadiología. Hospital General de Alicante. España.

Subclavian artery stenosis is an uncommon cause of myocardial ischaemia in patients with internal mammary artery grafts. Coronary subclavian steal and impaired flow through the graft are the two mechanisms implied. We report 2 patients with mammary artery grafts in whom reappraisal of anginal symptoms was related to the presence of proximal subclavian stenoses located just before the origin of the mammary artery grafts. Both patients were successfully treated by percutaneous angioplasty and stent implantation.

Key words: *Peripheral vascular disease. Coronary bypass. Revascularization. Stent.*

Full English text available at: www.revespcardiol.org

Angioplastia transluminal percutánea en pacientes con estenosis de la arteria subclavia e injertos de arteria mamaria

Una causa infrecuente de isquemia coronaria tras revascularización con injertos de arteria mamaria es la presencia de estenosis en la porción proximal de la subclavia, que puede condicionar un fenómeno de robo coronario o bien limitar el flujo por el injerto. Presentamos los casos de 2 pacientes con injertos de arteria mamaria en los que la reaparición de la sintomatología anginosa se relacionó con la presencia de sendas estenosis de la porción proximal de la arteria subclavia, justo antes de la salida de los injertos de arteria mamaria. Estos pacientes fueron tratados satisfactoriamente mediante angioplastia percutánea e implantación de *stents*.

Palabras clave: *Enfermedad vascular periférica. Injerto coronario. Revascularización. Stent.*

INTRODUCTION

The use of the internal mammary artery (IMA) is highly recommended for coronary revascularization surgery.¹⁻⁴ Coronary steal syndromes is an unusual complication in patients with IMA grafts. One of the better known causes of this syndrome in subjects with IMA grafts is the presence of stenosis in the proximal portion of the subclavian artery. This syndrome, called coronary-subclavian steal by Tyras and Barner,⁵ is characterized by the presence of stenosis in the proximal portion of the subclavian artery and the inversion of flow in the graft, which causes conditions

favorable for the appearance of symptoms of myocardial ischemia. The treatment of this syndrome has been based on surgical correction of the stenosis,^{4,6,7} but recently nonsurgical methods have been suggested based on percutaneous dilatation of the stenosis with good results and few complications.⁸⁻¹¹

CLINICAL CASES

Case 1

The patient was a 52-year-old man with a history of arterial hypertension, hypercholesterolemia, beta lactamic allergy, and ischemic cardiopathy with previous angioplasty of the anterior descending artery (DA). In a previous admission for an episode of unstable angina re-stenosis was noted in the median DA, as well as progression of coronary heart disease with occlusion of the proximal right coronary artery (RC). It was decided to perform surgical revascularization by means of a double aortocoronary

Correspondence: Dr. A. Berenguer Jofresa.
Sección de Hemodinámica y Cardiología Intervencionista.
Hospital General de Alicante.
Avda. Maestro Alonso, 109. 03010 Alicante. España.
Correo electrónico: berenguer_alb@gva.es

Recibido el 18 de junio de 2001.
Aceptado para su publicación el 11 de septiembre de 2001.

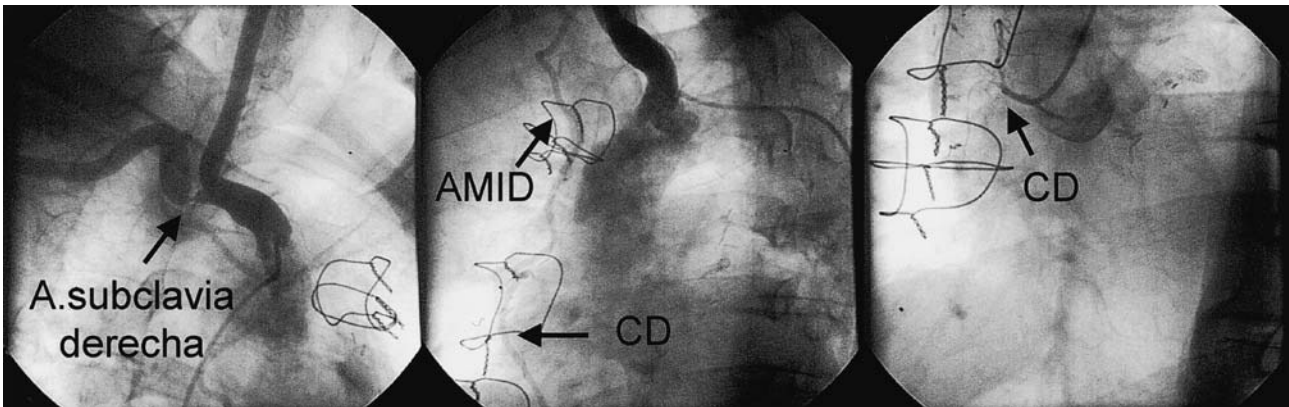


Fig. 1. The left side shows a selective angiography of the right brachiocephalic trunk (OAD projection); severe stenosis can be seen in the right subclavian artery. In the center, the right mammary artery graft (RMAG) can be seen to the right coronary (RC) in an angiography of the right brachiocephalic trunk (OI projection). On the right, the occlusion of the proximal right coronary artery can be seen.

bypass to the distal DA with a left IMA and to the median RC with a right IMA. After 2 years of clinical stability, he was seen for the reappearance of angina symptoms after less and less exertion that was also associated with movement of the right arm when shaving or washing his face. Angiographic study results revealed the presence of severe stenosis in the right subclavian artery with a permeable right mammary artery graft (Figure 1). Because of the

occlusion of the native right coronary artery, retrograde filling of the graft was not visible; nevertheless, given the possibility that stenosis of the right subclavian artery could limit flow through the graft, balloon dilatation was performed followed by the placement of a 7 × 18 mm stent in the right subclavian artery; the lumen diameter was restored and flow in the subclavian and right mammary was normalized (Figure 2). The patient was asymptomatic at 6-month follow-up.

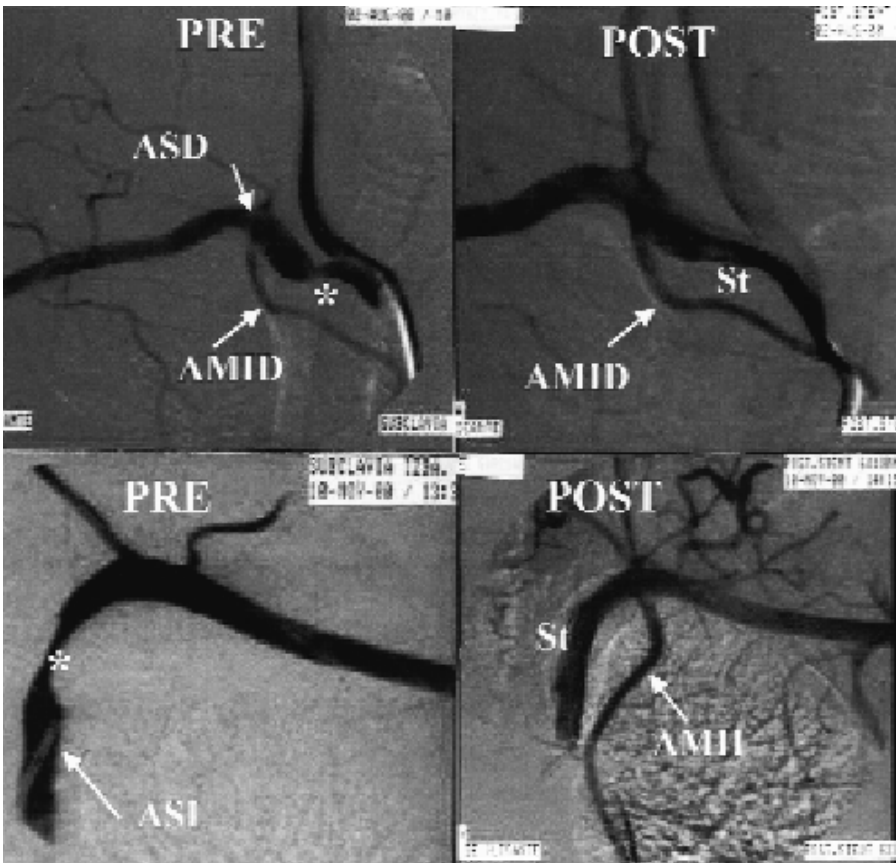
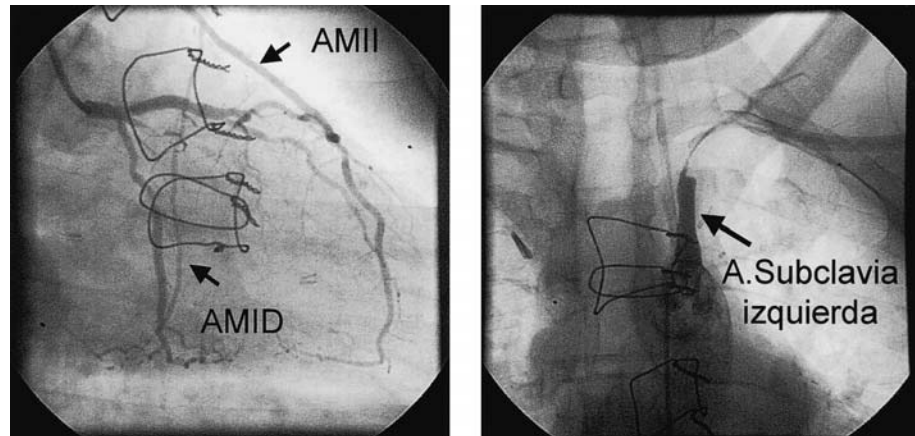


Fig. 2. The upper quadrants contain images from the first case; on the left stenosis (*) can be seen in the right subclavian artery (RSA), and on the right side, the final result after dilation and stent placement (St). The lower quadrants are images of the second case before (left) and after (right) dilation; it can be seen how dilatation normalized the left internal mammary artery (LIMA). LSA indicates left subclavian artery; RIMA, right internal mammary artery.

Fig. 3. The left side shows a selective angiography study of the left coronary artery (OAD projection) where the retrograde fill of the left internal mammary artery (LIMA) graft can be seen. The right internal mammary artery (RIMA) was used as an arterial graft from the RIMA to the obtuse marginal artery. The right side shows a selective angiography study of the left subclavian artery (AP projection) where subtotal stenosis of same can be seen as well as the absence of anterograde fill of the left mammary graft.



Case 2

The patient was a 40-year-old man, current smoker with diabetes mellitus (DM) type 1, dyslipidemia, ischemic cardiopathy with aortocoronary bypass with left LMA to the RC, and free right IMA Y-graft from the left IMA to the marginal obtuse artery. Three years after surgery, the patient was seen for progressive angina. Electrocardiogram showed a sinus rhythm, a complete block of the right branch, and an anterior hemi block. Echocardiogram revealed a slight inferoposterior hypokinesia and preserved systolic function. Ergometry was positive for ischemic electrocardiography and tension fall of 50 mm Hg during stage III of the Bruce protocol. Cardiac catheterization was performed and retrograde filling of mammary graft from the left coronary artery was apparent, as was incomplete stenosis of the left subclavian artery in front of the outlet of the mammary artery (Figure 3). Faced with coronary steal, dilatation was performed followed by the implantation of a 6–20 mm stent in the left subclavian artery with angiographic success (Figure 2) and normalization of the left IMA flow. At 4 month followup the patient remained asymptomatic.

DISCUSSION

Coronary steal syndromes infrequently cause myocardial ischemia as a result of aortocoronary bypass surgery with MA grafts.⁵ The preferential use of left IMA grafts and the growing impetus to use bilateral IMA grafts in coronary revascularization surgery^{2,3} predicts that the incidence of these phenomena may increase.⁴ These syndromes may be due to a number of causes such as mammary artery malformations or the presence of fistulas or large collateral branches, or both; nevertheless, the most frequent and better known cause of coronary steal in patients with mammary grafts is the existence of stenosis in the proximal subclavian artery in front of

the graft origin.^{4,5} Since Tyras and Barner⁵ first described this phenomenon, there have been reports of isolated cases of subclavian coronary steal.^{4,6,8,9}

The phenomenon of subclavian coronary steal often appears in the setting of repair for angina symptomatology through revascularization surgery. Occasionally, steal syndrome caused by stenosis of the subclavian artery can affect other areas and trigger symptoms of vertebrobasilar insufficiency or claudication of the affected superior limb. Our patients were seen for the reappearance of angina symptoms; neither patient reported having other symptoms, even when questioned after the diagnosis had been confirmed. Curiously, in 1 patient the angina was triggered with exercise of the affected upper limb. This would indicate that the increase in musculature of the superior limb took flow away from the graft, which was decreased by the proximal subclavian stenosis.

The period of time that elapsed from the intervention to the appearance of symptoms varied. The appearance of symptoms in the first 2 years is indicative of a relevant stenosis as it existed at the time of surgery;⁴ therefore, adequate questioning of the patient and complete physical exam, with evaluation of differences in arterial pressure or in the pulses in the upper limbs and the presence of murmur in the supraclavicular region, are essential when subclavian stenosis is suspected. The presence of insignificant stenosis can go unnoticed during preoperative evaluation; if this occurs, the progression of the stenosis in the postoperative period can affect the late appearance of coronary steal symptoms. In the cases presented, the appearance of symptoms more than 2 years after surgery would most likely result in slow and gradual progression of insignificant subclavian stenosis at the time of surgery.

Traditionally, the treatment of this illness consisted of surgical correction by performing a carotid subclavian or axilo-axilar bypass.^{4,6} Recently, direct relocation of the mammary artery has been described

in a patient who required implantation of 3 new coronary grafts.⁷ Alternatively, for surgical management, various researchers have used transluminal percutaneous angioplasty successfully to treat coronary steal caused by stenosis of the subclavian artery in patients with mammary artery grafts.⁸⁻¹¹ The patients we present were successfully treated by percutaneous dilatation of the subclavian stenosis, and in both stent implantation was required in the setting of dissections after the dilatation.

The principal complications described include local problems such as dissections in the dilatation point, which can be treated effectively by the implantation of stents, and embolization by the vertebral artery which may cause neurological manifestations that are usually transient.^{10,11}

In conclusion, transluminal percutaneous angioplasty can provide efficacious and reliable outcomes in the treatment of coronary steal caused by subclavian stenosis in patients who have mammary artery grafts; in the absence of other conditions such as fistulas, aneurysms, etc. that require reconstruction of the subclavian artery, it is an efficient alternative to surgical treatment.

REFERENCES

1. Eagle KA, Guyton RA, Davidoff R, Ewy GA, Fonger J, Gardner TJ, et al. ACC/AHA guidelines for coronary artery bypass graft surgery: executive summary and recommendations: a report of the American College of Cardiology/American Heart Association Task Force on Practice Guidelines (Committee to revise the 1991 guidelines for coronary artery bypass graft surgery). *Circulation* 1999;100:1464-80.
2. Buxton B, Komeda M, Fuller J, Gordon I. Bilateral internal thoracic artery grafting may improve outcome of coronary artery surgery. *Circulation* 1998;98(Supl II):1-6.
3. Silva J, Malillos S, Villaseñor M, Marín M, Villacosta I, Martín de Dios R et al. Resultados a medio plazo de la cirugía coronaria con el uso exclusivo de injertos arteriales. *Rev Esp Cardiol* 2000; 53:1201-8.
4. Tönz M, Von Segesser L, Carrel T, Pasic M, Turina M. Steal syndrome after internal mammary artery bypass grafting – An entity with increasing significance. *Thorac Cardiovasc Surg* 1993;41:112-117.
5. Tyras DH, Barner HB. Coronary-subclavian steal. *Arch Surg* 1977;112:1125-7.
6. Saydjari R, Upp J, Wolma F. Coronary-subclavian steal syndrome following coronary artery bypass grafting. *Cardiology* 1991;78: 53-7.
7. Chung D, Large S. Relocation of the internal mammary artery graft in a case of coronary-subclavian steal. *Thorac Cardiovasc Surg* 2000;48:39-40.
8. Crowe K, Iannone L. Percutaneous transluminal angioplasty for subclavian artery stenosis in patients with subclavian steal syndrome and coronary subclavian steal syndrome. *Am Heart J* 1993;126:229-33.
9. Stagg SJ, Abben R, Chaisson G, Kowalski JM, Ladd WR, Meldahl RV, et al. Management of the coronary-subclavian steal syndrome with balloon angioplasty. A case report and review of the literature. *Angiology* 1994;45:725-31.
10. Perrault L, Carrier M, Hudon G, Lemarbre L, Hebert Y, Pelletier L. Transluminal angioplasty of the subclavian artery in patients with internal mammary grafts. *Ann Thorac Surg* 1993;56:927-30.
11. Marques K, Ernst S, Mast G, Bal T, Suttorp MJ, Plokker T. Percutaneous transluminal angioplasty of the left subclavian artery to prevent or treat the coronary-subclavian steal syndrome. *Am J Cardiol* 1996;78:687-90.