

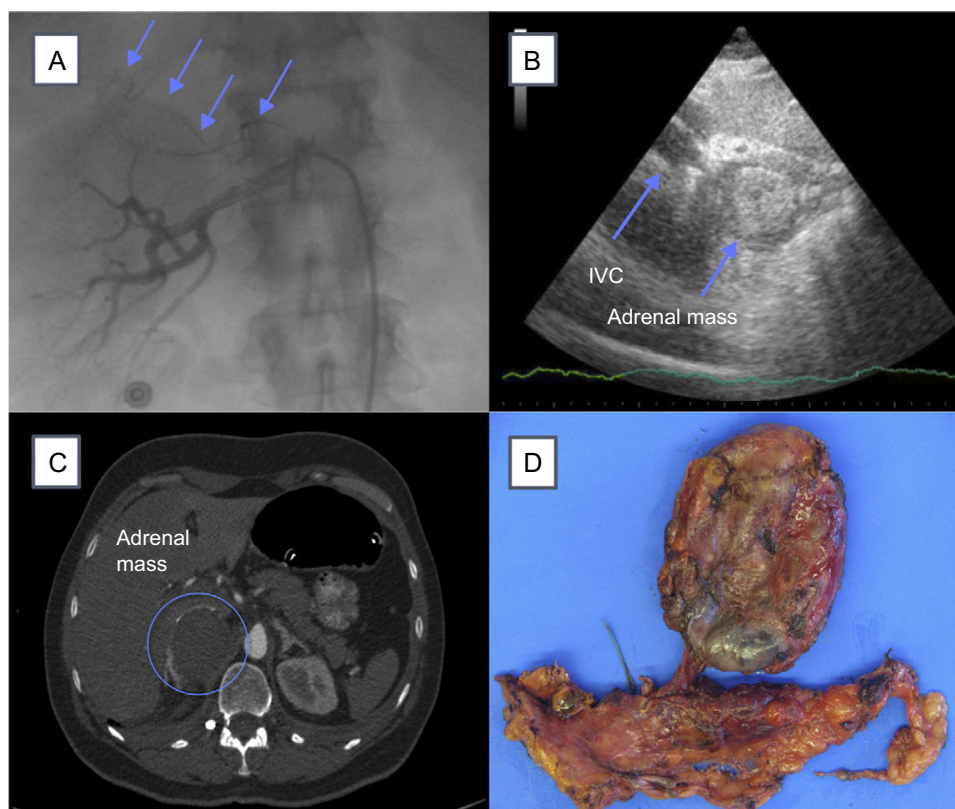Figure 2. A: right renal arteriography. Arrows show abnormal adrenal vascularization; B: cardiogram in subcostal plane showing IVC and adrenal mass; C: abdominal CT. The circle shows the location of the adrenal mass; D, macroscopic specimen of the tumor. CT, computed tomography; IVC, inferior vena cava.

SUPPLEMENTARY MATERIAL



Supplementary material associated with this article can be found in the online version available at [doi:10.1016/j.rec.2016.05.021](https://doi.org/10.1016/j.rec.2016.05.021).

José Miguel Hernández Ramírez,*
Aridane Cárdenes León, and Rakesh Gobind Sakhrani

Servicio de Cardiología, Hospital Universitario de Gran Canaria Doctor Negrín, Las Palmas de Gran Canaria, Las Palmas, Spain

* Corresponding author:
E-mail address: josemi14hr@gmail.com (J.M. Hernández Ramírez).

Available online 12 August 2016

REFERENCES

1. Agarwal V, Kant G, Hans N, Messerli FH. Takotsubo-like cardiomyopathy in pheochromocytoma. *Int J Cardiol.* 2011;153:241–8.
2. Sanchez-Recalde A, Costero O, Oliver JM, Iborra C, Ruiz E, Sobrino JA. Images in cardiovascular medicine. Pheochromocytoma-related cardiomyopathy: inverted Takotsubo contractile pattern. *Circulation.* 2006;113:e738–9.
3. Rosenbaum JS, Billingham ME, Ginsburg R, Tsujimoto G, Lurie KG, Hoffman BB. Cardiomyopathy in a rat model of pheochromocytoma. Morphological and functional alterations. *Am J Cardiovasc Pathol.* 1988;1:389–99.
4. Yunge L, Bruneval P, Cokay MS, Berry B, Peters H, Poulsen R. Perturbation of the sarcolemmal membrane in isoproterenol-induced myocardial injury of the rat. Permeability and freeze-fracture studies in vivo and in vitro. *Am J Pathol.* 1989;134:171–85.
5. Flam B, Broomé M, Frenckner B, Bränström R, Bell M. Pheochromocytoma-induced inverted takotsubo-like cardiomyopathy leading to cardiogenic shock successfully treated with extracorporeal membrane oxygenation. *Intensive Care Med.* 2015;30:365–72.
6. Sojod G, Diana M, Wall J. Successful extracorporeal membrane oxygenation treatment for pheochromocytoma-induced acute cardiac failure. *Am J Emerg Med.* 2012;30:1017.e1–3.

<http://dx.doi.org/10.1016/j.rec.2016.05.021>

Percutaneous Stent Placement to Treat Coarctation of Aorta Due to Atresia in Adult Patients



Tratamiento percutáneo con stent de la coartación atrésica de aorta en el adulto

To the Editor,

Coarctation of aorta (CoA) accounts for between 7% and 10% of cases of congenital heart disease. In this letter, we focus on a

special and very uncommon type (1%–5% of all coarctations), complete aortic occlusion. This condition is characterized by the total absence of distal flow, but with luminal continuity between the ascending and descending aorta, and thus differs from interrupted aortic arch, in which this continuity does not exist. It normally occurs in cases of untreated long-standing CoA, which progress to complete occlusion (distal to the origin of left subclavian artery).^{1–3}

The diagnosis of this condition is usually established in the context of the study of hypertension, stroke, or heart failure. From the anatomical point of view, it is usually accompanied by

Table

Clinical Characteristics, Technical Features, Type of Stent, and Follow-up

Patient	Date	Age, y	Sex	Associated conditions	Length of the occlusion	Pre-/Posttreatment gradient, mmHg	Pre-/Posttreatment diameter, mm	Stent implantation technique	Stent	Outcome	Follow-up
1	6/1997	56	Woman	HT Dilated cardiomyopathy NYHA III/IV VT	8 mm	60/5	0/15	With coronary angioplasty guidewire	Palmaz 308	Effective	Sudden arrhythmic death 2 y later
2	6/1999	31	Woman	HT Bicuspid AV	10 mm	50/5	0/18	With coronary angioplasty guidewire	Palmaz 4014	Effective	Asymptomatic
3	7/2000	38	Woman	HT Bicuspid AV	7 mm	55/2	0/18	With coronary angioplasty guidewire	Palmaz 4014	Effective	Asymptomatic
4	11/2005	57	Man	HT AR (III/IV) Bicuspid AV	12 mm	70/0	0/20	With coronary angioplasty guidewire	NuMED 45.8z covered stent	Death 48 h later	-
5	10/2011	30	Man	HT	11 mm	50/3	0/18	With coronary angioplasty guidewire	NuMED 45.8z covered stent	Effective	Asymptomatic
6	10/2014	60	Man	HT Stroke Stent in DA	25 mm	50/2	0/19	With radiofrequency catheter	NuMED 45.8z covered stent	Effective	Asymptomatic

AD, anterior descending artery; AR, aortic regurgitation; AV, aortic valve; HT, hypertension; NYHA, New York Heart Association; VT, ventricular tachycardia.

extensive collateral circulation, and the aortic wall shows cystic degeneration of the medial layer, as well as marked loss of structure, which can trigger complications such as aneurysms and dissections, or even aortic rupture. Surgical treatment is associated with a high rate of morbidity, with serious complications such as paraplegia. For this reason, percutaneous treatment of this disorder has become highly relevant in recent years.^{3,4}

We present 6 adult patients (3 women and 3 men, with a mean age of 45.3 ± 13 years [range, 30–60 years]). From the clinical point of view, all of them had hypertension, 3 also had congenital aortic valve disease (bicuspid aortic valve), and 1 had dilated cardiomyopathy with severe systolic dysfunction, and was in New York Heart Association functional class III (Table).

All of them underwent a percutaneous intervention to gain access to the coarcted segment and implant a stent—standard Palmaz (Cordis) in the first 3 patients and, from 2005 onward, expanded polytetrafluoroethylene (ePTFE)-covered stents. The procedure was performed under general anesthesia, using a dual arterial access (radial or humeral plus femoral). In the first 5 patients, the occluded segment was crossed using a Hi-Torque Cross-It 200 (Abbott) or Asahi Confianza (World Medical) guidewire via the radial/humeral access and, once this had been accomplished, the distal portion of the guidewire was snared with a loop catheter (Amplatz GooseNeck), and the guidewire was exteriorized by way of a radial-femoral “monorail”. The sixth patient required the use of a radiofrequency catheter (Nikannen) via femoral access to penetrate the occluded segment, given its length (approximately 20 mm), which could not be crossed using an angioplasty guidewire.

Once the radial-femoral monorail had been established, dilatation was performed progressively with 1-mm to 4-mm-balloons inserted via the upper access to achieve distal flow; at that moment, an Amplatz extra-stiff guidewire was introduced via the femoral access, to continue the dilatation with larger-caliber balloons (BALT 8–10 mm). Finally, the stent, which was mounted on a balloon (NuMED Z-Med or BIB balloon) with a diameter similar to that of the aorta, was implanted at the level of the subclavian artery. Then, the distal portion of the stent was

postdilated using a larger-caliber balloon to achieve correct apposition. The results were confirmed both angiographically and hemodynamically (Figure).

The femoral access was closed using the Prostar XL closure device (Abbott) in all the patients, and there were no vascular complications in any of the patients. The patients were discharged from the hospital on the third day and received antiplatelet therapy with aspirin 100 mg/d for 3 to 6 months.

Elimination of the occlusion and stent implantation were achieved in 100% of the patients. We observed a reduction in the gradient from 55 ± 8 mmHg to 3 ± 2 mmHg ($P < .001$). There was only 1 serious complication in a patient (patient 4) who had extensive collateral circulation and a giant aneurysm in an intercostal artery. He died 48 hours after the procedure due to hypovolemic shock secondary to massive hematemesis. The autopsy demonstrated that the stent had lost its covering (for no clear reason), thus leaving a shunt between the intercostal aneurysm and descending aorta, which, with the increase in pressure beyond the point of the coarctation, provoked retrograde flow in the aneurysm that caused a rupture in the esophageal wall and produced an aorto-esophageal fistula.⁴

The mean follow-up was 8.4 (2–17) years (involving office visits and diagnostic imaging techniques—ultrasound and computed tomography or magnetic resonance). There were no aneurysms, dissections, or evidence of recoarctation of the aorta. The mortality rate has increased to 33% (the aforementioned patients 4 and 1, who had dilated cardiomyopathy with severe systolic dysfunction and died 2 years later of sudden arrhythmic death).

Our series of 6 patients undergoing stent implantation for totally occluded CoA is comparable to other published series with good immediate and long-term results, as this condition is associated with a high mortality rate. The use of ePTFE-covered stents can be recommended in this type of complex intervention in calcified aortas with a loss of structure due to medial cystic necrosis, which can progress to the formation of aneurysms, dissections, or even rupture. The stent should be positioned correctly in the wall with its ePTFE covering in order to reduce the incidence of complications. To simplify the procedure, after

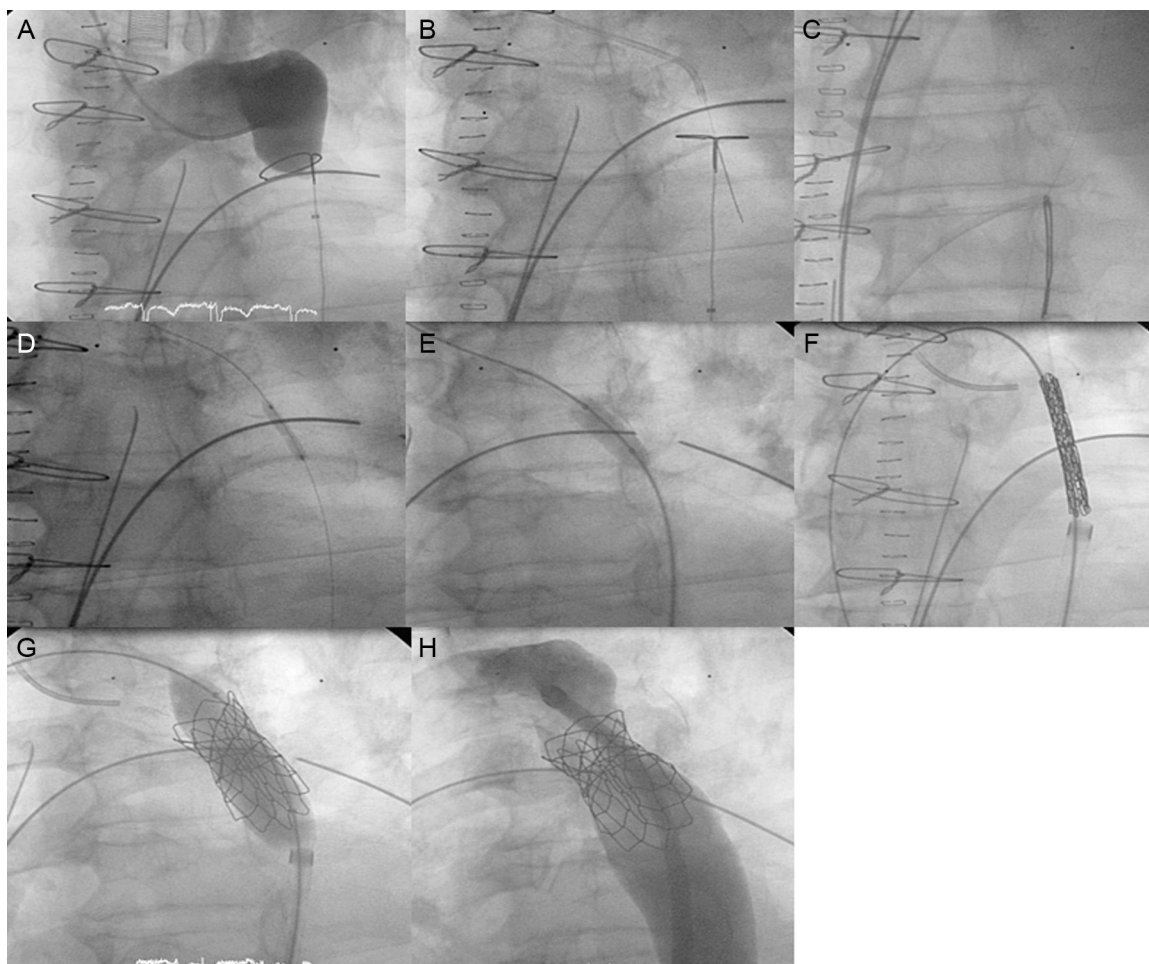


Figure. A: angiography from the upper extreme showing complete occlusion with no distal flow; B: crossing of the occlusion with angioplasty guidewire (Cross-it 300) via radial access; C: guidewire capture using a GooseNeck loop snare and establishment of the radial-femoral monorail; D: dilatation by coronary balloon angioplasty via the radial access; E: dilatation with a larger-caliber balloon (BALT) via the femoral access; F: introduction of the Mullins sheath with the stent; G: stent implantation; and H: postdilatation for correct apposition of the stent to the wall.

ensuring the expansion of the stent with its ePTFE covering, we now employ the Nudel premounted system (Evomed), very similar to that of the Melody pulmonary valve prosthesis, which might have prevented the fatal complication in patient 4.

In our experience, totally occluded CoA represents 4% of the total number of percutaneous interventions in CoA and 12% of cases involving stent implantation. The collateral circulation is usually highly developed, which confers special surgical difficulty and risk on the procedure. This has led to the development of the percutaneous approach, with techniques for crossing the occluded segment using coronary angioplasty or radiofrequency guidewires and implantation of a stent, which should preferably be covered with ePTFE, as it reduces long-term complications.^{5,6}

Luis Fernández González,* Koldobika García San Román, Roberto Blanco Mata, Josune Arriola Meabe, Juan Carlos Astorga Burgo, and Juan Alcibar Villa

Departamento de Cardiología Intervencionista, Servicio de Cardiología, Hospital Universitario de Cruces, Baracaldo, Vizcaya, Spain

* Corresponding author:

E-mail address: Luisfg82@hotmail.com (L. Fernández González).

Available online 11 August 2016

REFERENCES

1. Suárez de Lezo J, Pan M, Romero M, Medina A, Segura J, Pavlovic A, et al. Balloon-expandable stent repair of severe coarctation of aorta. *Am Heart J*. 1995; 129:1002–8.
2. Alcibar J, Peña N, Oñate A, Cabrera A, Galdeano JM, Pastor E, et al. Implantación primaria de stent en la coartación de aorta; seguimiento a mediano plazo. *Rev Esp Cardiol*. 2000;52:797–804.
3. Butera G, Heles M, Carminati M. Percutaneous treatment of aortic isthmus atresia: use of radiofrequency perforation and covered stents. *Catheter Cardiovasc Interv*. 2011;78:933–9.
4. Alcibar J, Blanco R, Fernandez L, Arriola J, García K, Peña N, et al. Elective implantation of covered stents for coarctation and recoarctation in adolescents and adults. *Rev Esp Cardiol*. 2013;66:443–9.
5. Momenah T, Khan M, Qureshi S, Hijazi Z. Acquired aortic atresia: catheter therapy using covered stents. *Catheter Cardiovasc Interv*. 2015;86:1063–7.
6. Suárez de Lezo J, Romero M, Pan M, Suárez de Lezo J, Segura J, Ojeda S, et al. Stent repair for complex coarctation of aorta. *JACC Cardiovasc Interv*. 2015; 8:1368–79.

<http://dx.doi.org/10.1016/j.rec.2016.05.019>