

## Percutaneous Intervention for Severe Aortic Stenosis and Left Main Artery Disease in a Morbidly Obese Patient

Luisa Salido, José L. Mestre, Alejandro del Río, Celia Vaticón, Francisco Barcia, and Jaime Pey

Sección de Hemodinámica, Hospital Ramón y Cajal, Madrid, Spain.

Obesity increases significantly the rate of postsurgical complications and mortality in patients undergoing major surgery. We present the case of a morbidly obese 65-year-old female with severe aortic stenosis and left main coronary artery disease who underwent successful aortic valvuloplasty and angioplasty, with placement of a stent in the left main coronary artery. After undergoing bariatric surgery and losing 30% of her body weight, the patient was accepted for cardiac surgery to replace the aortic valve and to bypass the left anterior descending coronary artery using the mammary artery. There were no surgical complications.

**Key words:** *Obesity. Aortic valvuloplasty. Coronary angioplasty.*

### **Tratamiento percutáneo de estenosis aórtica y lesión de tronco coronario izquierdo severa en paciente con obesidad mórbida**

La obesidad es un factor de riesgo para el desarrollo de complicaciones posquirúrgicas e incrementa de forma significativa la tasa de mortalidad intrahospitalaria. Presentamos el caso de una mujer de 65 años con obesidad mórbida, estenosis aórtica severa y enfermedad de tronco que se trató con éxito mediante valvuloplastia aórtica y angioplastia e implantación de *stent* en tronco coronario izquierdo. Tras una intervención quirúrgica bariátrica y perder el 30% de su peso, la paciente fue aceptada en cirugía cardíaca y se le realizó recambio valvular aórtico y *bypass* de mamaria a la descendente anterior (DA) sin complicaciones.

**Palabras clave:** *Obesidad. Valvuloplastia aórtica. Angioplastia coronaria.*

## INTRODUCTION

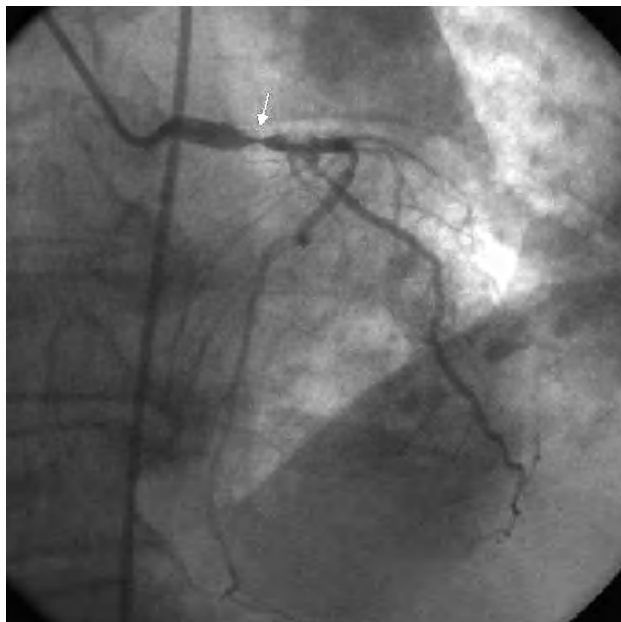
Obesity is an important risk factor for postoperative complications following heart surgery and significantly increases the incidence of in-hospital infections and mortality. Percutaneous treatment of concomitant valve disease and coronary disease may be an effective, less aggressive alternative with potentially fewer complications among high-risk surgical patients.

## CASE STUDY

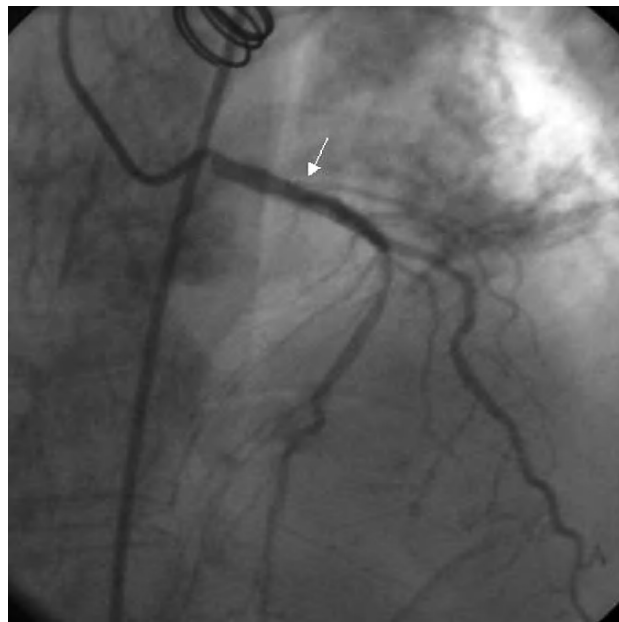
A 65-year-old woman with a body mass index of 44 and a history of hypertension, type 2 diabetes, right lobectomy due to childhood tuberculosis with moderate pulmonary restriction, and Graves-Basedow disease was admitted for surgery for morbid obesity. During the hospitalization, she was assessed by the cardiology department for an episode of chest pain that lasted 30 minutes. Cardiopulmonary auscultation revealed an aortic ejection murmur and hypoventilation in both lung fields; the electrocardiogram showed sinus rhythm with no evidence of acute ischemia. The blood analyses indicated elevation of myocardial lesion markers (troponin I, 8 ng/dL and creatine kinase, normal); hence, coronary angiography was performed. The diagnostic catheterization disclosed a severe calcified lesion of the left main stem that encompassed the origin of the circumflex artery and a 50% lesion in the middle segment of the left anterior descending artery (Figure

Correspondence: Dra. L. Salido Tahoces.  
Hospital Ramón y Cajal.  
Ctra. de Colmenar, km 9,100. 28039 Madrid. España.  
E-mail: luisasalido@hotmail.com

Received March 11, 2005.  
Accepted for publication May 10, 2005.



**Figure 1.** Left anterior oblique view showing a calcified lesion in the left coronary trunk that encompasses the origin of the circumflex artery.



**Figure 2.** Angiographic image following stent placement in the left coronary trunk and in the ostium of the circumflex artery.

1). Ventriculography showed normal overall ventricular function with no regional contractility alterations. Measurement of the left ventricular and aortic pressures gave a peak-to-peak gradient of 100 mm Hg and average of 60 mm Hg. Based on these findings, the patient was considered ineligible for bariatric surgery and at high risk for heart surgery due to obesity; therefore, conservative medical treatment was initiated. Two months later the patient was readmitted to the coronary unit for acute pulmonary edema secondary to atrial fibrillation with rapid ventricular response and discharged following stabilization and medical treatment. Two months later she was again admitted with a diagnosis of Killip Class III acute myocardial infarction; palliative percutaneous treatment was decided because of the patient's poor progress. Aortic valvuloplasty was performed using a Cribier Laetac® balloon and the peak-to-peak gradient dropped from 100 to 40 mm Hg. A paclitaxel-coated stent (Taxus 3.5×12 mm) was implanted in the left coronary trunk during the same procedure, along with another stent in the ostium of the circumflex artery (Taxus 2.75×16 mm) (Figure 2). Four months later the patient was cardiologically stable and asymptomatic, and was able to undergo bariatric surgery consisting of gastrectomy, cholecystectomy, and biliopancreatic diversion, with an uneventful postoperative period. Eight months later she was admitted for chest pain. Diagnostic catheterization was repeated showing absence of in-stent restenosis; however, there was a 60% lesion in the middle segment of the left anterior descending artery was seen. The

mean aortic transvalvular gradient was 50 mm Hg. By that time, the patient had lost 30% of her body weight and the body mass index was 31; therefore, she was accepted by the cardiac surgery department. On-pump aortic valve replacement with a 21 Omnicarbon prosthesis and an internal mammary artery bypass to the left anterior descending artery were performed. The postoperative was uneventful, and the patient remained asymptomatic one year later.

## DISCUSSION

Obesity raises the risk of any type of surgery, significantly increasing the risk of infections and in-hospital mortality. Morbid obesity is defined as a body mass index  $\geq 40$ . In these patients, diet and behavioral therapies fail in 90% of the cases. Surgical treatment is more successful and in most cases achieves a reduction of 50% in preoperative weight, thus lowering the risks associated with severe obesity.<sup>1</sup>

Combined aortic valve replacement and coronary revascularization surgery was indicated in our patient. However, the surgical risk calculated by the EuroSCORE<sup>2</sup> was extremely high and conservative treatment was initially decided. Given the patient's poor clinical progress, percutaneous treatment of both the aortic stenosis and the coronary lesions was chosen as an alternative with the aim of performing bariatric surgery followed by heart surgery sometime later.

Aortic valvuloplasty can be used as palliative treatment for patients with symptomatic aortic stenosis

when valve replacement surgery is contraindicated. This therapeutic alternative has been used in elderly patients and in patients in cardiogenic shock as a bridge to subsequent heart surgery. Ten percent of cases develop severe complications, and restenosis appears in most patients within 6-12 months after valvuloplasty.<sup>3,4</sup>

Additionally, a significant lesion in the left main stem is an indication for surgical revascularization. The high associated risk and the high incidence of restenosis with conventional stents have been some of the arguments used against percutaneous surgery for lesions in this location. The incidence of restenosis is considerably lower with the use of drug-coated stents, making percutaneous management of these lesions a safe alternative for some patients.<sup>5,6</sup>

The literature review revealed only a few cases of aortic valvuloplasty combined with coronary angioplasty in older patients and in patients with cardiogenic shock.<sup>7</sup> This is the first time this treatment has been described as an alternative for a patient with morbid obesity and at high surgical risk.

## REFERENCES

1. Steinbrook R. Surgery for severe obesity. *N Engl J Med.* 2004;11:1075-9.
2. Karthik S, Srinivasan AK, Grayson AD, Jackson M, Sharpe DA, Keenan DJ, et al. Limitations of additive EuroSCORE for measuring risk stratified mortality in combined coronary and valve surgery. *Eur J Cardiothorac Surg.* 2004;26:318-22.
3. Dauterman KW, Michaels AD, Ports TA. Is there any indication for aortic valvuloplasty in the elderly? *Am J Geriatr Cardiol.* 2003; 12:190-6.
4. Buchwald AB, Meyer T, Scholz K, Schorn B, Unterberg C. Efficacy of balloon valvuloplasty in patients with critical aortic stenosis and cardiogenic shock: the role of shock duration. *J Clin Cardiol.* 2001; 24:214-8.
5. López-Palop R, Pinar E, Saura D, Pérez-Lorente F, Lozano I, Teruel F, et al. Resultados a corto y medio plazo del intervencionismo coronario percutáneo sobre el tronco coronario común izquierdo no protegido en pacientes malos candidatos para revascularización quirúrgica. *Rev Esp Cardiol.* 2004;57:1035-44.
6. Soriano Triguero J. Intervencionismo percutáneo en la enfermedad del tronco común izquierdo: ¿es hora de cambiar las guías de actuación? *Rev Esp Cardiol.* 2004;57:1009-13.
7. Whisenant B, Sweeney J, Ports TA. Combined PTCA and aortic valvuloplasty for acute myocardial infarction complicated by severe aortic stenosis and cardiogenic shock. *Cathet Cardiovasc Diagn.* 1997;42:283-5.