

Scientific letters

Percutaneous Coronary Intervention: A Rare Cause of Acute Traumatic Aortic Regurgitation***Insuficiencia aórtica aguda traumática tras intervención coronaria percutánea: una causa poco frecuente*****To the Editor,**

Percutaneous coronary procedures are safe techniques that have greatly improved the prognosis of patients with ischemic heart disease. Since their introduction in cardiology, the number of percutaneous procedures has increased considerably, reaching 140 461 diagnostic procedures in 2014.¹ However, despite their advantages, percutaneous procedures are not risk-free.

We present the case of a 63-year-old man, a former smoker with high blood pressure and dyslipidemia, who was admitted to hospital with inferior ST-segment acute myocardial infarction (Figure 1A). Emergency coronary catheterization via the right radial artery revealed a lesion-free left coronary tree and a severe injury in the proximal right coronary artery (RCA), with thrombotic occlusion of the midsegment (Figure 1B). Therapeutic catheterization of the RCA proved extremely difficult due to lack of support, requiring the successive use of several catheters (JR4, AL2, and AR1) and was finally achieved with a 3 D right coronary catheter (Medtronic; Minneapolis, Minnesota, United States). A hydrophilic guidewire

was then inserted and the vessel was predilated with a conventional 1.5 × 12 mm balloon at 20 atm. Revascularization was achieved with 2 uncovered stents measuring 3 × 23 mm (midsegment RCA) and 3.5 × 14 mm (proximal RCA), yielding good angiographic and clinical results. Twenty-four hours after the procedure, the patient developed ventricular fibrillation. Sinus rhythm was restored after a 360 J electric shock, advanced cardiopulmonary reanimation maneuvers, vasoactive therapy, and orotracheal intubation. Electrocardiography detected current from an inferior subepicardial injury, prompting a repeat coronary catheterization that revealed stent thrombosis. Subsequent clinical progress was slow, and the patient developed a pronounced aortic diastolic murmur that was not present on admission. Emergency transthoracic echocardiography detected an acute aortic regurgitation (AoR) with images showing nodules adhered to the ventricular surface of the aortic valve; AoR was confirmed by transesophageal echocardiography (Figure 1C–1D). Infective aortic valve endocarditis was suspected, and given the poor clinical progress, the patient was referred for surgery after 24 hours. Intraoperative examination excluded endocarditis as the cause of AoR. A tear was observed at the free edge of the noncoronary aortic leaflet, associated with severe traumatic AoR and probably related to rotation of the 3 D right catheter during investigation of the RCA (Figure 2). The aortic valve was beyond repair, and the patient was therefore referred for aortic valve replacement surgery, subsequently making good clinical progress.

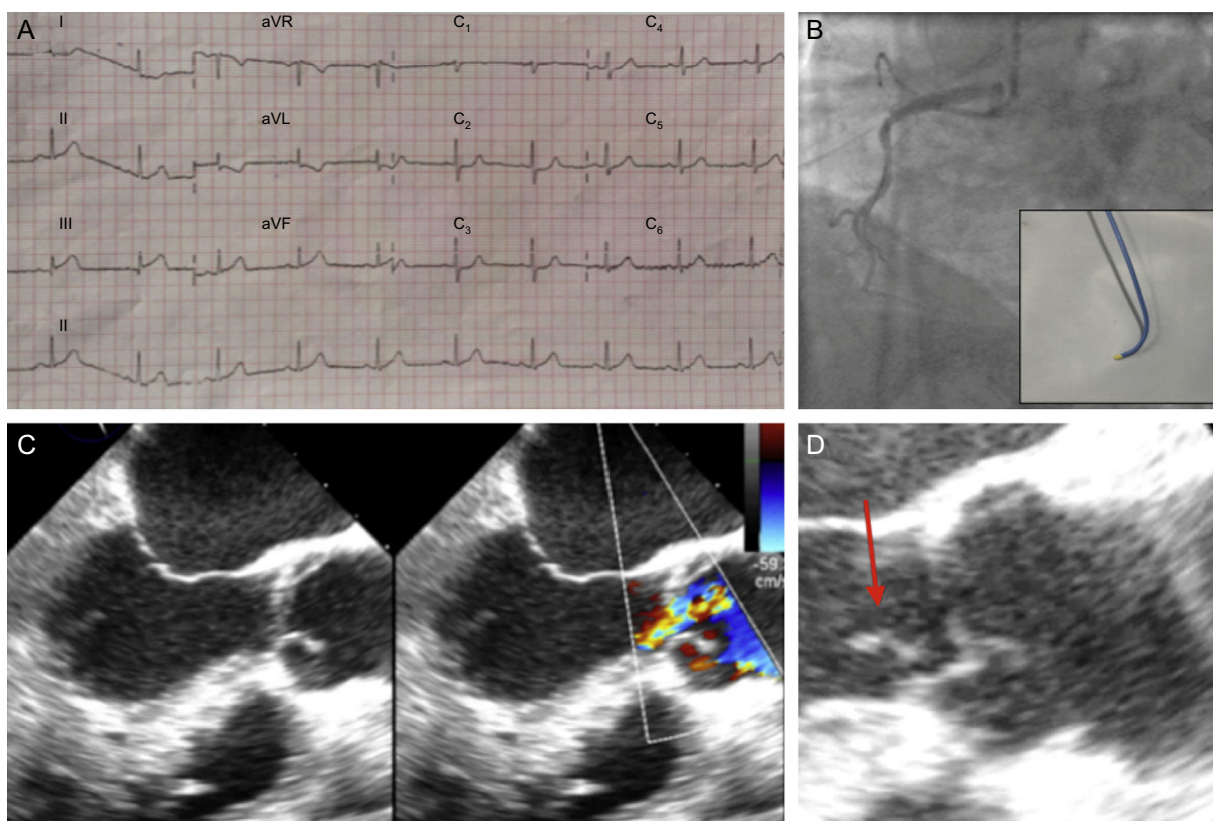


Figure 1. A: Electrocardiogram showing current due to inferior subepicardial injury. B: Coronary angiogram showing thrombotic occlusion of the midsegment right coronary artery; the inset shows the 3D catheter. C: Transthoracic echocardiogram at the level of the left ventricular outflow tract at 120°, showing severe aortic regurgitation. D: Image of nodules (arrow) adhered to the ventricular plane of the aortic valve.

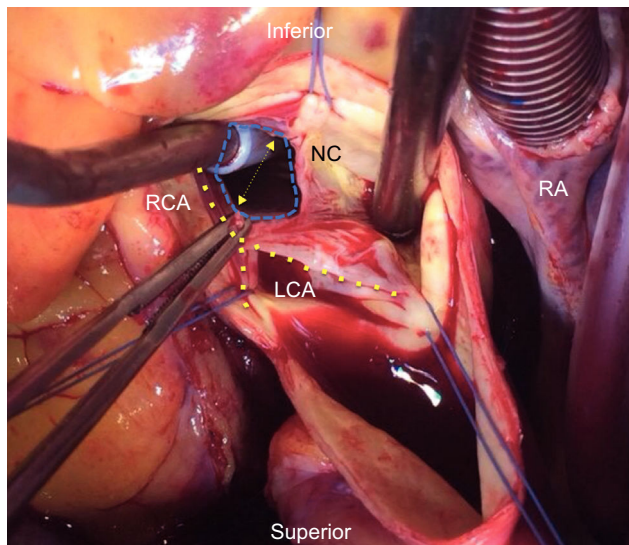


Figure 2. Intraoperative image of the aortic valve, showing perforation of the noncoronary leaflet. The 3 commissures are delimited by the sutures (discontinuous blue line). The aspirator to the left is introduced through the leaflet perforation. The aspirator to the right is placed over the ring of the injured leaflet, which is opened in the form of a V, almost obscuring the left and right coronary leaflets. The tweezers hold one edge of the perforated leaflet, which would normally join the other leaflet-half at the commissure positioned at 12 o'clock in the image. RA, right atrium; RCA, right coronary artery; LCA, left coronary artery; NC, noncoronary.

Minor complications are relatively common during percutaneous coronary procedures; however, there is a relatively low rate of potentially fatal complications such as acute arterial occlusion and cardiogenic shock. According to the 2015 Spanish Cardiac Catheterization and Coronary Intervention Registry (*Registro Español de Hemodinámica y Cardiología Intervencionista*), in 2014 severe complications during intervention affected 1.2% of procedures and the intervention mortality rate was just 0.4%.¹

Acute traumatic AoR due to catheterization injury is an extremely rare mechanical complication. Three mechanisms have been reported for acute traumatic AoR. The most frequent is transitory regurgitation due to excessive movement of rigid catheters into the aortic arch, and the condition is relieved upon catheter withdrawal². Irreversible acute AoR is rare and is generally related to stents implanted in the RCA ostium protruding into the aorta.^{3,4}

Of the very few reported cases of direct catheter perforation of the coronary leaflet, most involve intervention in the RCA with Amplatz catheters.^{5,6} This type of complication can be prevented by careful catheter handling, especially in situations where catheterization is challenging or in patients with coronary anomalies.

Sergio Gamaza Chulián,^a Santiago Jesús Camacho Freire,^b
Javier León Jiménez,^{b,*} Antonio Agarrado Luna,^a
Tomás Daroca Martínez,^c and Manuel Jesús Oneto Otero^a

^aServicio de Cardiología, Hospital Universitario de Jerez de la Frontera, Jerez de la Frontera, Cádiz, Spain

^bServicio de Cardiología, Complejo Hospitalario Universitario de Huelva, Huelva, Spain

^cServicio de Cirugía Cardíaca, Hospital Puerta del Mar, Cádiz, Spain

*Corresponding author:

E-mail address: javierleonjimenez@gmail.com (J. León Jiménez).

Available online 20 October 2016

REFERENCES

- García del Blanco B, Hernández Hernández F, Rumoroso Cuevas JR, Trillo Nouché R. Registro Español de Hemodinámica y Cardiología Intervencionista. XXIV Informe Oficial de la Sección de Hemodinámica y Cardiología Intervencionista de la Sociedad Española de Cardiología (1990-2014). *Rev Esp Cardiol.* 2015;68:1154–1164.
- Javeed N, Shaikh J, Patel M, Rezai F, Wong P. Catheter-induced acute aortic insufficiency with hemodynamic collapse during PTCA: an unreported complication. *Cathet Cardiovasc Diagn.* 1997;42:305–307.
- Kotoulas C, Bigeon JY, Patris K, Hasan R. Aortic valve as a victim of percutaneous coronary angioplasty and stenting. *Ann Thorac Surg.* 2007;84:1765.
- Quintana E, Mestres CA, Congiu S, Josa M, Cartañá R. Delayed aortic regurgitation caused by a right coronary stent protruding into the aorta. *J Heart Valve Dis.* 2009;18:717–719.
- Ong G, Bagur R, Barbeau G, Couture C, Trahan S, Déry JP. Severe aortic regurgitation after transradial percutaneous coronary intervention. *Circ Cardiovasc Interv.* 2011;4:e8–e11.
- Grisoli D, Gariboldi V, Quilici J. An unusual complication after coronary catheterization. *J Invasive Cardiol.* 2012;24:E22–E23.

<http://dx.doi.org/10.1016/j.rec.2016.09.017>
1885-5857/

© 2016 Sociedad Española de Cardiología. Published by Elsevier España, S.L.U. All rights reserved.

Acute Coronary Syndrome Due to Septic Embolism Secondary to Infective Endocarditis in a Prosthetic Mitral Valve



Síndrome coronario agudo por embolia séptica secundaria a endocarditis infecciosa en prótesis mitral

To the Editor,

We report the uncommon case of a male patient with acute coronary syndrome (ACS) secondary to a septic embolism in the setting of infective endocarditis (IE) in a mitral valve prosthesis. To date, the literature indicates a higher frequency of this condition in aortic valve replacements. We conducted a review of the disease and of the treatment currently considered most appropriate.

The patient was a 69-year-old man whose mitral valve was replaced in 2005 with a No. 29 St. Jude mechanical prosthetic

mitral valve due to IE in the setting of Q fever, after he had presented to our emergency department because of an episode of syncope. On arrival, an electrocardiogram showed a complete atrioventricular block with a nodal escape rhythm at 44 bpm. The international normalized ratio (INR) was in therapeutic range. In the next few hours, while in the observation unit, the patient had typical angina, and a new electrocardiogram showed excessively discordant (2 mm) ST elevation in anterior leads (V₂-V₄). The infarction code was activated. On arrival at the cardiac catheterization laboratory, the patient had ventricular fibrillation; he underwent immediate electrical cardioversion, which restored the previous rhythm, complete atrioventricular block, and a transitory pacemaker was implanted.

Emergency coronary angiography revealed acute occlusion of the middle anterior descending artery, without filling of the distal vascular bed (**Figure 1** and **Video 1** of the supplementary material). Suspecting an embolic origin, we performed multiple